This is a digital copy of a book that was preserved for generations on library shelves before it was carefully scanned by Google as part of a project to make the world's books discoverable online.

It has survived long enough for the copyright to expire and the book to enter the public domain. A public domain book is one that was never subject to copyright or whose legal copyright term has expired. Whether a book is in the public domain may vary country to country. Public domain books are our gateways to the past, representing a wealth of history, culture and knowledge that's often difficult to discover.

Marks, notations and other marginalia present in the original volume will appear in this file - a reminder of this book's long journey from the publisher to a library and finally to you.

Usage guidelines

Google is proud to partner with libraries to digitize public domain materials and make them widely accessible. Public domain books belong to the public and we are merely their custodians. Nevertheless, this work is expensive, so in order to keep providing this resource, we have taken steps to prevent abuse by commercial parties, including placing technical restrictions on automated querying.

We also ask that you:

+ *Make non-commercial use of the files* We designed Google Book Search for use by individuals, and we request that you use these files for personal, non-commercial purposes.

+ *Refrain from automated querying* Do not send automated queries of any sort to Google's system: If you are conducting research on machine translation, optical character recognition or other areas where access to a large amount of text is helpful, please contact us. We encourage the use of public domain materials for these purposes and may be able to help.

+ *Maintain attribution* The Google "watermark" you see on each file is essential for informing people about this project and helping them find additional materials through Google Book Search. Please do not remove it.

+ *Keep it legal* Whatever your use, remember that you are responsible for ensuring that what you are doing is legal. Do not assume that just because we believe a book is in the public domain for users in the United States, that the work is also in the public domain for users in other countries. Whether a book is still in copyright varies from country to country, and we can't offer guidance on whether any specific use of any specific book is allowed. Please do not assume that a book's appearance in Google Book Search means it can be used in any manner anywhere in the world. Copyright infringement liability can be quite severe.

About Google Book Search

Google's mission is to organize the world's information and to make it universally accessible and useful. Google Book Search helps readers discover the world's books while helping authors and publishers reach new audiences. You can search through the full text of this book on the web at http://books.google.com/

COUNTWAY LIBRARY
HC 1AGA N

Given by L. Melville French.
Class Book
DISCARDED BY NEW HAMPSHIRE STATE LIBRARY
State Library
CONCORD.

This book treats also of

Subject	*Page*	*Subject*	*Page*

BLANCHARD & LEA,

PHILADELPHIA,

HAVE JUST ISSUED

A PRACTICAL TREATISE ON

DISEASES AND INJURIES OF THE EYE.

BY W. MACKENZIE, M.D.,

SURGEON OCULIST IN ORDINARY IN SCOTLAND TO HER MAJESTY, ETC.

TO WHICH IS PREFIXED AN ANATOMICAL INTRODUCTION EXPLANATORY OF

A HORIZONTAL SECTION OF THE HUMAN EYEBALL.

BY T. WHARTON JONES, F. R. S., ETC.

FROM THE FOURTH REVISED AND ENLARGED ENGLISH EDITION.

WITH NOTES AND ADDITIONS

BY ADDINELL HEWSON, M.D.,

ONE OF THE SURGEONS TO WILLS HOSPITAL, ETC.

WITH PLATES AND NUMEROUS ILLUSTRATIONS.

In one very large and handsome octavo volume, of over one thousand pages, strongly bound, with raised bands.

The treatise of Dr. Mackenzie indisputably holds the first place, and forms, in respect of learning and research, an Encyclopædia unequalled in extent by any other work of the kind, either English or foreign.—*Dixon on Diseases of the Eye.*

The fourth edition of this standard work will no doubt be as fully appreciated as the three former editions. It is unnecessary to say a word in its praise, for the verdict has already been passed upon it by the most competent judges, and "Mackenzie on the Eye" has justly obtained a reputation which it is no figure of speech to call world-wide.—*British and Foreign Medico-Chirurgical Review.*

This new edition of Dr. Mackenzie's celebrated treatise on diseases of the eye, is truly a miracle of industry and learning. We need scarcely say that he has entirely exhausted the subject of his specialty.—*Dublin Quarterly Journal.*

We have no hesitation in saying that, in the whole range of surgical literature, no work excels, few rival, Dr. Mackenzie's treatise, for exact and profound erudition, for an accurate and comprehensive power of clinical observation, and for sound judgment in the application of scientific knowledge to the great end of medical science, the treatment of disease.—*Association Med. Journal*, July 27, 1855.

We are satisfied that no student, teacher, or practitioner need fear to rely upon the book as a library in itself, and one adapted to every want in relation to every subject of which it treats. Dr. Hewson's contributions include many new cases, as well as recent observations, and may be regarded as decidedly enhancing the value of the edition.—*Am. Journal Med. Sciences*, Oct., 1855.

1

BLANCHARD & LEA,

PHILADELPHIA,

HAVE RECENTLY ISSUED

A TREATISE ON THE DISEASES OF THE EYE.

BY W. LAWRENCE, F.R.S.,

SURGEON EXTRAORDINARY TO THE QUEEN, SURGEON TO ST. BARTHOLOMEW'S HOSPITAL, ETC.

A NEW EDITION,

EDITED, WITH NUMEROUS ADDITIONS, AND TWO HUNDRED AND FORTY-THREE ILLUSTRATIONS,

BY ISAAC HAYS, M.D.,

SURGEON TO WILLS HOSPITAL, ETC.

In one very large and handsome octavo volume of 950 pages, strongly bound in leather, with raised bands.

In a future number we shall notice more at length this admirable treatise—the safest guide and most comprehensive work of reference, which is within the reach of all classes of the profession.—*Stethoscope.*

This standard text-book on the department of which it treats, has not been superseded by any or all of the numerous publications on the subject heretofore issued. Nor with the multiplied improvements of Dr. Hays, the American Editor, is it at all likely that this great work will cease to merit the confidence and preference of students or practitioners. Its ample extent—nearly one thousand large octavo pages—has enabled both author and editor to do justice to all the details of this subject, and condense in this single volume the present state of our knowledge of the whole science in this department, whereby its practical value cannot be excelled. We heartily commend it, especially as a book of reference, indispensable in every medical library. The additions of the American editor very greatly enhance the value of the work, exhibiting the learning and experience of Dr. Hays, in the light in which he ought to be held, as a standard authority on all subjects appertaining to this specialty, to which he has rendered so many valuable contributions.—*N. Y. Medical Gazette.*

We know of no work to which we would refer with more confidence; indeed it is decidedly the best in our language. The publishers are entitled to high commendation for the beautiful style in which they have issued the work, and we take great pleasure in recommending it to the profession.—*Southern Med. and Surgical Journal.*

The editor, Dr. Hays, has made many valuable additions to portions of the work which had fallen into the background, from the advances in ophthalmic physiology, pathology, and therapeutics, since the issue of the former edition. It has always been considered a standard work, and may now be regarded as one of our most complete treatises on the diseases of the eye, and fully illustrates the most recent and improved views of authorities at home and abroad.—*N. Y. Journal of Medical and Collateral Science.*

The subject is one which demands much study, and in its prosecution we do not know so complete and trustworthy a manual as this elaborate treatise by Mr. Lawrence.—*Western Journal of Med. and Surg.*

This voluminous treatise—948 closely printed pages—is the most complete and learned encyclopædia of ophthalmic, medical, and surgical science, brought down to the moment of publication, in any language.—*American Lancet.*

PRINCIPLES AND PRACTICE

OF

OPHTHALMIC MEDICINE AND SURGERY.

617.7
J79p2

THE

PRINCIPLES AND PRACTICE

OF

OPHTHALMIC

MEDICINE AND SURGERY.

BY

T. WHARTON JONES, F.R.S.,

PROFESSOR OF OPHTHALMIC MEDICINE AND SURGERY IN UNIVERSITY COLLEGE, LONDON;
OPHTHALMIC SURGEON TO THE HOSPITAL, ETC.

WITH

ONE HUNDRED AND TEN ILLUSTRATIONS.

SECOND AMERICAN EDITION, WITH ADDITIONS, FROM THE SECOND AND REVISED LONDON EDITION.

HARVARD MEDICAL LIBRARY
IN THE
FRANCIS A. COUNTWAY
LIBRARY OF MEDICINE

NEW HAMPSHIRE
OCT 2 1859
STATE LIBRARY
DISCARDED BY
NEW HAMPSHIRE STATE LIBRARY

PHILADELPHIA:
BLANCHARD AND LEA.
1856.

Entered, according to Act of Congress, in the year 1855,

BY BLANCHARD & LEA,

In the Clerk's Office of the District Court for the Eastern District of Pennsylvania.

ADVERTISEMENT

TO THE SECOND AMERICAN EDITION.

This excellent manual, which is already well known to the American profession through the former edition, revised by Dr. Hays, has been materially improved in matter and arrangement by its distinguished author; and we trust that it may prove more than ever useful to the class of readers for whom it was especially designed.

In consenting to superintend the present edition, although necessarily precluded from making any large additions to a work already so complete in most respects, as well as so compact, the Editor has nevertheless ventured to introduce some occasional short notes in relation to details of treatment in which the experience of this city appeared to him to differ from that of London. He regrets that the brevity essential to these additions may, perhaps, have given to them an air of dogmatism almost unavoidable in the act of condensation. They are enclosed in brackets, and have been placed in

the body of the page, in order as much as possible to avoid the accumulation of foot-notes.

The only excuse he has to give for their insertion is, that they are founded on a personal familiarity with the subjects treated of, for many years past, in association, on both sides of the Atlantic, either as pupil or colleague, with observers of long-established authority; and especially as Surgeon to Wills Hospital, well known as one of the oldest and largest eye infirmaries of this country.

EDWARD HARTSHORNE, M.D.

PHILADELPHIA,
453 Walnut Street.

ADVERTISEMENT

TO THE SECOND LONDON EDITION.

"To produce a Work on the Diseases of the Eye, which should serve at once as a text-book for students and as a book of reference for practitioners, has been the great aim of the Author in composing this Manual. Accordingly, besides carefully discussing the principles, he has labored to give such a practical exposition of the subject as will be found available at the bedside of the patient, and in the operating room."

Believing that in the aim here expressed, the Author has not been unsuccessful, he has continued to hold it in view in the preparation of this Second Edition. The additions and alterations made, he hopes, will be

all found to manifest a practical tendency, and to bring the Work up to the present state of knowledge in the important department of Medicine and Surgery of which it treats.

HANOVER SQUARE, LONDON,
35 George Street

CONTENTS.

CHAPTER I.

SECTION I.—OPHTHALMOSCOPY OR EXPLORATION OF THE EYES, IN ORDER TO A DIAGNOSIS.

PAGE

OBJECTIVE EXPLORATION OF THE EYES, . . . 37
Exploration of the eyebrows and orbital margins, . 39
Exploration of the eyelids and their tarsal border, including the state of the cilia and Meibomian apertures, . . 40
Exploration of the conjunctival surface of the eyelids, and of the palpebral sinuses, ... 43
Exploration of the angles of the eye, and of the lacrymal organs, as regards their general state, . . . 44
Examination of the form and appearance of the eyeballs generally, their size and degree of prominence, . . 46
Examination of the direction and movements of the eyeballs, 46
Examination of the front and interior of the eyeball, . 47

SUBJECTIVE EXAMINATION OF THE EYES, ... 63
Pain; its seat and character, ... 63
Impairment or loss of common sensibility, . . . 63
Intolerance of light or photophobia, ... 64
State of vision, ... 64

SECTION II.—APPLICATION OF REMEDIES TO THE EYES OR THEIR NEIGHBORHOOD, AND PERFORMANCE OF MINOR OPERATIONS ON THEM, . . . 66

Cold applications, ... 66
Warm applications, ... 66
Medicated vapors, ... 67
Collyria, &c., ... 68
Potential cautery, ... 74

PAGE

Abstraction of blood, ... 75
Anodyne friction, ... 78
Counter-irritation, ... 79
Evulsion of eyelashes, ... 79
Foreign bodies in the oculo-palpebral space of the conjunctiva, and their removal, ... 80
Evacuation of the aqueous humor by puncture of the cornea, 83

CHAPTER II.

OPHTHALMIC INFLAMMATION.

SECTION I.—INFLAMMATION IN GENERAL, . . 84

INFLAMMATION PROPER, ... 84
TERMINATIONS OR EVENTS OF INFLAMMATION, . . 84
DISTINCTION OF INFLAMMATION INTO ACUTE AND CHRONIC, 86

SECTION II.—OPHTHALMIC INFLAMMATION IN GENERAL, 86

INFLAMMATION AS IT OCCURS IN THE DIFFERENT TISSUES OF THE EYE, ... 87

Conjunctivitis, or inflammation of the conjunctiva, . . 87
Sclerotitis, or inflammation of the sclerotica, . . 91
Corneitis, or inflammation of the cornea, ... 92
Iritis, or inflammation of the iris, ... 99
Choroiditis and retinitis, or inflammation of the choroid and retina, ... 101
Inflammation of the lenses of the eye, ... 102

Morbid sensations depending on perversion of common sensibility, accompanying inflammation of the different tissues, 103
Morbid sensations depending on perversion of the special sensibility of the retina, ... 104

CAUSES OF OPHTHALMIC INFLAMMATION, . . . 108

TREATMENT OF OPHTHALMIC INFLAMMATION, . . . 109

General—Antiphlogistic treatment, ... 110
General—Tonic and alterative treatment, . . . 112
Local—Antiphlogistic and soothing treatment, . . 112
Local—Irritating applications, ... 113

PAGE

SECTION III.—THE OPHTHALMIÆ, . . . 114

ORDER I.—OPHTHALMIA EXTERNA, ... 115

GENUS I.—CONJUNCTIVITIS, ... 115

Pustular ophthalmia, ... 115
Catarrhal ophthalmia, ... 116
Egyptian ophthalmia, ... 121
Ophthalmia of new-born infants, ... 127
Gonorrhœal ophthalmia, ... 131
Mild gonorrhœal ophthalmia, ... 132
Puro-mucous ophthalmia occurring in female children, in connection with puro-mucous discharge from the vagina, 132
Erysipelatous ophthalmia, ... 133

GENUS II.—SCLEROTITIS, ... 134

Rheumatic ophthalmia, ... 134
Scrofulous sclerotitis, ... 136

GENUS III.—CORNEITIS, ... 137

Scrofulous or phlyctenular ophthalmia, ... 138
Scrofulous corneitis, ... 143
Acute or erethitic form, ... 143
Chronic or torpid form, ... 146
Rheumatic corneitis, ... 146

GENUS IV.—COMPOUND EXTERNAL OPHTHALMIA, . . 147

Scrofulo-catarrhal ophthalmia, ... 147
Catarrho-rheumatic ophthalmia, ... 151

ORDER II.—OPHTHALMIA INTERNA ANTERIOR, . . 153

GENUS I.—AQUO-CAPSULITIS, ... 156

Aquo-capsulitis, ... 156

GENUS II.—IRITIS, ... 158

Scrofulous iritis, ... 158
Rheumatic iritis, ... 159
Syphilitic iritis, ... 161
Arthritic iritis, ... 163

GENUS III.—CRYSTALLINO-CAPSULITIS ANTERIOR, . 166

Crystallino-capsulitis anterior, ... 166

PAGE

ORDER III.—OPHTHALMIA INTERNA POSTERIOR, . . 167

Scrofulous posterior internal ophthalmia, . . . 169
Arthritic posterior internal ophthalmia, ... 171

ORDER IV.—PANOPHTHALMITIS, ... 174

GENUS.—PANOPHTHALMITIS, ... 175

Phlegmonous panophthalmitis, ... 175

APPENDIX TO THE PRECEDING SECTION, . . . 177

Scarlatinous and morbillous ophthalmia, . . . 177
Variolous ophthalmia, ... 178
Post-febrile ophthalmitis, ... 179
Phlebitic ophthalmitis, ... 180
Traumatic and sympathetic ophthalmia, . . . 181

SECTION IV.—VARIOUS MORBID STATES OF THE EYE, CONSEQUENCES OF THE OPHTHALMIÆ, . . 182

Granular conjunctiva, ... 182
Vascular cornea and pannus, ... 186
Cuticular conjunctiva, ... 187
Onyx and abscess of the cornea, ... 188
Ulcers of the cornea, ... 188
Suffusion, opacities, and specks of the cornea, . . 189
Hernia of the cornea (keratocele), ... 191
Prolapsus iridis, ... 192
Staphyloma of the cornea and iris, ... 192
Partial staphyloma, ... 192
Total spherical staphyloma, ... 193
Hypopyon, ... 200
Prominent cornea and dropsy of the aqueous chambers, . 201
Synechia, ... 201
Closure of the pupil, ... 202
Iridauxesis, ... 202
Sclerotic staphyloma, ... 203
Synchysis, ... 204
Atrophy of the eyeball, ... 205
Shrunk state of the eyeball from evacuation of humors, . 206

APPENDIX TO THE PRECEDING SECTION, . . . 206

Adaptation of an artificial eye, ... 206

CHAPTER III.

PAGE

SECTION I.—DROPSIES, TUMOR, CANCER, ETC., OF THE EYE-BALL, ... 208

Conical cornea, ... 208
Hydrophthalmia, ... 211
Hæmophthalmus, ... 214
Hydatid (cysticercus cellulosæ) in the anterior chamber, . 215
Non-malignant tumors of the eyeball, ... 218
Scirrhus of the eyeball, ... 221
Medullary or encephaloid fungus of the eyeball, . . 221
Melanosis of the eyeball, ... 226

Operation of extirpation of the eyeball, . . . 228

SECTION II.—CATARACT, ... 230

GENERA AND SPECIES OF CATARACT, ... 230

LENTICULAR CATARACT, ... 231

Hard or common lenticular cataract of old people, . . 232
Soft or common lenticular cataract of young people, . 237

CAPSULAR CATARACT, ... 238

Anterior capsular cataract, ... 238
Posterior capsular-cataract, ... 239

CAPSULO-LENTICULAR CATARACT, ... 239

Central capsulo-lenticular cataract, ... 240
General capsulo-lenticular cataract, . . . 240
Siliquose cataract, ... 241

OPERATIONS FOR CATARACT, ... 241

General observations and questions regarding the operations for cataract, ... 241

EXTRACTION OF THE CATARACT, ... 247
Extraction of the hard or common lenticular cataract of old persons, ... 247
Extraction of capsulo-lenticular cataract, . . . 265
Extraction of siliquose cataract, ... 266

PAGE

DISPLACEMENT OF THE CATARACT AND ITS MODIFICATIONS, 266

Reclination by sclerotic puncturation, . . . 268
Reclination by corneal puncturation, . . . 272

DIVISION OF THE CATARACT, ... 274

Division of the cataract by sclerotic puncturation, . 275
Division of the cataract by corneal puncturation, . . 278
Operation for cataract in infants, ... 280
Secondary cataract, ... 280
Comparative advantages and disadvantages of extraction, displacement, and division, ... 281
Cataract glasses, ... 282

SECTION III.—OPERATIONS FOR ARTIFICIAL PUPIL, 283

General conditions necessary, or at least favorable to the success of operations for artificial pupil, . . . 284

ARTIFICIAL PUPIL BY INCISION, ... 285

Incision through the sclerotica, ... 285
Incision through the cornea, ... 287

ARTIFICIAL PUPIL BY EXCISION, ... 289

Lateral excision, ... 290
Central excision, ... 293

ARTIFICIAL PUPIL BY SEPARATION, . . . 293

Separation through the cornea, ... 294

OPERATIONS FOR AGAIN RENDERING THE NATURAL PUPIL AVAILABLE, ... 297

Restoration to its natural position by abscission, . . 297
Dislocation of the pupil to opposite a clear part of the cornea, 298

INDEX OF THE DIFFERENT MORBID STATES OF THE EYE, IN WHICH VISION MAY BE RESTORED BY THE OPERATION FOR ARTIFICIAL PUPIL, AND OF THE PLAN OF OPERATING, OR MODIFICATION OF IT ADAPTED TO EACH PARTICULAR STATE, 300

SECTION IV.—CONGENITAL DEFECTS OF THE IRIS AND PUPIL, ... 301

Congenital absence of the iris, ... 301
Congenital fissure of the iris, ... 302
Congenital imperforation of the iris, ... 304

CHAPTER IV.

PAGE

SECTION I.—ABNORMAL STATES OF THE OPTICAL REFRACTIONS AND ADJUSTMENTS OF THE EYE, . 304

MYOSIS AND MYDRIASIS, ... 304

Conditions on which the movements of the pupil depend, . 304
Myosis, ... 307
Mydriasis, ... 308

MYOPY, OR SHORTSIGHTEDNESS, AND PRESBYOPY, OR FARSIGHTEDNESS, ... 308

Refraction by convergent lenses and the adjustment of the eye to different distances, ... 309
Shortsightedness, ... 310
Farsightedness, ... 314

Cylindrical eye, ... 317
Unequally refractive state of the two eyes, . . 517
Loss of power of adjustment, ... 318
Chromatic vision, ... 318
Diplopy and polyopy with one eye, ... 318
Asthenopy or weaksightedness, ... 319

SECTION II.—VISION OF OBJECTS IN AND ON THE EYE, . 322

VISION OF OBJECTS IN THE EYES, ... 322

Common muscæ volitantes, ... 322
Spectrum of the vascular ramifications and network of the retina, ... 326
Circulatory spectrum, ... 326

VISION OF OBJECTS ON THE EYES, ... 327
Muco-lacrymal muscæ, ... 327

CHAPTER V.

AMAUROTIC AFFECTIONS.

SECTION I.—INTRODUCTION.—ABNORMAL EXCITEMENT OF VISUAL SENSATIONS, ... 327

Sensations of light and color, independent of external light,

PAGE

excited by internal influences operating on the optic nervous apparatus, ... 327
Reciprocal action of the different parts of the retina on each other's sensation, ... 329
Spectra consequent to impressions on the retina and complementary colors, ... 330

SECTION II.—IMPAIRMENT AND LOSS OF SENSIBILITY OF THE OPTIC NERVOUS APPARATUS, OR AMAUROSIS IN ITS VARIOUS DEGREES, ... 331

Defective perception of colors, ... 332
Temporary hemiopy, ... 332
Night-blindness, ... 333
Day-blindness, ... 335
Fixed muscæ, ... 335

AMAUROSIS, ... 336

Amaurosis considered empirically, ... 336
Amaurosis considered pathologically, ... 340
Amaurosis considered therapeutically, ... 343

SECTION III.—GLAUCOMA AND CAT'S EYE, . . . 345

GLAUCOMA, ... 345

Simple glaucoma, ... 346
Simple glaucoma with cataract, ... 346
Chronic glaucoma with amaurosis, ... 347
Chronic glaucoma with amaurosis and cataract, . . 347
Acute glaucoma with amaurosis, ... 347

CAT'S EYE, ... 347

CHAPTER VI.

SECTION I.—LOSS OF CORRESPONDENCE OF THE SENSATIONS AND MOVEMENTS OF THE TWO EYES, . 348

Correspondence between the sensations of the two eyes, . 348
Single vision with two eyes, ... 349
Natural double vision with two eyes, ... 353
Correspondence in the movements of the two eyeballs, . 353

LOSS OF CORRESPONDENCE IN THE SENSATIONS OF THE TWO EYES, ... 356

Diplopy or double vision with two eyes, . . . 356

PAGE

Loss of Correspondence in the Direction of the two Eyes, 358

Strabismus, or squinting, and luscitas, or immovable distortion of the eyeballs, ... 358
Strabismus convergens, ... 359
Strabismus divergens, ... 365
Strabismus sursumvergens and strabismus deorsumvergens, 365
Paralysis of the muscles supplied by the nerve of the third pair, ... 366
Paralysis of the muscles supplied by the nerve of the fourth pair, ... 369
Paralysis of the muscles supplied by the nerve of the sixth pair, ... 369
Oscillation and nystagmus of the eyeballs, ... 370

CHAPTER VII.

DISEASES OF THE EYELIDS.

Section I.—Inflammations and Ulcerations of the Eyelids, ... 371

Phlegmonous inflammation of the eyelids, ... 372
Erysipelatous inflammation of the eyelids, ... 372
Variolous inflammation of the eyelids, ... 373
Carbuncle and malignant pustule of the eyelids, . . 373
Ophthalmia tarsi, ... 374
Catarrhal ophthalmia tarsi, ... 374
Scrofulous ophthalmia tarsi, ... 376
Hordeolum, or stye, ... 378
Inflammation and abscess of the Meibomian glands, . 379
Syphilitic affections of the eyelids, ... 379

Section II.—Abnormal Position of the Eyelids, Misdirection of the Eyelashes, Irregularity and Loss of Movements of the Eyelids, etc., . 381

Ectropium or Eversion of the Eyelids, . . 381

Ectropium from excoriation and contraction of the skin of the eyelid, together with a thickened and sarcomatous state of the conjunctiva, ... 381
Ectropium from contraction of the skin in consequence of cicatrices, &c., ... 385
Ectropium from caries of the orbit, ... 392

Entropium or Inversion of the Eyelids, . . 393

Entropium from relaxation of the integuments of the eyelid, and spasmodic contraction of the orbicularis palpebrarum muscle, ... 394

PAGE

Entropium from a contracted and deformed state of the tarsal cartilage, ... 396
Trichiasis and distichiasis, ... 398
Lagophthalmos, ... 401
Lagophthalmos from paralysis of the orbicularis palpebrarum, 401
Lagophthalmos from organic contraction or adhesions of the eyelids, ... 402
Congenital lagophthalmos, ... 403
Ptosis or falling down of the upper eyelid, . . . 403
Ptosis from paralysis of the nerve of the third pair, . . 403
Ptosis from injury of levator palpebræ muscle, . . 403
Ptosis from extension and relaxation of the skin, or of the whole substance of the eyelid, ... 404
Congenital ptosis, ... 404
Epicanthus, ... 404

SECTION III.—MORBID CONNECTIONS OF THE EYELIDS, 405

Anchyloblepharon, ... 405
Symblepharon, ... 407

SECTION IV.—TUMORS, CANCER, ETC., OF THE EYELIDS AND EYEBROWS, ... 408

Phlyctenulæ on the borders of the eyelids, from obstruction of the Meibomian apertures and retention of the secretion, 408
Meibomian calculus, ... 408
Enlargement and induration of the Meibomian glands, . 408
Abnormal occurrence of a sebaceous gland in the palpebral conjunctiva of the upper eyelid, ... 408
Vesicles or phlyctenulæ on the cutaneous surface of the eyelid near its margin, ... 408
Warts on the eyelids, ... 409
Horny-like excrescences connected with the skin of the eyelids, ... 409
Milium, ... 409
Thickwalled encysted tumors, ... 410
Chalazion, or tarsal tumor, ... 410
Encysted tumor, ... 411
Hydatids in the cellular substance of the eyelids, . . 411
Nævus maternus and aneurism by anastomosis of the region of the eyelids, ... 411
Scirrhoid callosity of the eyelids, ... 412
Cancer of the eyelids, ... 412
Phtheiriasis of the eyebrows and eyelashes, . . . 413

CHAPTER VIII.

PAGE

SECTION I.—DISEASES OF THE CONJUNCTIVA, . . 414

Pterygium, ... 414
Pinguecula, ... 416
Trichosis bulbi, ... 416
Abnormal development, or hypertrophy of the conjunctiva corneæ, ... 417
Fungous excrescence of the conjunctiva corneæ, . . 417
Various kinds of tumors of the conjunctiva, . . . 417
Hydatids in the cellular tissue under the sclerotic conjunctiva, 417
Filaria medinensis, or Guinea worm, ... 419

SECTION II.—DISEASES OF THE SEMILUNAR FOLD AND LACRYMAL CARUNCLE, ... 419

Inflammation of the semilunar fold and lacrymal caruncle, 419
Catarrhal inflammation of the semilunar fold and lacrymal caruncle, ... 419
Inflammation and abscess of the lacrymal caruncle, . 420
Chronic enlargement of the lacrymal caruncle and semilunar fold, ... 420
Polypous and fungous excrescences of the lacrymal caruncle and semilunar fold, ... 421
Cancer of the lacrymal caruncle, ... 421

CHAPTER IX.

DISEASES OF THE LACRYMAL ORGANS.

SECTION I.—DISEASES OF THE SECRETING LACRYMAL ORGANS, ... 422

Disordered state of the lacrymal secretion, . . . 422
Suppression of the lacrymal secretion, ... 422
Epiphora or watery eye, ... 423
Inflammation of the lacrymal gland, ... 423
Fistula of the lacrymal gland, or true lacrymal fistula, . 424
Extirpation of tumors in the neighborhood of the lacrymal gland, or of the diseased gland itself, . . . 424

PAGE

SECTION II.—DISEASES OF THE DERIVATIVE LACRYMAL PASSAGES, ... 426

Inflammatory swelling, abscess, or sinuous ulcer in the region over the lacrymal sac, ... 426
Catarrhal inflammation of the derivative lacrymal passages, . 427
Acute inflammation of the derivative lacrymal passages, . 428
Chronic inflammation of the derivative lacrymal passages, . 429
Atony or relaxation of the lacrymal sac, ... 431
Mucocele, ... 432
Exostosis of the inner and posterior wall of the lacrymal fossa, 433
Fistula of the lacrymal sac, ... 433
Atony or relaxation of the papillæ, with a dilated state of the puncta, ... 433
Shrunk papillæ and contracted state of the puncta, . . 433
Obliteration or obstruction of the lacrymal puncta and canalicules, ... 434
Exploration of the nasal duct, to determine whether it is obstructed or obliterated, ... 436
Obstruction of the nasal duct, and the different operative methods adopted with a view to remove it, and to restore a passage to the tears, ... 441
Obliteration of the nasal duct, ... 445
Lacrymal calculi, ... 445

CHAPTER X.

DISEASES OF THE ORBIT.

SECTION I.—INFLAMMATIONS, ETC., OF THE ORBIT, . 446

Inflammation of the orbital cellular tissue, . . 446
Inflammation of the periorbita and bones of the orbit, . 449

SECTION II.—ORBITAL GROWTHS AND TUMORS, . 449

Infiltration of the orbital cellular tissue, . . . 450
Sarcomatous tumors in the orbit, ... 451
Encysted tumors in the orbit, ... 451
Operation of extirpating sarcomatous and encysted orbital tumors, ... 451
Hydatidgenous cysts in the orbit, ... 452
Medullary tumor in the orbit, ... 452

PAGE
Melanotic tumor in the orbit, ... 453
Aneurism by anastomosis in the orbit, ... 453
True aneurism in the orbit, ... 453

CHAPTER XI.

INJURIES OF THE EYE.

SECTION I.—INJURIES OF THE CONJUNCTIVA AND EYEBALL, ... 453

INJURIES OF THE CONJUNCTIVA FROM INTRUSION OF FOREIGN BODIES INTO THE OCULO-PALPEBRAL SPACE, . . 453

Mechanical injuries, ... 454
Chemical injuries, ... 454

INJURIES OF THE EYEBALL AND ITS PROPER TUNICS, . . 456

Concussion of the eyeball, ... 456
Contused wounds of the eyeball, ... 457
Injuries of the cornea, ... 457
Inflammation from abrasion of the cornea, . . . 460
Foreign bodies in the aqueous chambers, . . . 461
Injuries of the iris and pupil, ... 463
Injuries of the crystalline body, ... 463
Wounds of the sclerotic and posterior segment of the eyeball, 467
Dislocation of the eyeball, ... 468
Evulsion of the eyeball, ... 468

SECTION II.—INJURIES OF THE EYEBROW AND EYELIDS, . 468

Contusion with ecchymosis, ... 468
Incised, lacerated, and contused wounds of the eyebrows and eyelids, ... 469
Poisoned wounds, ... 469
Burns and scalds, ... 470

SECTION III.—INJURIES OF THE LACRYMAL ORGANS, . 470

Injuries of the lacrymal gland and ducts, . . . 470
Injuries of the derivative lacrymal organs, . . . 471

PAGE

SECTION IV.—INJURIES OF THE ORBIT, . . . 472

Blows, &c., on the edge of the orbit, ... 472
Penetrating wounds of the orbit, ... 472

GLOSSARY, ... 473

INDEX, ... 479

LIST OF WOOD ENGRAVINGS, ... xxv

EXPLANATION OF THE PLATES, ... xxix

LIST OF WOOD ENGRAVINGS.

FIGURE		PAGE
1.	Ducts of the lacrymal gland,	44
2, 3.	Diagrams illustrating the ophthalmoscope,	49
4.	Characters of conjunctival and sclerotic vascularity,	52
5.	Natural appearance of the iris and pupil in profile,	57
6.	Abnormal, " " " "	57
7.	Instrument with a small aperture for testing the sight in mydriasis,	65
8.	Forceps for plucking out eyelashes,	79
9.	Knife for evacuating aqueous humor,	83
10.	Central opacity of the cornea concealing the pupil,	91
11.	The same eye with the pupil dilated by belladonna,	91
12.	Partial staphyloma,	92
13.	Total spherical staphyloma,	93
14.	Staphyloma knife,	99
15.	Prominent cornea and dropsy of the aqueous chambers,	201
16.	Iridauxesis (from Klemmer),	203
17.	Conical cornea,	208
18.	Appearance of bulging retina in subchoroid dropsy,	214
19.	Medullary fungus in the early stage,	225
20.	Anterior radiated fissures of the lens,	231
21.	The stellate appearance in cataract,	231

FIGURE PAGE

22. The shadow thrown by the pupillary margin of the iris on the surface of a cataract, ... 232
23. Mode of securing the eyelids for operations for cataract and other operations on the eyeball, ... 246
24, 25, 26. The different sections of the cornea in the operation of extraction of the cataract, ... 249
27. A cataract knife, ... 249
28. The act of making the lower section of the cornea, . . 250
29. Mode of holding the cataract knife, ... 251
30. Probe-pointed convex-edged knife, ... 253
31. Mode of completing section of the cornea by the convex-edged knife, ... 254
32, 33. Faulty sections of the cornea, ... 254
34. Knife for enlarging the corneal section, ... 255
35, 36. Daviel's scissors, ... 256
37. Instrument for opening the capsule of the lens in extraction, 257
38. Daviel's curette or spoon, ... 258
39. Small hook, ... 259
40. Coevring for the eye after operation, ... 260
41. Maunoir's scissors, ... 264
42. Fine hooked forceps, ... 266
43. Diagram illustrating couching of the cataract, . . 267
44. Diagram illustrating reclination, ... 267
45, 46. Cataract needles, straight and curved, . . . 267
47. Diagram illustrating sclerotic puncturation with a curved needle, ... 269
48. Diagram illustrating reclination through the cornea, . 272
49. Diagram illustrating division through the cornea, . . 278
50. Diagram illustrating artificial pupil by incision through the sclerotica, ... 286
51. Adams' iris knife, ... 286
52. Diagram illustrating the operation by incision through the sclerotica, ... 287

FIGURE PAGE

53, 54, 55, 56. Diagrams illustrating artificial pupil by incision through the cornea, ... 288
57. Maunoir's scissors, ... 288
58. Hooked forceps, ... 291
59. Mode of holding the curved scissors, . . . 292
60. Artificial pupil by lateral excision, ... 293
61. Diagram illustrating artificial pupil by central excision, . 293
62. Diagram illustrating artificial pupil by separation, . . 294
63. Jäeger's keratome, ... 295
64. Simple hook, ... 295
65. Illustration of artificial pupil by separation and prolapse of the separated portion of iris through the cornea, . . 297
66. Tyrrell's hook, ... 299
67. Coloboma iridis, ... 303
68. Instrument with a small aperture for testing the sight in mydriasis, ... 308
69. Common muscæ volitantes, ... 322
70. Diagram illustrating complementary colors, . . . 330
71. Diagrams for stereoscopic experiment, ... 351
72. Diagram from Ruete, illustrating the axis of revolution on which the eyeball is moved by its different muscles, . . 354
73. Blunt hook for operation of strabismus, . . . 363
74, 75. Illustrations of Adams' operation for ectropium, . 383, 384
76. Illustration of the operation for ectropium by transplantation of skin, ... 387
77, 78. Illustrations of the Author's operation for ectropium, . 389
79. Illustration of Dieffenbach's operation for ectropium, . 390
80, 81. Illustration of eversion at the outer angle, and Walther's operation of *tarsoraphia*, ... 391, 392
82, 83. Ectropium from caries of the orbit, and Ammon's operation, ... 392, 393
84. Graefe's entropium forceps, ... 395
85. Trichiasis, ... 398

FIGURE PAGE

86. Horn spatula for introducing behind the eyelids in operating on them, ... 400
87. Pterygium, ... 414
88. Trichosis bulbi, ... 416
89. Knife for incision of the lacrymal sac, . . . 438
90. Operation of incision of the lacrymal sac, . . . 439
91. Catgut style for dilating the nasal duct, . . . 442
92, 93. Metallic styles, ... 442
94, 95. Gold tubes for insertion into the nasal duct, . . 443
96. Conductor or handle for inserting the tube, . . . 444

EXPLANATION OF THE PLATES.

PLATE I.

FIGURE 1.—This represents catarrhal inflammation of the conjunctiva, as described at pp. 88 and 116; and also the mode of examining the conjunctival surface of the lower eyelid, as described at p. 43.

FIGURE 2.—A well-developed granular state of the conjunctiva of the upper eyelid in Egyptian ophthalmia, as described at pp. 122 and 182. The enlarged papillæ are separated into groups by furrows or fissures. The figure also illustrates the mode of examining the conjunctival surface of the upper eyelid, as described at p. 43.

FIGURE 3.—A case of phlyctenular, or scrofulous ophthalmia, in which there is a burst phlyctenula on the cornea, with a fasciculus of vessels running from the conjunctiva into it, as described at p. 139. This figure also illustrates the mode of examining the eye in such cases, which occur in children, and in which there is great intolerance of light, as described at p. 50.

FIGURE 4.—This figure represents a case of iritis, as above described at pp. 99, et seq.; and also illustrates the mode of depressing the lower eyelid for examination of the front of the eyeball. See p. 48.

PLATE I.

FIG. 1.

FIG. 2.

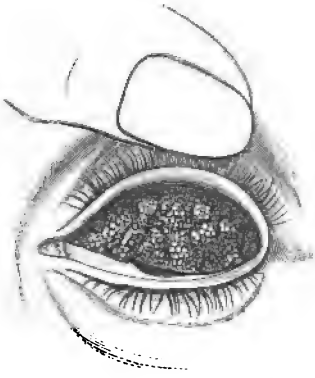

FIG. 3.

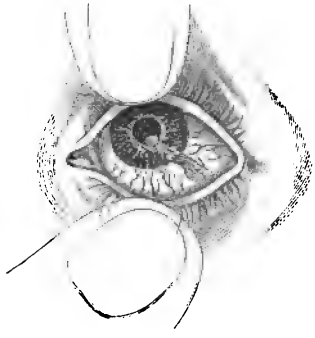

FIG. 4.

PLATE II.

FIGURE 1.—Inflammation of the ciliary body and corresponding part of the sclerotica, with secondary iritis. Near the outer margin of the cornea, the sclerotica is thickened and yellowish-looking; elsewhere it is purplish. There are two spots of opacity of the cornea at its outer edge.

FIGURE 2.—Arthritic posterior internal ophthalmia, as described at pp. 171, et seq. The figure also illustrates the mode of raising the upper eyelid for examination of the front of the eyeball. See p. 48.

FIGURE 3.—This represents a case of medullary fungus of the eyeball in its second stage, as described at p. 221, et seq.

FIGURE 4.—A case of sclerotic staphyloma from traumatic inflammation of the eye. In this figure there is a good representation of varicose vessels. See pp. 169, 170, 203, et seq.

PLATE II.

FIG. 1.

FIG. 2.

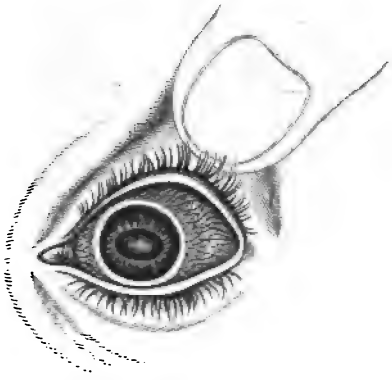

FIG. 3.

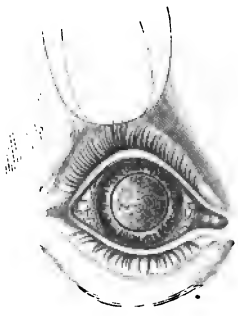

FIG. 4.

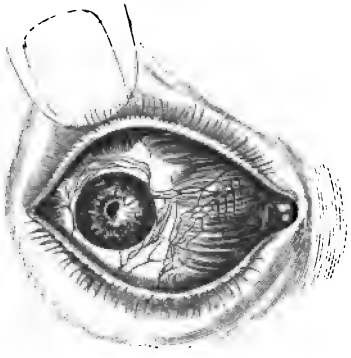

PLATE III.

FIGURE 1.—A case of melanosis of the eyeball, in which the iris has been detached at one part of its circumference, and the black mass is making its appearance from behind, as also through the sclerotica near the cornea. See p. 226.

FIGURE 2.—The third case of hydatid in the anterior chamber, referred to at p. 216. The body and head of the animal are protruded from the tail vesicle.

FIGURE 3.—Represents a case of dislocation of the lens into the anterior chamber; the lens being still clear, see p. 465. This figure also illustrates the mode of fully exposing the front of the eyeball for examination, as above described at p. 48.

FIGURE 4.—Represents the third case of cyst, in connection with the iris, above described at p. 220.

PLATE III.

FIG. 1.

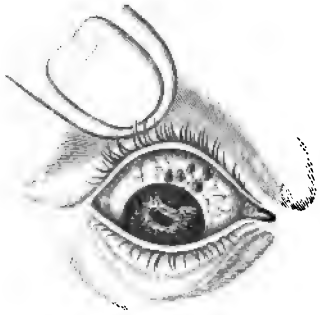

FIG. 3.

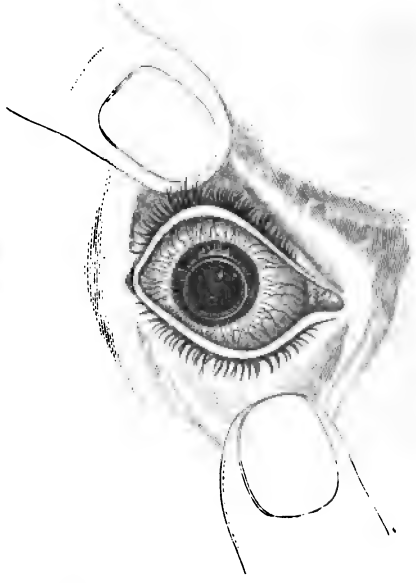

FIG. 2.

FIG. 4.



PLATE IV.

FIGURE 1.—This represents a case of granular conjunctiva with pannus. The lower eyelid is held everted, to show the vesicular granulations just within its border, and also on the conjunctiva of the lower palpebral sinus. The upper lid is slightly elevated, to allow the upper part of the cornea, which is the seat of the pannus, to be fully seen.

FIGURE 2.—The bottom of the left eye in a case of amblyopia, as seen by means of the ophthalmoscope. The retina is congested and its transparency somewhat impaired.

PLATE IV.

FIG. 1.

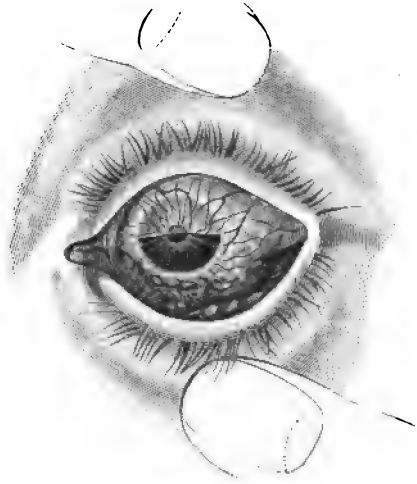

FIG. 2.

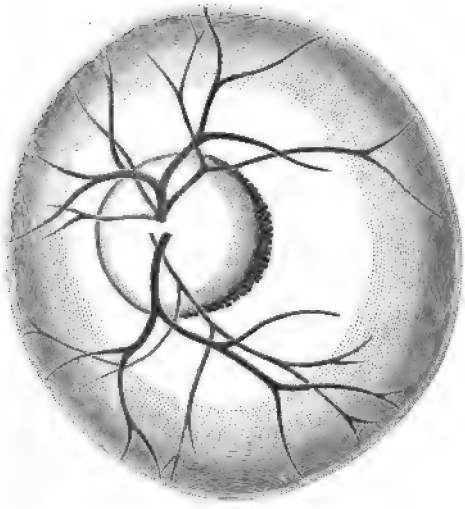

OPHTHALMIC

MEDICINE AND SURGERY.

CHAPTER I.

Section I.—Ophthalmoscopy, or, Exploration of the Eyes in order to a Diagnosis.

In exploring the eyes for the purpose of establishing a diagnosis, attention has to be directed, on the one hand, to such material changes in the constitution of those organs as the surgeon himself can directly see or touch, or, at least, infer from cognizable marks or symptoms;—and, on the other hand, to the disturbance of sight, pain, and other morbid sensations in the affected organs, regarding which the patient himself can alone furnish explicit information—though even on this head the surgeon may also infer something from his own observation.

The first of these two kinds of exploration is called *objective;* the second, *subjective.*

OBJECTIVE EXPLORATION OF THE EYES.

At first the eyes should be viewed merely, *not touched.* This precaution it is important to observe, especially in inflammations, in order to avoid causing an increased determination of blood, lacrymation, &c., which, in such cases, are apt to be occasioned by the slightest touch, and which might complicate the appearance natural to the inflammation, and give an erroneous view of the nature of the case. In an hospital, the pupils should not, on any account,

be permitted to touch the eyes of a patient, before the surgeon has made his examination.

The surgeon should, in succession, glance at the eyebrows and orbital margins, the eyelids and their movements, the borders of the eyelids and state of the eyelashes, and the corners of the eyes, noting the presence or absence of lacrymation. He should then pass in review the form and appearance of the eyeballs generally—their size and degree of prominence—movements and direction—the correspondence of their axes—the appearance and color of the white of the eye—the aspect of the cornea—the color of the iris—and the state of the pupil.

The general bearing of the patient, and the expression of his features, should not be left unobserved. The information thus obtained, will sometimes reveal the nature of the case, or will guide in the further exploration of it. By the general bearing of the patient, and the expression of his features, it will be seen, for example, if he is affected with intolerance of light—if he be blind from amaurosis, or blind from cataract.

The patient, intolerant of light, keeps his head bent down, and covers his eyes with his hands, in order to protect them from the light [or hides his head in a pillow or the bedclothes, or seeks the darkest corner of the room]. The eyelids are spasmodically closed, and at the same time the eyebrows are knit and depressed, and the cheeks drawn up so that there is great distortion of the whole features. There is greater or less lacrymation.

Whilst the confirmedly amaurotic patient moves about with an air of uncertainty, his head erect, and the eyes wide open—not converged and fixed on any object, but staring forward as if on vacancy—perhaps moving about in a vacillating manner, or squinting, the cataractous patient is more steady in his gait; and with his head bent forwards, his eyes half-closed, his eyebrows knit and depressed, he moves and directs the eyes naturally and steadily, in an exploratory manner.

This survey, constituting the first step in the objective exploration of the eyes, may be taken during the time the patient is coming into the room, and relating the history of his case. In the subsequent steps of the objective exploration, attention should be carefully directed to the relations which may exist between the appearances observed and the patient's sensations—pain, tolerance or intolerance of light, and state of vision as elicited in the subjective exploration.

Most probably the general objective survey, now indicated, in conjunction with the subjective examination, to be spoken of by-and-by, will direct the practitioner to the seat of the disease. On this part he will accordingly fix his attention, and subject it to the

detailed scrutiny necessary to enable him to discriminate exactly the nature of the case. The account of the mode of conducting the objective exploration of the different parts of the eye in detail, to which I now proceed, will necessarily include references to the principal morbid conditions of the organ,—in fact, will constitute an epitome of the pathology of the eye.

Exploration of the eyebrows, and orbital margins.

The affections of the eyebrows and orbital margins do not require much exploration for their diagnosis, a glance and a few touches being in general sufficient, except in the case of a fistulous opening in the margin of the orbit, when it may be necessary to introduce a probe to ascertain the extent and direction of the fistula, and state of the bone.

The skin forming the boundary of the inner canthus of the left eye of a man who had syphilis about two years before, was the seat of what appeared a small ulcer covered with sloughy-looking matter. On probing this, the instrument could be passed on to some depth, and by directing its point downwards, it entered the nose.

In injuries and affections of the eyebrow and orbital margins, the eyelids are almost necessarily more or less implicated; and it is to be remarked, that in the case of blows, contusions and wounds of the eyebrow and margin of the orbit, there may have occurred injury of the fifth pair, concussion of the retina, or even of the brain, and, as a consequence, amaurosis.

In the exploration, attention is directed to the state of the skin all around the margin of the orbit, and of the hairs of the eyebrow. The skin may be the seat of an eruption, or of cicatrices. The hairs may have fallen off, or they may be the seat of phtheiriasis. Tumors will not unfrequently come under notice in the eyebrows, or connected with the margin of the orbit. The injuries met with are burns, from which the eyelids in general suffer most; contusions and wounds with ecchymosis.

The affections found more particularly seated in the margin of the orbit, besides fracture, &c., which may complicate the injuries just referred to, are inflammation and abscess, involving the periosteum and bone. Abscess manifests itself by a dark-red swelling, which at last bursts and discharges a thin or curdy matter. The carious or necrosed bone is felt bare and rough, on the introduction of a probe through the opening, now become fistulous. Lastly, the margin of the orbit may be thickened from periostosis, or hyperostosis, or be the seat of an exostosis, or of an osteosarcomatous tumor.

Exploration of the eyelids, and their tarsal border, including the state of the cilia and Meibomian apertures.

The points to be noticed in regard to the eyelids, are :—first, their position, their connections, and their movements; then their organic condition generally, and that of their tarsal border in particular; the direction of the eyelashes, the state of the Meibomian apertures, and of the Meibomian discharge, as indicated by the presence or absence of incrustation of the eyelashes.

The morbid changes in position, which the eyelids may be found to present, are, *eversion* or *ectropium*, *inversion* or *entropium*, *retraction* and *shortening* or *lagophthalmus*. The morbid connections are, adhesion to each other's edges, or *anchyloblepharon*, which may be either mediate or immediate, total or partial, congenital or accidental; and adhesion of the inner surface of one or both eyelids to the globe, or *symblepharon*, which may likewise be mediate or immediate, total or partial.

In proceeding to indicate the morbid changes to which the movements of the eyelids are subject, it may be useful to premise that it is chiefly by the movements of the upper eyelid that the open or closed state of the eye is produced. The upper eyelid is both vertically and horizontally larger than the lower, and in the closed state during sleep covers much more of the front of the eyeball; but in voluntary or forced closure of the eye, the lower eyelid is drawn up, being at the same time impressed with a horizontal movement towards the inner angle, by the action of the orbicularis palpebrarum muscle, and meets the upper lid half way. Or, if the upper lid be immovably retracted under the edge of the orbit, either by disease, or by the finger for the sake of experiment, the lower eyelid can of itself almost entirely cover the whole front of the eyeball. When the action of the orbicularis ceases, the lower eyelid falls back into its former state by its own elasticity and that of the skin of the cheek. It is by the levator palpebræ, that the open state of the upper eyelid is maintained. In winking, the upper eyelid falls and the lower rises considerably, in consequence of the momentary action of the orbicularis.

Nictitation may be observed to be morbidly frequent. The eyelids may be affected with a twitching or quivering motion, which is, however, sometimes so slight as not to be very apparent to the observer, though felt by the patient himself as a very annoying throbbing. Or, they may be spasmodically closed intermittently, or remittently, or continuously—a symptom usually of the presence of a foreign particle in the eye, inflammation of the conjunctiva, or of intolerance of light.

The movements again may be defective, or lost from paralysis. There may be a constant open state of the eye, from palsy of the orbicularis muscle—*paralytic lagophthalmus.* Or, the upper eyelid may hang down over the eye from palsy or atony of the levator palpebræ superioris—*paralytic ptosis.* In the former case there will probably be found palsy of the other muscles of the same side of the face; in the latter, on raising the eyelid with the finger, the eyeball will probably be found more or less fixed, incapable of being turned inwards, upwards, or downwards, from concomitant paralysis of those muscles of the eyeball which, in common with the levator palpebræ, are supplied by the third pair of nerves;—perhaps also dilatation of the pupil.

The eyelids may be the subject of various injuries, such as burns and scalds: contusions with ecchymosis, wounds, incised or lacerated, or poisoned, as by the stings of the scorpion, wasp, &c.

The eyelids are sometimes the original and principal seat of erysipelas. In erysipelas of the face they are always involved. They may be the seat of phlegmonous inflammation, in which case, the redness, which is intense, and swelling, are circumscribed, and the part very painful to the touch. Sometimes they present very black sloughs from gangrenous inflammation. Both erysipelatous and phlegmonous inflammation of the eyelids are to be distinguished from the sympathetic inflammatory œdema of these parts, which attends some of the inflammations of the eye, especially the purulent inflammation of the conjunctiva.

The eyelids are often simply œdematous, sometimes emphysematous.

In children the eyelids are frequently affected with porrigo larvalis.

The eyelids may be the seat of syphilitic ulcerations. In infants affected with syphilis, the eyelids, and other parts of the face and body are covered with an eruption of flat broad pustules which break, scab, and spread. Such children have a peculiarly wrinkled and withered expression of face.

The eyelids may be the seat of nævus maternus, of warts, and of different kinds of tumors. Lastly, they may be found cancerous.

In regard to the tarsal borders of the eyelids, it is to be premised that they are broad surfaces. The border of the upper eyelid is about one-twelfth of an inch broad; that of the lower about one-fifteenth. The edge bounding the border anteriorly corresponds to the insertion of the eyelashes and is round. The posterior edge is much sharper and more defined than the preceding, and is the place where the delicate integument of the border of the eyelid is continued into the palpebral conjunctiva. On the border of either eyelid between the two edges or boundaries just described, but nearer

the posterior than the anterior, and parallel to them, there is observable, on close inspection, a row of minute pores—the execretory mouths of the Meibomian follicles. Fig. 1.

The tarsal border of the eyelids may be found inflamed—perhaps ulcerated (*ophthalmia tarsi*), in which case the eyelashes will be incrusted partly with dried Meibomian discharge, partly with the discharge from the ulcers. *Hordeolum*, or stye, is another form of inflammation of the free margin of the eyelids. Inflammation and abscess of the Meibomian follicles simulates the appearance of stye externally, but is a rarer occurrence. The eyelids, at their edges, or close to their edges, may present small tumors, thickening, and callosity, unattended by any great degree of inflammation, viz., chalazion, tylosis, &c.

The eyelashes are sometimes the seat of *phtheiriasis* [*pediculi*], which is apt to be overlooked, except a closer examination be made [with a magnifying glass.] *Madarosis*, or loss of the eyelashes, is at once recognized.

The eyelashes are often found in greater or less numbers turned in against and irritating the eyeball, constituting *trichiasis* and *distichiasis*. The surgeon should always take particular care to assure himself, therefore, of the direction of the eyelashes in cases of chronic ophthalmia; and in order to do so, and to see properly the broad surface of the tarsal border, and the state of the Meibomian apertures, the eyelids should be slightly everted by gentle pressure with the point of the finger on the skin of the eyelid, the eyelashes being kept between the finger and the skin.

By this means it will generally be at once seen if any of the eyelashes are growing in against the eyeball. Sometimes, however, such eyelashes are so pale and fine that they are apt to escape notice. The presence of these may often be detected by attention to the following point when they might otherwise be overlooked:—the tears, of which there is in such cases generally more than usual, rise up around the pale, misdirected eyelashes, and between the eyelid and eyeball, by capillary attraction, and occasion a marked reflection of light at the place. [In searching for these, as well as for other conditions, a magnifying glass is of great service, and ought generally to be employed.]

One or more of the Meibomian apertures may become covered with a thin film, apparently of epidermis, which prevents the escape of the secretion, so that the latter accumulates and raises the film up into a small elevation like a phlyctenula. The Meibomian discharge is increased, whenever there is any irritation of the edges of the eyelids, and especially of the palpebral conjunctiva.

The posterior edge of the tarsal border, which is in its natural state sharply defined, may be found rounded or obliterated, in con-

sequence of chronic inflammation of the palpebral conjunctiva and of the integument of the tarsal border.

Exploration of the conjunctival surface of the eyelids, and of the palpebral sinuses.

The lower eyelid is everted for the purpose of examining its inner surface, by simply drawing down the skin of the lid and cheek; and in order that the lower palpebral sinus may be fully exposed, the patient is to be desired to turn the eyeball upwards, while the lower eyelid is thus held down and everted.

The upper eyelid does not admit of being so readily everted as the lower; and as the operation is attended with some uneasiness to the patient, it ought not to be had recourse to, unless the glimpse of the inner surface of the eyelid, which may be obtained by raising the upper eyelid, and drawing it slightly from contact with the eyeball by pressing up the skin of the eyebrow and eyelid itself, prove insufficient to satisfy the surgeon of the state of parts. [We think that eversion ought to be practised in most cases; certainly, much oftener than it is, and without hesitation on account of the slight discomfort it occasions.] If there is reason to suppose that a foreign body is lodged under the eyelid, then eversion is the only means of detecting and removing it.

In order to evert the upper eyelid, lay hold of the eyelashes between the forefinger and thumb of the right hand, for the right eye—and *vice versa*—in such a way, that whilst the eyelashes are securely held, the points of the thumb and forefinger may extend a little beyond their insertion, so that the former may be applied to the broad border, and the latter to the outer surface of the eyelid. Having thus got a secure hold of the eyelid, draw it away from contact with the eyeball, and then, whilst applying counter pressure downwards on the outer surface of the eyelid, opposite the orbital margin of the tarsal cartilage, raise the ciliary margin upwards. [This manœuvre is much facilitated by the patient's looking downwards.] The counter pressure may be applied either by the thumb of the free hand, or what most people find better adapted to the purpose, by a thick probe [or a lead pencil or quill].

The whole extent of the upper palpebral sinus cannot be exposed like the lower. To explore it a probe must be used, whilst the everted lid is kept as much as possible withdrawn from the eyeball, and the patient directed to turn the eyeball downwards.

By everting the eyelids, the state of the palpebral conjunctiva is ascertained; whether it be inflamed or granular, and whether there be growths connected with or projecting at the inner surface of the eyelids, as chalazia. By the eversion of the eyelids also, foreign

bodies in the eye are readily detected and removed. Small particles are especially apt to adhere to the inner surface of the upper eyelid.

Exploration of the angles of the eye, and of the lacrymal organs, as regards their general state.

The inner and outer corners of the eye, where the eyelids join, are called *canthi*. The outer canthus, generally speaking, forms an acute angle; but on close examination, it is observed that the apex is rounded off, somewhat prolonged and turned slightly downwards. The conformation of the inner canthus is altogether peculiar and rather complicated. At the inner canthus, the palpebral fissure is prolonged into a secondary fissure, the borders of which being destitute of cartilage, are not firm and square, but soft and rounded. The secondary fissure is closed by the action of the orbicularis muscle at the same time as the eyelids. The space within the inner or nasal canthus is called *lacus lacrymalis*.

The state of the outer canthus is readily ascertained by slightly drawing the eyelids from each other. The most ordinary morbid condition met with there, is abrasion or ulceration of the skin. Sometimes there is eversion—sometimes inversion.

Fig. 1.

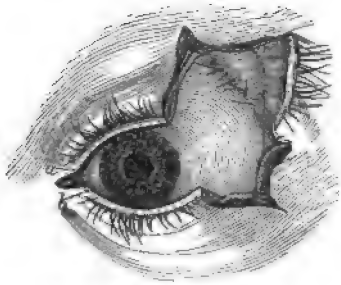

An eye, with the eyelids divided vertically, and the outer halves everted, to show the orifices of the ducts of the lacrymal gland, into which hairs are inserted. The letters *a* and *b* indicate respectively the upper and the lower puncta lacrymalia. Along the border of the eyelids are observed the Meibomian apertures.

The parts situated at the inner canthus are exposed, by drawing the eyelids from each other, and at the same time slightly everting them. At the inner extremity of the border of either eyelid, where the fissure of the nasal canthus begins, the papillary eminence called *lacrymal papilla* is seen, with the small orifice in its summit called *lacrymal point*, of such a size as to admit a bristle. These lacrymal points are, from their larger size and situation, sufficiently

conspicuous not to be confounded with a Meibomian aperture. In the natural state, the lacrymal papillæ are inclined towards the lacus lacrymalis. The lower papilla is somewhat more prominent than the upper, and situated somewhat more towards the temple. At the bottom of the lacus lacrymalis, is the lacrymal caruncle, and between it and the white of the eye, the semilunar fold. The semilunar fold and lacrymal caruncle may be found swoln and enlarged (*encanthis inflammatoria*); sometimes the seat of growths (*encanthis fungosa*).

In reference to the exploration of the state of the secreting lacrymal organs, it is to be remembered that the lacrymal gland consists of two masses, an upper and a lower. The former is that which lies in the lacrymal fossa of the frontal bone; the latter, composed of a loosely connected aggregation of small lobules, extends from the upper mass down to the outer part of the upper margin of the tarsal cartilage of the upper eyelid, in the substance of which it lies at the outer part, and may be seen shining through the conjunctiva on everting the upper eyelid. The ducts of the lacrymal gland are some twelve in number, very slender, and open by as many minute orifices on the surface of the conjunctiva, lining the inside of the upper eyelid, arranged in a row, extending from the outer canthus inwards for about half an inch, and parallel to, but a little above, the outer part of the upper margin of the tarsal cartilage. Fig. 1.

In exploring the derivative lacrymal organs, the appearance of the region of the lacrymal sac should be particularly noted. If there is marked redness, circumscribed swelling, and pain even on the slightest touch, with great œdema of the eyelids, the case is one of *acute dacryocystitis*. If there is less marked redness, merely unnatural fulness, with pain only on pressure, and when pressure is made, if there takes place regurgitation of tears with puriform mucus, through the puncta, the case is one of *chronic dacryocystitis*. If there is a large indolent tumor, more or less hard, perhaps livid, pressure on which does not cause any evacuation of matter either through the puncta or into the nose, the case is one of *mucocele;* it is to be remembered, however, that exostosis of the bony wall behind the lacrymal sac sometimes occurs, causing a tumor of closely similar characters. If there is a large flaccid tumor without pain, much or any redness, readily yielding to the pressure of the finger; and if on that pressure a mucous matter is evacuated through the puncta, but especially into the nose, the case is one of *relaxation of the lacrymal sac*. Lastly, if there is a fistulous opening leading into the sac, the case is one of *fistula of the lacrymal sac*.

A kind of scrofulous inflammation of the skin and subjacent

cellular tissue in the region over the lacrymal sac sometimes occurs, running into diffuse abscess (*anchilops*), which, bursting externally, leaves a sinuous ulcer (*ægilops*). This sinus sometimes communicates by ulceration with the lacrymal sac, constituting what is called *spurious fistula* of it.

The state and position of the lacrymal papillæ and puncta should next be examined.

In addition to the examination now detailed, instrumental exploration of the derivative lacrymal passages may in certain cases be required, to determine the nature and seat of obstruction. But for this, see under the head of diseases of the lacrymal organs. The nostrils at the same time require to be looked to.

The state of the lacrymal discharge is to be noted. If the eye is overflowing in tears, it is to be determined whether this is owing to increased discharge from the gland—*epiphora*—or to diminished or obstructed derivation of the tears towards the nose—*stillicidium lacrymarum*. The point is determined by ascertaining the state of the derivative apparatus. If this is free from disease, the case is one of epiphora; if not, it is one of stillicidium. It is, however, to be observed, that stillicidium and epiphora may coexist.

Examination of the form and appearance of the eyeballs generally, their size and degree of prominence.

The eyeballs, otherwise healthy, may be unusually prominent, apparently from infiltration of the orbital cellular tissue. This state of eyes is sometimes found along with goitre. When the eye is prominent from the presence of a growth in the orbit, it will probably be at the same time misdirected.

In general dropsical enlargement, the eyeball may not be much, if at all misshapen, nor also in the early stages of encephaloid tumor, &c. But in staphylomatous enlargement, and when the encephaloid tumor is much advanced, there is very evident alteration of form and appearance, as well as increase of size and prominence.

In atrophy, the appearance of the eyes, in all these respects, may be little or not at all changed, but it is found soft to the touch. In a greater degree of atrophy, the eyeball is indented in the situation of the insertion of the recti muscles.

Examination of the direction and movements of the eyeballs.

In strabismus, if the properly directed eye be shut, the patient immediately regains command over the previously squinting eye so as to be able to direct it to any object.

Both eyes may be affected with squint, though one only appears to be so. To determine this, in the case of convergent squint, for example, cover the eye which appears well directed, by holding the hand before it, and desire the patient to look straight before him with the previously distorted eye. While he is doing this, look behind the hand at the other eye, and if it now be seen distorted, there is double squint; if, on the contrary, it remains straight, it is not affected, but the squint is confined to the one eye alone.

In monocular squint, the affected eye follows the movements of the sound one, but the latter alone fixes the object. In this case, if the squint be only slightly divergent, it ceases on looking at distant objects;—if, on the contrary, it be only slightly convergent, it ceases on looking at near objects.

It has been above (page 41) remarked, that in paralytic ptosis the eyeball may be found incapable of being turned inwards, upwards, or downwards, from coincident paralysis of the internal, superior and inferior recti muscles, which, in common with the levator palpebræ, are supplied by the third pair of nerves.

Incapacity to turn the eye in the above-mentioned directions may, however, not be accompanied by much, if any, ptosis. The power of the external rectus being unimpaired, the eyeball is readily turned towards the temple. The case, therefore, might at first sight be taken for one of divergent strabismus. The continued inability to turn the eyeball inwards when the opposite eye is shut, will, however, at once distinguish it from that defect; whilst the concomitant paralysis of the superior and inferior recti will point to the nature of the case.

Inability to turn the eyeball outwards indicates paralysis of the external rectus. As there is slight inclination inwards in consequence of the unrestrained action of the internal rectus, the case requires to be distinguished from convergent strabismus. By closing the opposite eye, therefore, it will be seen that the patient is still unable to turn the eye towards the temple.

Such cases of luscitas, or immobility of the eye in a particular direction from paralysis, are to be distinguished from the luscitas depending on organic contraction, &c., of the muscle of the side to which the eyeball is turned.

A partial rotatory movement of the eyeball to and fro on its antero-posterior axis (*oscillation*) may be met with; or a movement from side to side—(*nystagmus*). These irregular movements of the eye are of most common occurrence in persons whose sight has been defective from an early period of life.

Exploration of the front and interior of the eyeball.

The points to be noted in this examination are:—the state of the white of the eye, that is, of the ocular conjunctiva, and of the

anterior part of the sclerotica, including the expansion of the tendons of the recti muscles underneath, the state of the cornea, the state of the iris and pupil, the state of the aqueous chambers and humor, the presence or absence of opaque appearances behind the pupil; and lastly, the degree of prominence and consistency of the eyeball.

Mode of exposing the front of the eyeball for examination.—The patient should be seated before a window, in such a way that the light falls obliquely on the eye to be examined, from the temporal side, whilst the surgeon, placed before the patient, applies the pulp of his thumb on the skin of the upper eyelid, previously well dried, near its ciliary margin, whilst it is gently closed, and raises it by traction of the skin. In doing this, no pressure should be made on the eyeball, but the skin of the raised eyelid may be secured by pressure against the margin of the orbit. The lower eyelid is to be depressed to the extent that is necessary in a similar way, by the fore or middle finger of the other hand. In separating the two eyelids, however, it is to be remembered that when the upper is much raised, the lower should not be much depressed; and when the lower is much depressed, the upper should not be much raised, in order to avoid putting the external commissure too much on the stretch.

The eyelids being thus opened, the surgeon can look directly into the eye, or from any one side, by requesting the patient to move the eye in different directions.

To avoid irritating the eye too much, the eyelids should not be kept more than a few seconds separated at a time; they should be occasionally allowed to close, and after a few seconds, reopened when the examination requires to be prolonged.

In exploring the state of the interior of the eye, illumination greater than is afforded by the window merely, is sometimes necessary. The light concentrated by means of a convex lens, about two inches in diameter, and three or four inches focus, is sufficient for all practical purposes, in the case of the anterior segment of the eyeball, comprising the cornea, aqueous humor, iris, pupil, and crystalline body. For the exploration of the posterior segment comprising the vitreous body, retina, and choroid, an instrument called *ophthalmoscope* or *speculum oculi* has been recently introduced.

The ophthalmoscope in its original form, as invented by Dr. Helmholtz, of Königsberg, consists of a reflector B (Fig. 2), composed of four plates of glass laid one over the other, which is disposed at such an inclination as to throw the light from the flame A into the eye D. The observer's eye C looks through this reflector into the patient's eye in the same direction as that in which the

light is thrown into it. As the rays of light reflected from the illuminated retina of the patient are, after leaving his eye, somewhat converged, it is necessary that they be rendered divergent

Fig. 2.

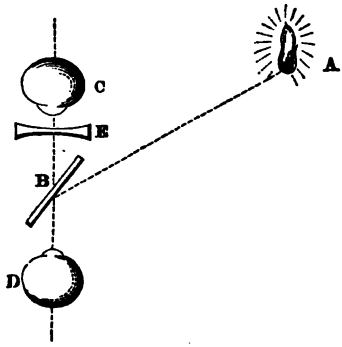

before entering the observer's eye, in order that they may come to a focus on his retina. This is effected by the interposition of the concave lens E between the observer's eye and the reflecting plates.

Modifications and improvements of Helmholtz's principle are to be found in the ophthalmoscopes of Follin and Nachet, of Coccius, of Donders and Epkens, and of Meyerstein.

In the ophthalmoscopes just referred to, the reflection is effected by plane surfaces, on which, however, except in Helmholtz's, the light is condensed by a convex lens. In the ophthalmoscopes now to be noticed, the reflection of the light is effected by a concave mirror, whereby its concentration is at the same time secured. The annexed is a diagram of Ruete's ophthalmoscope. The rays

Fig. 3.

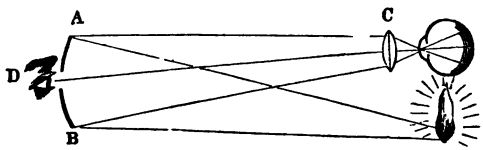

from the flame reflected by the concave mirror A B (of 10 inches focus) fall in a state of convergence on a convex lens C, in front of the observed eye. By this the rays are so much more converged, that, by the additional refraction they undergo on entering the eye, they quickly come to a focus, cross and fall in a state of

great dissipation on the retina, so that this is extensively illuminated. The observer's eye D looks through a hole in the middle of the convex mirror.

The ophthalmoscope of Ulrich is constructed on a similar plan, but is more compactly arranged.

Anagnostakis's ophthalmoscope is merely the concave mirror (four and a half inches focus).

Jaeger's ophthalmoscope, which appears to be very compact and convenient, may be adjusted with either a plain or a concave reflector on Helmholtz's or Ruete's principle.

The use of the ophthalmoscope is necessarily limited by the capacity of the eye to bear the light.

For the examination of the eyes in children, especially when affected with intolerance of light and blepharospasmus, considerable management is required, and even some degree of gentle force.

The surgeon is to seat himself on a chair, with a towel folded longways, laid across his knees. On another chair, on the surgeon's left hand, and a little in front of him, the nurse, with the child, sits in such a way that when she lays the child across her lap, its head may be received on the towel, and between the knees of the surgeon, and thus held steadily. The nurse now confines the arms and hands of the child, whilst the surgeon, having dried the eyelids with a soft linen cloth, proceeds to separate them by applying the point of the forefinger of one hand to the border of the upper eyelid, and the point of the thumb of the other hand to the border of the lower, and then sliding them against the eyeball, but without pressing on it, towards their respective orbital edges. This mode of proceeding obviates the eversion of the eyelids, which is so apt to take place under the circumstances. The eyelids being thus opened, they are readily kept so during the examination, by the command which the points of the finger and thumb, resting against the edges of the orbit, have of their borders.

By this means the whole front of the eyeball is exposed, but it often happens that, to avoid the light, the eye is spasmodically turned up, so that the cornea is in a great measure concealed. By waiting a few seconds, however, enough of it will in general come into view to enable the surgeon to judge of the state in which the eye is. Having completed this part of the exploration, there is not much difficulty in so everting the eyelids, as to ascertain the state of the palpebral conjunctiva. [The eyes of an infant may be most readily examined while the child is asleep. Time enough is generally afforded for a good view of the cornea and conjunctiva before the little creature is alarmed.]

State of the white of the eye—ocular conjunctiva.—The ocular conjunctiva is connected to the sclerotica underneath by cellular

tissue loose enough to allow the former to slide somewhat upon the latter. At the margin of the cornea the cellulo-vascular and nervous basis of the sclerotic conjunctiva stops—what of the conjunctiva extends over the cornea being reduced to the epithelium. This epithelium, however, forms a thicker layer than on the sclerotic conjunctiva. It is, of course, intimately adherent to the proper substance of the cornea.

The bloodvessels of the ocular conjunctiva ramify in a direction from the circumference of the eyeball towards the cornea, and form a vascular circle or wreath around it, but send no vessels in the healthy state into it. Except the ramifications derived from the seven recto-muscular vessels, which are often enlarged and tortuous, the vessels of the ocular conjunctiva can be seen only in the inflamed state of the membrane.

The presence or absence of redness is a point which should be first noted in exploring the state of the ocular conjunctiva. If there is redness, it is easy to determine whether it is the redness of ecchymosis or the redness of inflammatory congestion. The redness of ecchymosis is dark and occurs in patches, abruptly defined, without any appearance of vascular ramifications; whilst the redness of inflammatory congestion presents contrary characters, as will be detailed in their proper places. The ocular conjunctiva may be the seat of pustules, or of growths of various kinds, such as pterygium, pinguecula, warts, fungus, trichosis, and the like. It may be found stained from the long-continued use of nitrate of silver drops, &c.

Injuries of the conjunctiva, whether mechanical or chemical, force themselves on the attention; as also, in general, the presence of foreign bodies in the oculo-palpebral space.

The cellular tissue between the conjunctiva and sclerotica is sometimes the seat of extravasations of blood, *subconjunctival ecchymosis*, sometimes the seat of an accumulation of serous fluid, as in the œdema attending erysipelatous ophthalmia. It is sometimes the seat of a more serious form of œdema, that known by the name of *chemosis*, and common in the purulent inflammations of the conjunctiva. It may also be the seat of emphysema, and is occasionally so of phlegmon.

State of the white of the eye—sclerotica, including the tunica tendinea, or expansion of the tendons of the recti muscles.—In the natural state the sclerotica, including the tunica tendinea, is white and glistening, like other fibrous membranes. The peculiar appearance of the white of the eye is owing to its shining through the semi-transparent conjunctiva. The bluish tinge of the white of the eye in childhood is owing to the thinness of the sclerotica at that time of life, allowing the dark choroid to shine through.

In the healthy state, the sclerotica is even more bloodless than the conjunctiva. The bloodvessels seen in it in certain inflammations are very minute, and converge in straight lines towards the margin of the cornea. Opposite the insertion of the ciliary ligament, some of these vessels pierce the sclerotica to gain the interior of the eye, where they join the vessels of the iris; whilst others anastomose with the circumcorneal vessels of the conjunctiva.

If the white of the eye is red from inflammation, the seat of the vascularity, whether in the conjunctiva or sclerotica, becomes a question. In conjunctival inflammation, the vessels of the sclerotic conjunctiva are large, somewhat tortuous, and arranged in a reticular manner; the color is scarlet, or brick red, and it may be deeper towards the orbit, but more or less shaded off towards the cornea. In sclerotic injection, the redness is in the form of a pink or lake-colored zone, encircling the cornea; the injected vessels being very minute, and disposed in straight radiating lines, as if from its margin, where the tint is deeper, whilst it is shaded off, and disappears towards the orbit, the converse of what occurs in the injection attending conjunctival inflammation. The seat of the injected vessels, whether in the sclerotic conjunctiva, or in or on the sclerotica itself, is easily proved, supposing any doubt exist, by making the conjunctiva slide on the sclerotica, when the ves-

Fig. 4.

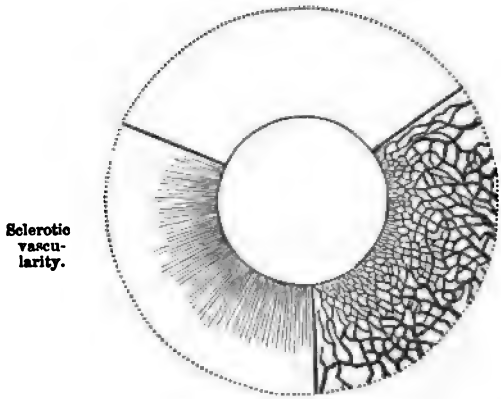

sels, if seated in the conjunctiva, will be observed to move along with it, whereas, if seated in the sclerotica, or closely applied to its surface, they will remain stationary. When both conjunctiva

and sclerotica are injected at the same time, the pink hair-like vessels of the sclerotica are seen stationary through the larger meshes of the sliding conjunctiva. But when the conjunctiva is very much injected, the state of the sclerotica cannot be seen.

Growths and tumors on the white of the eye are to be examined as to whether they have their seat in the conjunctiva only as in *pterygium*—or are imbedded in the subconjunctival cellular tissue, as in *hydatid cysts*,—or have their roots in the sclerotica, as in *trichosis bulbi*. The sclerotica may be found in some part unnaturally prominent and bluish-black—*sclerotic staphyloma*.

State of the cornea.—The prominence and breadth of the cornea, the state of its margin, its connection with the sclerotica, and its transparency and non-vascularity in the mature and healthy state, as also its relations to the iris, and its composition of three principal layers of different tissue, viz., the proper substance, forming its principal thickness; the thick epithelium, or conjunctival layer on its anterior surface; and the membranes of Descemet on its posterior surface, are circumstances to be had in remembrance in examining whether it be the seat of disease.

In order to ascertain the prominence of the cornea, a profile examination of it should always be made. The cornea may be found unnaturally prominent; the prominence may be spherical, as in dropsy of the aqueous chambers after *corneitis*, or conical as in *conical cornea*. Besides these unnatural states of prominence, in which the transparency of the cornea is usually still more or less retained, there is the opaque prominence of staphyloma, which may be either partial or complete. The cornea may be found unnaturally flat. By a profile examination, also, it will be seen in any doubtful case whether an opacity is seated in the cornea, or not. Facets and small ulcers of the cornea will also be detected.

The usual diameter of the cornea is 9-20ths of an inch transversely, somewhat less vertically, the outline of the cornea not being quite circular, but rather oval, and this in the literal sense; its small end being that next the temple. Any morbid increase or diminution of diameter which the cornea may present, is usually an accompaniment of increase or diminution in the size of the eyeball generally.

State of margin of the cornea.—Externally the sclerotica overlaps or encroaches more or less on the edge of the cornea. In certain constitutions, and especially in old persons, the overlapping part of the sclerotica is thicker and more opaque than usual—perhaps also encroaching more extensively on the cornea. The conjunctiva covering the overlapping sclerotica, especially when the latter is to any considerable extent, is like the sclerotic conjunctiva generally, composed of both chorion and epithelium; and although

it adheres to the subjacent overlapping part of the sclerotica very closely by cellular tissue, it by no means presents the same intimate union with the subjacent structure which the extension of conjunctival epithelium over the transparent cornea does. The conjunctiva covering the overlapping part of the sclerotica has a vascular connection with the latter, no otherwise than by the anastomoses of the proper vessels of each—a vascular connection, which indeed subsists between the sclerotica and conjunctiva elsewhere. The disposition just described is connected with a point in the pathology of the eye, viz., the bluish-white ring which is observed to encircle the cornea more or less completely in certain internal inflammations of the eye, and so frequently in what is called arthritic iritis, that it has been considered a diagnostic of it, but certainly without just grounds.

In reference to the cause of the appearance, it is to be remembered that the insertion of the ciliary ligament is at some little distance from the apparent margin of the cornea; that the vessels which form the red zone of the sclerotica in the internal inflammations of the eye, and in inflammation of the proper substance of the cornea, are vessels which send branches inwards to the iris, opposite the ciliary ligament, branches outwards to anastomose with those of the conjunctiva, and, lastly, branches which, following the original direction, go to be continued into those newly developed in the proper substance of the cornea. These vessels are not apparent in the healthy state, and one set of them only may become apparent in inflammation. Thus, in inflammation of the iris, they will be apparent only as far as opposite the insertion of the ciliary ligament. Between this and the clear part of the cornea, is the opaque overlapping part of the sclerotica, which, of course, not being in the way of the progress of the vessels towards the inflamed part, remains white as usual; and the cornea not being affected, there are no vessels developed in its proper substance. Hence the overlapping part of the sclerotica is seen in contrast between the abruptly terminating red sclerotic zone, on the one hand, and the transparent cornea (appearing dark on account of the dark structure behind it), on the other, and forms the bluish-white ring.

From this explanation, the bluish-white ring round the cornea ought to exist more or less in all internal inflammations of the eye, unless obscured by vascularity of the conjunctiva in inflammation of the cornea. So it does; but in persons of otherwise sound constitution, and not of advanced age, the overlapping sclerotica is so transparent, and sometimes also narrow, that it is not strongly contrasted by the transparent cornea. It is otherwise, however, in certain persons, especially such as are advanced in life, in whom the encroachment of the sclerotica and fully developed conjunctiva

on the cornea exists to a great degree, and in a very opaque state; the bluish-white ring then appears in the exaggerated distinctness which has commonly attracted the notice of surgeons.

The condition of the eye necessary for the *distinct* appearance of the bluish-white ring round the cornea, occurring principally in old persons of bad constitution, and these being the very persons in whom an internal inflammation of the eye very often presents what is called the arthritic character, are circumstances which readily explain the error of supposing the bluish-white ring round the cornea diagnostical of arthritic iritis.

In degeneration of the structure of the cornea, the limit between its margin and the sclerotica may be quite obliterated.

Arcus Senilis (*Gerontoxon*), an annular opacity of the cornea within its circumference, which occurs in advanced periods of life, though it is sometimes observed below middle age, must not be confounded with the bluish-white ring round the extreme margin of the cornea, just described.

The opacity is about the twentieth or thirtieth of an inch broad, and has an equal breadth of nearly clear cornea intervening between it and the circumference of the cornea.

Arcus senilis appears first at the upper and lower parts of the cornea, and by and by extends all round, though this does not always happen.

It is never so extensive as to obstruct vision.

As shown by Mr. Canton, the opacity depends on a deposit of granular fat in the interstices between the corneal fibres.

The changes in the transparency which the cornea may present, are very various in seat, degree, extent, and nature. As regards seat, they are distinguished according to the different layers of the cornea which they implicate. But as regards nature especially, they are to be distinguished into those in which opacity is for the time merely a secondary consideration in the case, viz., phlyctenulæ, pustules, abscesses, and ulcers, which are concomitants of inflammation, and those in which the opacity, whether removable or not, is now the principal defect, viz., opacities properly so called.

A foreign body adhering to the cornea may simulate an opacity.

Minute opacities of the cornea, otherwise previously not very evident, are brought into view when the pupil is dilated, being rendered distinct by contrast with the black background formed by the pupil.

When in its mature state, vessels are observed in the cornea, they are new formations developed from the lymph exuded into its substance, from the vessels, in a state of inflammatory congestion, of the adjoining conjunctival or sclerotic circumcorneal zone. New vessels may be observed:—1, between the epithelium and proper

substance; 2, in the proper substance; 3, between the proper substance and membrane of Descemet—these being the situations where lymph is exuded in inflammation.

Foreign bodies getting into the eye, especially when projected with force, may adhere to or become imbedded in the cornea. The cornea is subject to be variously injured by mechanical or chemical agents. Certain chemical agents, such as mineral acids and lime, have the effect of rendering the epithelium of the cornea, in common with that of the conjunctiva, white and opaque, and causing it to become detached, and to peel off from the proper substance of the membrane.

The relations between the iris and cornea should not be passed unnoticed in reviewing the state of the cornea. When the cornea is penetrated by ulcer or wound, the aqueous humor escapes, and the iris is apt to be prolapsed. Of this prolapsus iridis there may be different degrees, according to the extent of destruction of the cornea; and as effects of different degrees of proper prolapsus, there may be found *synechia anterior, partial staphyloma, total staphyloma.*

The cornea may be the seat of growths and tumors.

State of the anterior chamber, and aqueous humor.—The size and form of the anterior chamber are determined by the diameter and prominence of the cornea, on the one hand, and the position of the iris on the other—whether the latter inclines forwards to, or backwards from, the cornea—circumstances to be determined by examining the eye from the side (p. 57).

The state of the aqueous humor is next to be attended to—whether it is of natural transparency, or whether it be mixed with any foreign matters, in the form of lymph, pus, or blood.

State of the iris and pupil.—The color, striated aspect, and position of the iris, and the state of the pupillary margin, are the points first to be noted; then the form, size, and especially the motions of the pupil.

When the iris is inflamed, its surface is dim-looking, and changed in color—if blue to green;—if blue-gray to green-gray;—if green to yellow-green;—if dark brown to reddish-brown;—if bright brown to yellow-brown. Its pupillary circle is often distinctly reddish at first; but when lymph has been exuded into its substance, as in syphilitic iritis, the pupillary circle presents a tawny color.

Change of the color of the iris may also follow an injury of the eye; but it is sometimes met with in cases in which it is alleged there has been no preceding inflammation, or any other apparent cause. In the cases referred to, however, the change of color is attended with some impairment of the sensibility of the retina, or with cataract, indicating that there is something wrong about the nutrition of the eye—probably slow inflammation.

Sometimes dark spots are observed on the iris, looking as if its proper substance were at the place gone, and the uvea appearing, or even protruding through. Somewhat similar spots may be met with in healthy eyes; but the spots here referred to are met with, and sometimes very large, after long-continued unhealthy inflammation of the iris, syphilitic, arthritic, or cachectic. In such cases, the pupillary margin is adherent to the lens, and the middle of the iris projects towards the cornea. The proper substance of the iris, which remains evident, is much changed in color, and presents a peculiar fibrous appearance. This change in the structure of the iris is called *iridoncosis* or *staphyloma uveæ*, from its having been supposed to be a protrusion of the uvea through the proper substance of the iris.

In its natural state, the iris is plane, neither inclining back towards the lens, nor forwards towards the cornea. Sometimes it is met with, in consequence of different morbid states of the eye, inclined towards the cornea. A deceptive appearance of this often occurs, if the eye be viewed from the front only; but all doubt is avoided by looking at it in profile. If the iris still retains its natural planeness, the pupil will be seen nearer the margin of the iris which is next the observer, thus :[1]—Fig. 5.

Fig. 5.

Fig. 6.

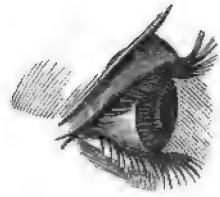

Whereas, if the iris be inclined towards the cornea, the pupil will be seen towards the opposite margin, thus :'—Fig. 6.

Sometimes the iris is inclined back from the cornea, being concave forwards, instead, as in the preceding case, convex. Sometimes, and especially in the cases just mentioned, the iris is seen to be tremulous—to shake on every motion of the eye, which indicates a dissolved state of the vitreous humor.

Besides other changes in the pupillary margin, such as the tawny color in syphilitic iritis, thickening, a fringed appearance, &c., there may be, adhesion of it to the capsule of the lens (*syne-*

[1] It is curious to see how very generally artists, in representing the eye in profile, have committed the error of drawing the pupil as it appears only when the iris is unnaturally inclined towards the cornea. Another common mistake in profiles of the eye is the monstrous size of the palpebral fissure.

chia posterior), producing distortion, contraction, and diminution, in the mobility of the pupil. Analogous changes in the state of the pupil may be produced by other causes, but that they are owing to morbid adhesions will, in general, be observed, on careful examination, and very certainly if belladonna be applied; for by this the free parts of the margin of the pupil will be dilated, and the adhesions rendered very evident, whilst the distortion of the pupil will be much increased.

The iris may be adherent by some part to the cornea, *synechia anterior*, or *partial staphyloma*, according to the extent of the iris and cornea implicated, and the consequent presence or absence of prominence at the place. In this case also the pupil is found distorted, contracted, and more or less confined in its motions. These changes are readily detected, especially by viewing the eye from the side, and by the use of belladonna.

The pupil may be found completely closed, and this state may be either simple or complicated, with morbid adhesions, &c.

Excrescences or tumors sometimes present themselves connected with the iris. The iris may be found detached at some part of its ciliary circumference by the protrusion of cysts or tumors from behind.

The deviations in the form, size, and especially the motions of the pupil, now to be noticed, are such as are independent of morbid adhesions.

Mode of examining the state of the pupil.—The patient is to be seated opposite the light. The surgeon, standing or sitting before him, closes both the patient's eyes by bringing down the upper eyelids. These he rubs over the cornea with his thumbs, and then suddenly opens one eye to the light, and carefully notices how far the pupil was dilated, and how quickly it contracts on exposure to the light. Both eyes are again to be closed and rubbed in the same way, and then the other eye suddenly opened and examined.

If the surgeon were to examine both pupils at the same time, by unshading both eyes simultaneously a mistake might be committed, as the pupil of a blind eye may move in concert with that of the other which is sound. But when the movements of the pupil of the latter are prevented by its being shaded, the pupil of the former will in general be found to be quite unaffected by the light.

It is to be remembered that, in the healthy state, when one eye is covered, the pupil of the opposite one is rather more dilated than when both eyes are exposed to the light.

As in a paralytic limb tickling may excite movements, so in amaurosis, the pupils are sometimes found obedient to the light.

Hippus, or excessive alternate contraction and dilatation of the pupil, is sometimes met with.

The pupil may be found much dilated, and either sluggish in its movements, or altogether immovable; or, it may be contracted, and either sluggish or immovable. In these cases, which are respectively named *mydriasis* (p. 65) and *myosis*, there may be no other disturbance of vision than what the state of the pupil will account for, or there may be amaurotic defect of sight.

Changes in form or position of the pupil, not owing to morbid adhesions, are sometimes met with in syphilitic iritis, arthritic iritis, choroiditis, amaurosis,—a result probably of some affection of the ciliary or iridal nerves.

In consequence of blows, &c., the iris may be detached at some part of its ciliary circumference, the result of which is a false pupil.

Imperfect development of the pupillary circle of the iris sometimes occurs.

Coloboma iridis, which consists of a fissure in the iris extending from the pupil towards the ciliary margin of the iris, is sometimes met with, either as a congenital malformation, or as the result of injury.

Congenital absence of the iris sometimes presents itself. It is readily distinguished by the uniform dark, though not black appearance, behind the cornea; unless cataract has formed, which is in general, sooner or later, the case. If cataract has formed, the opaque lens is seen to its very circumference.

The dark-red reflection from the bottom of the eyes which is observed when the pupils being dilated, the light falls upon them in a certain direction, is particularly well seen in cases of congenital absence of the iris.

Exploration of opaque appearances behind the pupil.—Though the nature and seat of an opaque appearance behind the pupil may be, to a certain extent, determined by the experienced surgeon, without artificial dilatation of the pupil, it is always advisable, especially for the young surgeon, not to pronounce a formal opinion of the exact nature and seat of the opaque appearance behind the pupil, in any case, until after an examination has been made with the pupil dilated.

Artificial dilatation of the pupil.—The dilatation of the pupil by belladonna or hyoscyamus, besides its use in the treatment of the internal ophthalmiæ, is a most valuable means of exploring the state of the pupil and the pupillary margin of the iris, as above shown, and also of exploring the nature and seat of opaque appearances behind the pupil.

The action of belladonna is stronger than that of hyoscyamus. They are usually applied either in the form of extract, reduced to the consistence of honey, which is smeared on the eyebrow and

outside of the eyelids, or in that of a solution of the extract (ext. belladonn. gr. xx. aq. destillat. ℥j, solve et per linteum cola), which is dropped into the eye. They may be also applied in the form of a solution of their active principles, atropine or hyoscyamine, dropped into the eye, as originally recommended by Dr. Reisinger. (Atropiæ sulphat. gr. ij—jv, aq. dest. ℥j; or hyoscyamiæ gr. jv—viij, aq. dest. ℥j.) [The Datura Stramonium or common Jamestown weed, so well known and abundant in America, affords an extract and an active principle which are quite as efficacious as those of the Atropa Belladonna, and may of course be employed in precisely the same manner, whether for anodyne or dilating purposes.]

When the belladonna is applied in the form of soft extract externally, the dilatation of the pupil takes place less quickly than when applied in the form of a solution of atropia dropped into the eye, the effect in this case being produced in ten minutes or a quarter of an hour.

As to the mode of action of belladonna in dilating the pupil, seeing that the state of relaxation of the iris, is that in which the pupil is neither much contracted nor much dilated, and that contraction and dilatation of the pupil are manifestations of an active state, the former of the circular, the latter of the radiating fibres of the iris, it is to be inferred, that the action of belladonna, in producing dilatation of the pupil, consists in calling forth, through the medium of the ganglionic system, the contraction of the radiating fibres. These fibres, it is to be remarked, are different from the circular fibres, immediately under the influence of the ganglionic system.

This action of belladonna in dilating the pupil, is analogous to that which I have found it to possess of determining constriction of the small arteries of the frog's web; their circular fibres being, like the radiating fibres of the iris, under the influence of the ganglionic system.

Catoptrical examination of the crystalline body.—The pupil being dilated by belladonna, and the patient sitting with his back to the window, if a lighted taper be held before the eye, the surgeon will see three reflected images of it in the pupil, one behind the other, if the cornea and crystalline are of their natural transparency. Of these images, the anterior and posterior are erect, the middle one inverted. The anterior is the brightest and most distinct, the posterior the least so. The middle one is the smallest, but it is bright. If the taper be moved, the two erect images follow its motions in the same direction, but the inverted image moves in the opposite direction, though not so quickly, nor through so great a range as the other two. The anterior erect image is re-

flected by the cornea, the posterior by the anterior surface of the lens, and the middle or inverted image by the concave surface of the posterior wall of the capsule.

The posterior erect and the inverted images are not produced, if the anterior part of the crystalline body be opaque, whether the rest be opaque or not, but if it is the centre or the posterior part only which is opaque, the posterior erect image is produced, but not the inverted one. When the opacity is as yet slight, the images may be produced, but will be more or less indistinct. Of course the anterior erect or corneal image is not affected, unless the cornea is diseased.

For determining that the crystalline body still exists, the catoptrical test is of real practical value. In assisting the differential diagnosis of amaurosis, and incipient cataract, and perhaps, in rare cases, of black cataract, its use is also considerable; but is likely to be superseded by the ophthalmoscope. Ordinary cataractous opacity, by the time that operative interference is called for, can always be sufficiently well observed by ordinary direct examination as above indicated, p. 48. By the catoptrical test, it is not to be forgotten, however, that in 1838, Dr. Mackenzie illustrated and confirmed the fact, which he had discovered some ten years before, that the lens is the seat of the peculiar opaque sea-green appearance in glaucoma.

The opaque appearance in glaucoma.—The peculiar sea-green opacity in glaucoma appears deep, and changes its seat according to the direction in which the light is admitted to the eye, being always seen most distinctly on the side opposite the light. When the disease is advanced, the inverted image in the catoptrical examination is indistinct or obliterated.

It has been above stated that for all practical purposes, opacity of the lens can be sufficiently well ascertained by ordinary exploration with the pupil dilated. By means of the ophthalmoscope, adjusted for the purpose, however, otherwise undistinguishable opaque points can be seen. But it is of no advantage to push the diagnosis of opacity of the lens to such a minute degree of accuracy, seeing that we often meet with cataractous opacity, quite evident to ordinary examination, notwithstanding which there is still pretty good sight; whilst, on the other hand, cases occur in which the impairment of sight complained of is not at all to be accounted for by the appreciable opacity of the lens.

Exploration of the state of the posterior segment of the eyeball.—Whilst the morbid states of the anterior segment of the eyeball are sufficiently accessible to objective exploration, those of the posterior segment, comprising the vitreous body, retina, and choroid, could formerly, with some exceptions—(*e. g.* exuded matter in the

vitreous body, scrofulous and encephaloid growths at the bottom of the eye, &c., which give rise to a yellow shining appearance, sometimes traversed by bloodvessels),—be determined only from the attendant subjective phenomena. This defect in our means of diagnosis of the state of the posterior segment of the eyeball, was, however, practically little felt. Having determined that the disease was not seated in the anterior segment, and thus *per exclusionem*, and from the nature of the subjective symptoms (together with the objective symptoms presented by the anterior segment, and by the eye considered as a whole), referred it to some part of the posterior segment, we were in a position to conduct our treatment of the case, not with less efficacy at least than can be done now, when it is possible, in many instances, to discover by means of the ophthalmoscope, opaque spots, shreds, &c., in the vitreous humor, and congestion, with extravasations, exudations, and pigment deposits in or behind the retina.

Vitreous body.—Morbid states discoverable in the vitreous body, are opacities in the form of fixed spots, or of undulating membranous shreds and filaments, of the most different size and form, with sharp or indistinct outline.

Retina and choroid.—There is nothing more easy than to see the vessels of the retina in a cat's eye without an ophthalmoscope. Having previously dilated the pupil by atropia solution, drop some water into the eye while the eyelids are held apart, and cover the cornea with a thin plate of glass. The vessels of the retina can then be seen slightly magnified. It has been proposed to explore the bottom of the human eye in a similar manner, and instruments have been contrived for the purpose, but the ophthalmoscope, as above described, is of more ready and convenient application.

In man, the red color which the bottom of the eye presents, varies in tint; being brighter in fair, more of a yellowish-brown in dark individuals. The retinal vessels are seen branching on the uniform red field formed by the more vascular choroid. At the entrance of the optic nerve, which appears whitish-yellow and well defined, the retinal vessels are seen emerging. The retina in the situation of the yellow spot, is little or not at all vascular, and sometimes presents a greenish-gray aspect. A streak of pigment deposit may be seen at some part or all round the border of the optic papilla.

The principal morbid appearances in the retina which have been observed are congestions, spots of extravasated blood, pigment, deposits, opacities of various aspect, the retina itself bulged forward by fluid accumulated between it and the choroid, and tremulous in the dissolved vitreous body.

A remarkable sparkling appearance produced by cholesterine

crystals is sometimes observed in the interior of the eye, even without the aid of the ophthalmoscope. Dr. Hannover thinks that the cholesterine is always formed in the lens, and becomes free after operation for cataract. He therefore proposes the name *cataracta scintillans* instead of *synchysis scintillans*, commonly given to the morbid state in question from the vitreous humor, in a dissolved state, being supposed to be the original seat of the cholesterine deposit.

Consistence of the eyeball to the touch.—By pressing on the eyeball with the finger through the medium of the tarsal edge of one of the eyelids, the consistence of the eyeball should be ascertained; whether it be normal or of unusual hardness or softness. Hardness of the eyeball indicates too great quantity of the vitreous humor. Softness or flexibility of the cornea or sclerotica, indicates atrophy of the vitreous body. In either case, as also when the eyeball is of natural consistence, there may be dissolution of the hyaloid membranous structure.

SUBJECTIVE EXAMINATION OF THE EYES.

Pain—its seat and character.

Pain in and around the eye, of various kinds and degrees, attends many diseases of the eye, especially the ophthalmiæ. It is, however, not a constant symptom; cases of the most intense inflammation, for example, are met, in which no complaint of pain is made. Speaking generally, however, it may be said that pain, as if a foreign body were in the eye, with heat, itchiness, and smarting of the edges of the eyelids, and sometimes pain across the forehead, indicates conjunctival inflammation. Rheumatic pain around the orbit, or in the temples, occurring in nocturnal paroxysms, points to inflammatory congestion of the sclerotica, as in iritis, &c. Deep-distending pain in the eyeball, with or without circumorbital or temporal pain, marks posterior internal inflammation of the eye.

These pains are to be distinguished from neuralgia of some one of the branches of the ophthalmic division of the fifth nerve. Here there may be symptoms of congestion, but they intermit along with the neuralgic paroxysm.

Impairment or loss of common sensibility.

The common sensibility of the conjunctiva, skin of the eyelids, &c., to the contact of external objects, may be found impaired or lost. Notwithstanding, the patient may have the sensation of creeping or formication, or may actually suffer neuralgic pains (*anæsthesia dolorosa*). When insensible to the touch, the eyes feel cold.

Intolerance of light, or Photophobia.

Intolerance of light, in a greater or less degree, is a very frequent symptom in the ophthalmiæ; but that in which it occurs most intensely is the scrofulous ophthalmia of children. Intolerance of light may also occur in other affections not coming under the head of the ophthalmiæ. The indication of intolerance of light from the general bearing of the patient has been above (p. 38) noticed.

State of Vision.

In our inquiries as to the state of vision, it is necessary to bear in mind that the anomalies complained of may depend—some, on derangement of the dioptric apparatus of the eye; some on loss of correspondence in the direction and movements of the two eyes; and some, on affection of the optic nervous apparatus.

The surgeon should have a series of concave glasses with which to test the sight when complaint is made that objects at some distance cannot be seen distinctly, as in *myopia* or shortsightedness; and a series of convex glasses for the same purpose, when the complaint is that in reading or sewing the sight is indistinct, unless the book or seam be held at arm's length, as in *presbyopia* or farsightedness.

In *amblyopia*, or defective sight from affection of the optic nervous apparatus, although neither distant nor near objects are seen distinctly, the latter may be seen better than the former, because the eye receives a greater number of rays from a near object, so that the impression on the retina is stronger. Such a case, which may be called nervous shortsightedness, must be distinguished from true or optical shortsightedness. In nervous shortsightedness the sight will probably be improved, not by a concave, but by a convex glass.

When a young person cannot see distant objects well, and if on trial it is found that the sight is not assisted by concave glasses, an examination of the form of the cornea, whether it be conical, and of the state of the lens, whether its transparency be impaired, should be instituted.

A not unfrequent defect of sight among young persons, and even children is, that though in commencing to read or sew the sight is quite distinct, the eye becomes fatigued in a few minutes, and everything appears confused (*asthenopia*). In such a case, convex glasses of low power (36 to 48 inches focus, or even lower) will probably enable the person to exercise vision on near objects without fatigue.

In a case of indistinctness of sight, with the pupil greatly dilated, the patient should be requested to look through a small aperture made with a thick pin in a card, or an instrument kept for the

purpose, such as is represented in Figure 7. If objects are then seen distinctly, the case is one of simple *mydriasis*.

Fig. 7.

When objects are seen double (*diplopia*), it is necessary to ascertain whether the two images are seen even with a single eye, or only when both eyes are open. In the former case, the double vision depends on some defect in the dioptric apparatus; in the latter, on misdirection of the two eyes. This misdirection of the two eyes is objectively evident, if owing to want of harmony in the action of any of the recti muscles, but is not so when owing to abnormal action of the oblique muscles. In this case, the misdirection consists in loss of parallelism of the vertical and horizontal diameters of the eyeballs.

When it has been ascertained by objective exploration of the eyes that dimness of sight does not depend on opacity of the cornea or lens, nor, by the tests above described, on defective adjustment, then there is reason to fear an amaurotic affection, depending on disease of the retina, optic nerve, or brain.

Amaurotic defect of sight presents itself in the various degrees and forms of *hemiopy*, *nightblindness*, *amblyopy*, confirmed amaurosis, &c. Whether the cause of amaurosis have its seat in the eyeball or within the cranium then becomes the question. Morbid changes in the retina, it has been above seen, may be observed by means of the ophthalmoscope. If none are thereby discoverable, the disease is probably intra-cranial, in which case there may be other symptoms of affection of the brain.

An appearance of motes or flies floating in the field of vision (*muscæ volitantes*) is owing to the shadows of minute objects on or in the eyes, usually in the vitreous body close in front of the retina, and is to be distinguished from the appearance of flashes and scintillations of light (*photopsy*), which is owing to irritation of some part of the optic nervous apparatus.

That muscæ volitantes are owing to the shadows of minute objects on or in the eyes, is proved by the *entoptical test*, viz., looking through a small aperture at the clear sky, when they appear more distinct, or are brought into view when not before apparent. Muscæ

volitantes are more evident in incipient cataract, on the same principle that they are so on looking through a pinhole.

As along with loss of sensibility of the skin there may be neuralgic pains, so along with amaurotic blindness there may be photopsy.

Section II.—Application of Remedies to the Eyes or their Neighborhood, and Performance of Minor Operations on them.

Cold Applications.

Cold lotions.—Cold spring water is the best cold lotion. It is applied by means of compresses of old linen or lint, which should be broad enough to extend over the neighboring parts as well as over the eye, but not so heavy as to press unpleasantly. When once commenced, the application of the cold lotion requires to be assiduously kept up as long as is necessary, one compress as soon as it becomes warm, being replaced by another just taken out of the water.

Cold douche bath.—This consists in a fine stream of cold spring water allowed to play on the closed eye and neighboring parts. The application may be continued for about a quarter of an hour at a time. There are particular douche apparatuses. A simple form of one may be readily constructed with a glass tube of the thickness of a barometer tube, and from three to three and a half feet long, bent like a syphon six inches from one end, whilst at the other it is drawn out small, and also bent, but only for about two inches; the short limb of the syphon being immersed in a vessel of water placed at a convenient height, the air is sucked out at the small end, when a fine stream of water will issue from it.

Dry cold.—In the weak and rheumy eyes of old persons, and in a similar state remaining after an attack of ophthalmia, it is often agreeable, and indeed productive of great relief, occasionally to draw some cold body across the eyelids. For this purpose, a long slender bottle, with a smooth round bottom, filled with ice, has been recommended.

Warm Applications.

Warm cataplasms and fomentations.—As applications to the eye, fomentations are much more convenient and elegant than poultices. Warm water simply may be used for the purpose, or chamomile decoction, poppy decoction, and the like. The application is made by means of compresses as just described for cold lotions. The application requires only to be made occasionally,

and that merely for a period of from five minutes to a quarter of an hour at a time. Warm cataplasms and fomentations should never be allowed to become cold on the eyes. After their removal, the eyes are to be gently dried with a soft linen cloth, and care taken that they be not exposed to a draught of air.

Watery vapors.—In order to receive watery vapors on the eyes, the patient holds his face over a vessel containing hot water; a cloth being thrown over all. When it is wished to have the steam play more directly on the eye, a funnel is inverted over the vessel, and the tube directed towards the eye at a proper distance. After the application, the face and eyelids to be well dried, and exposure to any draught of air carefully avoided.

Medicated Vapors.

Medicated watery vapors.—In some cases, the hot water is mixed with some aromatic or narcotic substance, such as tincture of opium, tincture of camphor, compound tincture of camphor, tincture of hyoscyamus, or of belladonna, in the proportion of a teaspoonful or two to the cupful of hot water about to be used for steaming.

Dry warmth and vapors of aromatic or narcotic substances.—Bags of aromatic or narcotic herbs hung over the eyes are employed partly to keep up dry warmth, and partly for the sake of the exhalations they give out. The bags are made of coarse lawn or muslin, washed and rubbed soft. Being lightly filled, the bag is sewed close, and then quilted at different places, so as to keep the materials equally spread out, and to prevent them from sinking down. The bags ought to be made as light as possible, not more than of the thickness of a finger, and about the size of a playing-card. They are fixed to a band passed round the forehead, so as to hang free; they ought not to be bound over the eye. The bags are warmed before being applied. The materials used for filling the bags are aromatic species (chamomile flowers, sage, rosemary, thyme, &c.), mixed or not with shavings of camphor. The species are reduced to a coarse powder, from which all dust is to be separated by a sieve. To fill a bag of the size above indicated one and a half to three drachms of herbs, flowers, &c., will be required. When *camphor* is the only active substance employed, cotton wool, impregnated with it, is to be used for filling the bag. The impregnation is readily effected by soaking the wool in strong spirit of camphor, and then allowing it to dry quickly; when dry, the wool is teased out.

Herb bags are now not much used.

Stimulating vapors.—The vapor of the weaker volatile fluids is applied by spreading the fluid out on a warm surface, and allowing it to evaporate near the eyes. Thus, having poured a few drops of

the fluid into one hand, and spread it out on the palms of both, by rubbing them quickly together, the hands are to be held one before each eye more or less close according to the strength of the material and degree of action desired.

Collyria, &c.

The word Collyrium, as at present understood, means an eye-water, but formerly it was applied to any medicine for the eyes, whatever its form. Recurring partially to the original and wider acceptation, it is purposed under this head to treat not only of eye-waters, but also of eye-salves and eye-powders. The skin of the eyelids, and the conjunctival surface, are the parts of the eye which, under ordinary circumstances, are most open to the contact of remedies; the derivative lacrymal passages, though also directly, are less easily accessible. Of the other parts of the eye the proper substance of the cornea, when laid bare by ulceration, and the iris when it is prolapsed in consequence of a wound or penetrating ulcer of the cornea, are those which may become the subject of the direct action of medicinal substances. The lacrymal gland and Meibomian follicles may be influenced by the action of collyria on their excretory orifices. Of the internal tunics, the iris is acted on by the external application of belladonna, &c. The others are also affected by applications to the conjunctiva, though in general, when these are irritating, rather injuriously than beneficially.

Eye-waters and drops are solutions of astringent, stimulant, or narcotic substances, or of all combined. Their state of concentration regulates the mode of application, hence the division into eye-waters properly so called, and drops for the eyes.

Eye-waters, properly so called, are the weaker solutions, and are used to bathe the eye with occasionally in the course of the day. The fluid is to be put into a cup in sufficient quantity and made tepid. The patient, holding his head over the vessel, is to lave his eye with the water by means of a piece of lint or soft linen rag; and after this has been done for a few minutes, some of the fluid may be dropped fairly into the eye by an assistant squeezing the soaked rag over it, while the patient lies on his back, and endeavors to hold his eyelids apart. After this, the eye may be laved again for a minute or so, and then carefully dried with a soft linen cloth. An eye-glass is not to be recommended.

A principal object in the process above described is to remove any discharge from the eye. In the blennorrhœal ophthalmiæ, when the eyelids are enormously swollen and cannot be opened, it may be necessary to inject the eye-water between the eyelids, after they have been cleansed as much as possible by means of the bathing simply. In using the syringe, however, care must be taken not to

injure the patient's eye by pressure or the like, and on the other hand, the operator should guard his own eyes from receiving any spirt of matter.

In order to act on the inner surface of the lacrymal passages, the simplest way of applying the eye-water is to drop it into the inner corner of the eye, and leave it there a short time till some is taken up by the puncta. It is sometimes also injected directly through the puncta and canalicules by means of Anel's syringe. Injections are occasionally thrown into the lacrymal passages from the opening of the nasal duct into the nose; but when an external opening into the lacrymal sac exists, whether it has been made by operation or the bursting of an abscess, we have the readiest access to the mucous surface of the lacrymal passages.

Examples of eye-waters.

℞—Belladonæ extracti, ʒss.
Aquæ puræ, ℥viij.
Solve et per linteum cola.
Sig. Sedative eye-water, to be used tepid.

℞—Aluminis, gr. xvj.
Aquæ rosæ, ℥viij.
Solve. Ft. aqua ophthalmica.

[℞—Alumin. ℈j.
Acid. tannic, ℈j.
Aq. ros. f℥viij.
Solve. Ft. aq. ophth.]

℞—Sulphatis zinci, gr. xvj.
Aquæ rosæ, ℥viij.
Acid. sulph. dilut. gtt. xvj.
F. Solutio pro aqua ophthalmica.

[℞—Zinc. sulph. ʒj.
Sod. hydrochlor. ʒj.
Aq. ros. f℥viij.
F. Sol. pro aq. ophth.]

℞—Hydrargyri bichloridi, gr. j.
Ammoniæ hydrochlorat. gr. viij.
Aq. ros. ℥viij.
Solve, &c.

℞—Lapidis divini,[1] gr. xvj.
Aquæ destillat. ℥j.
Solve et cola,
Colaturæ adde aquæ rosarum, ℥vij.
Misce, &c.
Sig. Eye-water.

[1] ℞—Æruginis,
Nitratis potassæ,
Aluminis ää partes xvj.
Terantur simul et liquefiant in vase vitreo in balneo arenæ. Liquefactis adde camphoræ tritæ partem j: Misce.
Massa refrigerata servetur sub nomine LAPIDIS DIVINI.

N.B. To any of the last four solutions, a drachm of vinum opii [or of laudanum] may be added. The following are the directions for use:—To half a teacupful, add as much hot water as will make the whole lukewarm. With the quantity thus prepared, the eyes are to be bathed as directed, p. 68.

Drops.—These may be applied by means of a quill or glass tube, but a large camel's hair pencil will be found the most convenient instrument. It is to be remembered, however, that to avoid accidents, each patient should have a separate pencil, which ought to be well washed every time it is used. The lower eyelid being slightly everted, its inner surface is to be touched with the loaded pencil, when the fluid will be immediately drawn off and diffused over the lower part of the conjunctiva. Pains must also be taken to allow the drop to make its way underneath the upper eyelid by drawing this from contact with the eyeball, and then moving it slightly up and down. It is frequently necessary to evert the upper eyelid, and to pencil its conjunctival surface directly.

Applied in the ordinary way, salves, eye-waters, and drops, scarcely ever come into contact with the conjunctiva of the upper eyelid and eyeball[1] in any degree of concentration, and too often what gets there acts rather as an irritant than otherwise. I consider it of great importance to insure the access of an application to the upper parts of the conjunctiva, because I have seen cases treated unsuccessfully, or rather irritated for a long time by applications, which, when properly introduced, did not fail of a speedy beneficial operation.

In order to apply drops to the eye of a child with the least possible trouble, the surgeon is to seat himself on a chair, with a towel folded longways, laid across his knees. On another chair, on the surgeon's left hand, and a little in front of him, the nurse with the child sits in such a way, that when she lays the child across her lap its head may be received on the towel, and between the knees of the surgeon, and thus held steadily. The nurse confining the hands and arms of the child, the surgeon easily draws down the lower eyelid, and drops in the fluid; he then draws the upper eyelid up a little, and also from contact with the eyeball, in order to allow the drop to get underneath. The eyelids are then alternately to be drawn from each other, and made to approach so as to favor the spreading of the fluid over the whole conjunctival surface.

[1] In illustration of this, it may be mentioned, that in most or all the cases in which, from the abuse of the nitrate of silver drops, the conjunctiva has become dyed of a dark olive or actually black, it is the lower part of this membrane which is so affected. In such cases, besides being discolored, the conjunctiva is often found much shrunk and in a state of incurable chronic inflammation. In extreme opposition to the notion that, drop in the nitrate of silver solution long enough and the ophthalmia will be cured, which leads to such deplorable results, is the disposition to decry the employment of the remedy altogether. The nitrate of silver solution is, however, a valuable application, if properly used.

Examples of eye-drops.

Vinum opii, pure, or diluted with one or two waters, is often used for dropping into the eye.

℞—Nitratis argenti, gr. iv.—x.
Aquæ destillatæ, ℥j.
Solve.

[℞—Zinc. sulph. gr. x.
Sod. hydrochlor. gr. x.
Aq. ros. f℥j. M.]

℞—Hydrargyri bichloridi, gr. ss.
Aquæ destillatæ, ℥vij.
Solve et cola. Colaturæ adde vini opii, ℥j.
Misce.

[℞—Tannin, ℈j.
Aq. ros. f℥j. M.]

℞—Lapidis divini, gr. v—x.
Aquæ destillatæ, ℥vij.
Solve et cola. Colaturæ adde vini opii, ℥j.
Misce.

℞—Extract. belladonnæ, gr. xx—xxx.
Aquæ destillatæ, ℥j.
Solve et per linteum cola.

℞—Atropiæ sulphat. gr. ij—iv.
Aquæ destillatæ, ℥j.
F. Solutio.

Eye-salves.—Salves are applied to the borders of the eyelids, or to the whole conjunctival surface. In the former case only should the patient or his attendants be intrusted with the application. In the latter case, more discrimination, as well as tact, being required, the surgeon should apply the salve himself.

Before applying a salve to the edges of the eyelids, all incrustations of matter about the roots of the eyelashes must be removed. This is done by first rubbing the part with fresh butter or lard, and after a while bathing it with tepid water; the incrusting matter is thus softened, and may readily be separated with the finger-nail or head of a pin. All loose eyelashes should at the same time be plucked out.

The anointing of the edges of the eyelids may be performed by means of a hair pencil, or simply with the point of the finger. The eyelid being held slightly everted, the salve is applied along its border to the mouths of the Meibomian follicles, then smeared outside the insertion of the eyelashes, and afterwards carefully rubbed in at their roots, the eyelids being at the time kept gently closed.

When a salve is to be applied to the whole surface of the conjunctiva, a piece of the size of a split pea is to be taken up on the point of a probe, or on the point of the nail of the little finger, and insinuated under the upper eyelid, while this is drawn forward from contact with the eyeball. When the salve is fairly in the eye, the upper eyelid is to be gently drawn down, and rubbed over the eyeball with the finger for a minute or so, in order to diffuse the salve, now melted by the heat of the eye, between the eyelids and eyeball, and consequently all over the conjunctiva.

If the palpebral conjunctiva be the part on which the salve is principally to exert its action, the application may be limited to it, in which case the pain is less severe than in the former. Having everted the eyelids, the exposed conjunctival surface is to be rubbed with the salve either by means of a hair pencil or the point of the finger.

Salves are sometimes applied to the lacrymal passages by smearing the styles, catgut-strings, &c., which are introduced into the nasal duct, whether from the nose or through an external opening into the lacrymal sac.

In regard to the application of a strong salve to the eye, it is necessary here to give a caution, viz., not to insert it in a lump within the lower eyelid and leave it there. I have seen the conjunctiva of the inferior palpebral sinus in a sloughy state from a lump of nitrate of silver ointment having been put in, and no care taken to diffuse it by rubbing the eyelid over the eyeball. In the case of ointment inserted under the upper eyelid, the natural motions of the part will make up in some degree for the neglect of the surgeon.

Examples of eye-salves.

℞—Oxidi hydrarg. rubri bene lævigat. gr. iii—vi—xv.
Axungiæ præparat. ʒij.
Misce accuratissime: ft. unguentum ophthalmicum.

The two weaker forms are used for anointing the edges of the eyelids, and may be intrusted to the patient. The strongest form should be applied only by the surgeon himself. Applied to the whole conjunctival surface it is found a very efficient remedy in various inflammations of the conjunctiva, and ulcers, specks, &c., of the cornea. It is less severe in its operation than the nitrate of silver ointment.

The citrine ointment of the pharmacopœias, diluted with three or more parts of lard or oil, is a useful application to the edges of the eyelids.

℞—Argenti nitrat. gr. x.
Aquæ destillat. q. s. ad solvend. nitrat.
Unguent. cetacei, ʒj.
Prius solvatur nitras; dein misceatur accuratissime solutio cum unguento.

This ointment has been used with much success not only in chronic, but also in cutting short acute inflammations of the conjunctiva; but the pain it causes is very severe.

The following is what is known by the name of Janin's ointment for the eyes.

℞—Præcipitati alb. gr. xv.
Tutiæ præparat.
Boli armen. ppt. āā ʒss.
Adipis suilli. ʒi—ʒij.
M. exactissime: ft. ungt. ophthalmicum.

It is of great consequence that the eye-salves should contain no gritty particles; the powders entering into their composition, therefore, should first be reduced by trituration to as impalpable a state as possible, and then carefully levigated with a little water or oil, previously to being mixed with the excipient. Substances soluble in a small quantity of fluid, such as the nitrate of silver and sulphates of zinc and copper may be dissolved. When camphor enters as an ingredient into an eye-salve it should first be dissolved in a fixed oil. The excipient best adapted for eye-salves is prepared lard, simple cerate, or spermaceti ointment.

[Castor oil is an excellent diluent, and when of the best quality, may be used with great advantage by itself as a simple unguent to the margins of the lids.]

Eye-powders, or Dry Collyria.—The application of irritating powders to the eye is much less frequent now than formerly. They were principally used against specks of the cornea. Insufflations of calomel have been strongly recommended in the puro-mucous ophthalmiæ.

The powder, reduced to the greatest impalpability, *pulvis subtillissimus*, is blown into the eye through a quill, or applied by means of a moist hair pencil. [The pencil should be used in all cases.] The surgeon should always perform the operation himself.

Refined sugar or sugar-candy reduced to a very subtle powder has been principally used either alone, or as an excipient and diluent of other substances.

Examples of eye-powders.

℞—Sacchari purif.
Oxidi zinci, āā pp. æq.
Misce, et tere ut fiat pulvis subtilissimus.

℞—Acid. tannic.
Pulv. sacch. alb. āā pp. æq.
Misce, et tere ut ft. pulv. subt.

℞—Oxydi hydrarg. rubri. gr. x.
Sacchari purif. ʒj.
Misce, et tere, &c.

℞—Calomelanos,
Sacchari purif. āā pp. æq.
Misce, et tere, &c.

To this, one-third of a part of powdered opium may be added.

The proportions above given may be varied according to circumstances.

Of late the neutral acetate of lead in fine powder has been much extolled in Belgium, as a remedy in *granular conjunctiva*. The eyelids being everted, and wiped with a bit of lint, this powder is laid on the affected surface by means of a camel-hair pencil or the point of the finger. After remaining a minute or so, it is to be washed off.[1] [The acetate of lead is far better applied in solution.]

Potential cautery.

It is sometimes required to touch fungosities of the conjunctiva, ulcers of the cornea, prolapsed iris, partial staphyloma, &c., with caustic. The caustic usually employed, is the nitrate of silver. In performing the operation, an assistant secures one eyelid, the surgeon the other, and that in a way according to the part which is to be cauterised. The surgeon then proceeds to make the application of the caustic, carefully confining it to the particular spot. [The application can generally be more safely and effectually made with a camel's hair pencil, previously moistened, and saturated with the nitrate by wiping it freely on the stick.] This being done, the part is to be dried by touching it with a bit of lint; some sweet oil is then to be pencilled on it before the eyelids are allowed to close. Cauterisation of the skin of the eyelids, by sulphuric acid, to remedy entropium, by producing contraction of the skin, will be noticed under the head of *Entropium*.

Blue-stone has been very extensively abused in the treatment of granular conjunctiva. In the hope of eventually destroying the so-called "granulations," it has been perseveringly rubbed on the

[1] From acetate of lead applications, an opaque white deposit takes place on the conjunctiva. This bad effect, different from the bad effect arising from the abuse of nitrate of silver, above noticed, may result from a single application. The deposit is extremely apt to fix itself on ulcers of the cornea. [It attacks every abrasion, or the slightest denuded surface.] Hence, when such exist, acetate of lead collyria are especially contraindicated. [Collyria of very dilute acetic acid, will sometimes remove the spots.]

inner surface of the eyelids. The result of this practice too often has been the destruction of the palpebral conjunctiva, as well as the "granulations;" the tarsal cartilage being left covered with nothing but a callous epithelium. In such cases, of which I have seen many, this result of the abuse of blue-stone has been generally found greatest on that part of the palpebral conjunctival surface which projects most when the upper eyelid is everted, betraying a mal-application, as well as an abuse of the escharotic. [The sulphate of copper, although liable to great abuse, is not more so than nitrate of silver or acetate of lead. Like these latter, it is very useful when properly and judiciously applied, while it does not produce the discolorations which may result from either of the others. Nitrate of silver may and does disorganize and irritate as much as any other remedy, when improperly employed, as it too often is by patients and surgeons.]

Abstraction of Blood.

Cupping.—When blood is to be abstracted by cupping, in diseases of the eyes, it is usually on the nape of the neck, or on the temples, that the operation is performed.

Application of leeches to the eyes.—The region corresponding to the margin of the orbit all round, the side of the root of the nose, and the temples, close to the outer angle, are the places where leeches are most advantageously applied in inflammation of the eyes. A leech or two are sometimes applied within the nostrils, and occasionally to the conjunctiva of the sinuses, though the latter is a place of application not much to be recommended—first, because the resulting wounds are elevated, and cause irritation like foreign bodies; and secondly, because scarification is preferable.

Half a dozen is the average number applied around one eye, in a grown-up person. In children, when it is necessary to abstract blood, two or three leeches to the region of the inner corner are sufficient. In very young infants, it is to be remembered, that the after-bleeding from even one leech may prove fatal, if allowed to continue. [As the American leech draws blood in the proportion of about two fluid ounces to the dozen, a larger number must be directed when the native leech is specified. The imported or European leech should never be resorted to for children, on account of the danger of excessive hemorrhage.] Scarification is therefore to be preferred, especially as the affection of the eyes in infants requiring bleeding, is the ophthalmia neonatorum, in which a few scratches on the gorged conjunctiva of the everted lids are sufficient to produce a considerable and beneficial discharge of blood.

When the after-bleeding (which, it is to be remarked, usually

takes place in any quantity from certain of the bites only, and generally more freely on a first than on subsequent application), has been kept up sufficiently long by means of warm fomentations, these are to be laid aside, and the skin carefully dried, when the bleeding will in general cease of itself; if not, pressure is to be made on the bites with the point of the finger, for a short time, or the bites touched with much-diluted nitric acid. (gtt. j—3ij.)

Discoloration of the eyelids from ecchymosis, generally results from the application of leeches, for which the patient should be prepared. From idiosyncrasy, erythema, or erysipelas—with very considerable œdema perhaps—is sometimes the result of the application of leeches to the face. In ordering leeches, therefore, to the face, inquiry should be made if leeches were ever applied before, and if any such tendency to erythema manifested itself. Though alarming to the patient, the erythema and œdema in general soon subside. A saturnine lotion may be used as an application in such a case. Sometimes, especially under the circumstances just mentioned, suppuration of the wounds takes place, and knotty cicatrices are left. [It is much better never to allow leeches to be applied to the eyelids, or the conjunctiva. The temple, near the outer angle of the eye, or in front of the ear, will generally answer equally well, if not actually better. We once saw a fatal attack of erysipelas produced by the application of leeches to the eyelids.]

Scarification of the conjunctiva of the eyelids and sinuses.—The simplest instrument for this purpose is a common lancet, rounded at the point. Scarification is called for when the palpebral conjunctiva, and especially the conjunctiva of the sinuses, is gorged with blood, and sarcomatous-looking. In such a state, superficial scratches are quite sufficient to give issue to a considerable quantity of blood. Deep scarifications ought not to be made. When free bleeding does not take place from superficial scratches, the case is not one for scarification at all. As the blood flows, it is to be taken up with a bit of dry lint held to the edge of the eyelid, but not allowed to touch the scarified part, as this is apt to cause the bleeding to stop. Bathing with warm water also stops the bleeding. The flow of blood is best promoted by every now and then allowing the eyelid to become less everted, and then again fully renewing the eversion. When, however, the blood begins to coagulate on the scratches, and its further flow ceases, the flakes of coagulated blood may be removed with the lint, and a few more scratches made with the lancet. When the conjunctiva of both eyelids is to be scarified, it is best to begin with the upper.

Scarification of the conjunctiva of the upper eyelid.—The upper eyelid is not so easily everted as the lower; but in those cases in which scarification is most required, the eversion is generally rea-

dily enough effected, on account of the swollen state of the conjunctiva. The upper eyelid being everted, as already described (p. 43), it is to be kept so by means of the eyelashes pressed against the upper margin of the orbit, whilst the scarifications are made, and as long as the blood flows. When the conjunctiva of the palpebral sinus is much congested and sarcomatous, as in ophthalmia neonatorum, it protrudes greatly, and should be freely scarified. In some cases of chronic inflammation, the conjunctiva of the upper eyelid is red and spongy-looking towards the angles, but not much affected in the middle. In these cases, the scarification is to be confined to a slight scratch or two on the red and spongy places.

Scarification of the conjunctiva of the lower eyelid.—In order to this, the lower eyelid is to be everted, by applying the points of the fore and middle fingers of the left hand on the middle of the eyelid, and in such a way that the extreme points correspond to the insertion of the eyelashes. The skin of the eyelid and neighboring part of the cheek is now to be drawn down a little; and when this is effected, the extreme points of the fingers are to be directed backwards, gently pushing them a little between the lower margin of the orbit and the eyeball. By this means the eyelid is fully everted, and the conjunctiva of the sinus exposed and rendered prominent, when the scarifications are to be made.

In granulated conjunctiva, a mode of scarification, which I have employed with advantage, consists in making a small crucial incision through each granulation, or when they are small and closely compacted, by making a number of cross hatches.

It has been objected to scarification, that the traumatic irritation which is occasioned does more harm than all the good effected by the loss of blood. But this is certainly not a correct view of the matter. In the proper cases, mere superficial scratches are sufficient to give issue to a considerable quantity of blood; thereby relieving the congestion of the conjunctiva, and thus preparing it to be more beneficially acted on by the applications made to it immediately after. [We are satisfied, from observation of its mischievous results in a large number of old cases, that decided scarification is rarely beneficial to granular lids, and very often permanently injurious. This we understand to be the established experience of our colleagues at Wills' Hospital. Superficial scratching to relieve temporary congestion is a different thing.]

Division of enlarged vessels in the sclerotic conjunctiva.—This may be readily effected by means of a small sickle-shaped needle introduced through the conjunctiva under the vessel, and made to cut itself out, by which manœuvre the vessel is divided. But it is usually found better to excise a portion of the vessel in order to obviate the reunion of the divided ends, and the refilling of the

vessel, which readily take place. To effect this, the eyelids require to be held apart by an assistant, as both hands of the surgeon are necessarily engaged, the one in taking up with a hooked forceps a fold of the conjunctiva, containing the portion of vessel to be excised,—the other in snipping it and a piece of the vessel away with a pair of curved scissors. The scissors should be held with the convexity towards the eye, and ready for use, before the fold is taken hold of with the forceps. Though the fold of conjunctiva is snipped away, the vessel may not be cut, but merely exposed; in this case the exposed part of the vessel is to be seized directly with the forceps and cut away. Division of enlarged vessels is, however, a practice not much to be recommended.

Incision of chemosed conjunctiva.—In chemosis, the elevated fold of conjunctiva all round the cornea requires to be incised, partly for the sake of the bleeding thereby occasioned, and partly to relieve the tension of the conjunctiva, and the pressure it exerts on the cornea. The best and safest plan is to make the incision with a pair of straight blunt-pointed scissors, in a direction radiating from the cornea. The eyelids being held apart by an assistant, the surgeon with a pair of hooked forceps takes hold of the overlapping fold of conjunctiva and cuts it across with the scissors. A radiating incision results. Three or four such incisions may be made at equal distances round the cornea.

The excision, by means of a hooked forceps and curved scissors, of small folds of the chemosed conjunctiva, here and there; or, the excision of the whole of the chemosed conjunctiva all round the cornea, is a proceeding of doubtful advantage.

Anodyne Friction.

Friction over the eyebrows or on the temples with some anodyne is often of use in mitigating the supra-orbital or temporal pain, which attends many internal ophthalmiæ. The following tincture of tobacco is a good example:

℞—Tabaci fol. consis. f℥jss.
Camphoræ pulv. ℥j.
Alcohol. fort.
Aq. destillat. aā ℥iv.
Digere per dies octo et cola.
Sig. ℥ss.—℥ij to be used at a time.

[There is probably no better medium for anodyne friction than the belladonna or stramonium ointment or its equivalent, an oleaginous dilution of either of the active principles.]

Counter-irritation.

In diseases of the eye, counter-irritation is usually made on the nape of the neck, behind the ears, or on the crown of the head, by means of repeated blisters, tartar-emetic plaster, or rubefacient liniments. When the counter-irritation is required to be long continued, it is made by means of warm plasters between the shoulders, a seton in the nape of the neck, or issue in the arm.

Counter-irritation is sometimes applied nearer the affected organ, as on the temples, above the eyebrow, or even directly on the outside of the eyelids. In this case, the most convenient counter-irritant, perhaps, is the following spirituous solution of iodine painted on the skin; ℞. Iodinii et Potassii Iodidi, sing., 3j; Spiritus vini rectificati, 3ss.; Solve. Cauterization with nitrate of silver may be also employed, and even the application of blisters. [The alcoholic or ethereal tincture of iodine is an admirable counter-irritant. It may be applied with great advantage around the eyes and even on the lids, as well as behind the ears. The nitrate of silver in solution may be employed in the same manner, although more objectionable. Another good application of this kind is a mixture of creosote and collodion, in the proportion of from half a fluid drachm to a fluid drachm of the former to a fluid ounce of the latter. Blisters are rarely, if ever, desirable on the temples and often do harm when thus applied. The cantharidal collodion is the most convenient vesicant, especially for children.]

Evulsion of Eyelashes.

The instrument best adapted for the performance of this simple but nice operation. is a forceps with broad points, like tweezers, Fig. 8; but a common good anatomical forceps will do. The eye-

Fig. 8.

lid being slightly everted and drawn from the eyeball with his left hand (p. 43,) the surgeon, with the forceps in his right hand, proceeds to pluck out one hair after the other singly; and the mode of doing so is to take hold of it with the forceps as near its root as possible, and to pull it out steadily—not too quickly nor with a jerk, as by doing so the eyelash is more apt to be broken short. If the eyelash should break short, its stump must be carefully looked for, seized with the forceps and plucked out, for if left it would irritate more even than the eyelash did when entire. If eyelashes are to be plucked out from both eyelids, the operation should be first performed on the upper.

Foreign Bodies in the oculo-palpebral space of the conjunctiva, and their removal.

When a foreign body has got into the oculo-palpebral space of the conjunctiva, it is, in common language, said to have got *into the eye.*

Chemical or mechanical irritation of the conjunctiva is followed by a spasmodic closure of the eyelids and the discharge of a flood of tears. If the irritation have been produced by a substance in the state of vapor, the conjunctiva is in this way protected from its further action, and the smarting soon subsides. Strong acid vapors, however,—of nitrous or hydrochloric acid for example,—may at once produce serious injury by decomposing the epithelium of the conjunctiva and cornea.

Consistent substances of a kind not calculated to adhere to the conjunctiva, are either immediately washed out of the eye by the tears, the discharge of which they have excited, or in the case of small particles, they may be found after some time lying enveloped in mucus in the lacus lacrymalis, having been carried thither by the movements of the eyelids, and the stream of tears.

When a foreign solid particle lies between the firm part of the eyelid and the eyeball, it causes great irritation, and excites the orbicularis muscle to strong spasmodic action. This serves but to aggravate the distress, by fixing the particle, if it be of a nature to adhere to the conjunctiva.

In a case in which a foreign body has got into the eye, and from the seat and severity of the irritation it is supposed to be lodged between the firm part of the upper eyelid and the eyeball,—if on gently raising the upper eyelid, and carefully examining the surface of the cornea and white of the eye, the foreign particle be not detected there, and if after taking hold of the upper eyelid by the eyelashes, and drawing it down over the edge of the lower eyelid, so that the eyelashes of the latter may sweep the inner surface of the upper eyelid, the particle is not felt to be removed, the upper eyelid should be everted, and its conjunctival surface examined as above described (p. 43), when most probably the offending particle will be discovered adhering to it. If the foreign particle is not at once detected, the possibility of its being transparent should be taken into consideration, and an examination of the whole exposed surface made with great care.

The foreign particle having been detected, it may readily be removed by the touch of a hair pencil, moistened and brought to a point, or of a toothpick, or the eyed end of a probe, or any other flat blunt-pointed instrument, [or the corner of a soft napkin or cambric handkerchief.]

Foreign bodies when within the lower eyelid do not cause so much irritation as when within the upper, and their detection is more easy, the lower eyelid being more readily everted than the upper (p. 43). [The irritation may be much diminished and the foreign body sometimes floated out by the immediate resort to the free introduction of mucilage or the white of egg.]

Foreign bodies which have entered the oculo-palpebral space, sometimes get lodged in the palpebral sinuses of the conjunctiva, and may there be retained for a length of time, without much or any irritation, the conjunctiva of the sinuses being so loose, and the subjacent cellular and adipose tissue of the orbit so soft, that the body is not much pressed on by the opposing surfaces. The large size of the bodies which have been found lodged in the palpebral sinuses without having given rise to irritation, is astonishing.

When, therefore, notwithstanding the absence of much, or any irritation, there is still reason to believe that a foreign body is in the oculo-palpebral space, and when by the mode of examination above described, it has not been detected, attention should be directed to the palpebral sinuses, and an exploration of them made as above described (p. 43).

Cases not unfrequently occur in which splinters of wood, pieces of straw, fragments of tobacco-pipe, &c., have penetrated through the conjunctiva of the sinuses into the orbit, and their presence, for want of careful exploration, overlooked.

A foreign body, especially when projected with force into the eye, may at once adhere to the ocular conjunctiva—generally the conjunctiva corneæ. It sometimes happens that the husks of small seeds, and other analogous bodies, such as the wing-case of certain insects, or, as I have seen in a fisherman, one of the valves of a minute bivalve shell, getting into the eye, adhere very closely to the sclerotic or corneal conjunctiva. Inflammation having set in, these foreign particles are liable to be mistaken for pustules or phlyctenulæ, resulting from the inflammation. This, therefore, should lead to a careful examination in any suspected case, when the nature of the body on the cornea cannot fail to be recognized. Removal is readily effected by any of the instruments above mentioned.

The ignited sparks detached from iron instruments in the course of various operations, called *fires*, and which so frequently strike and sink into the conjunctiva corneæ of the workman, appear as small dark points on the surface, with some dimness of the cornea around. They give rise to more or less pain, especially when the eyelids are closed, together with redness and lacrymation.

The foreign body is at first firmly fixed, but afterwards becomes loose. It is in general easily turned out of its nidus by means of

a toothpick or small silver spatula. When removed it is found, on close examination, to be black oxide of iron fused into a minute globule.

If the removal from the eye, of such foreign bodies as are above mentioned, is effected soon, the distress is at once relieved or greatly mitigated. Sometimes a sensation remains as if the foreign body were still in the eye; this is owing either to vascular injection or to abrasion of some part of the conjunctiva.

Caustic or hot substances, whether solid or fluid, getting into the eye, so quickly exert their action, that much, if not all, the injurious effects have already occurred before means can be taken for their removal.

While solid caustic substances are still in the eye, the best application to make in the first instance is sweet oil. After that, the surgeon may proceed to remove the foreign substance, and to effect this some pains will often be required, especially if it has been lime or mortar, for the particles of these substances are apt to adhere very closely to the conjunctiva. Exploration of the palpebral sinuses should not be neglected, lest pieces may have lodged there. After the eye has been freed as completely as can be done from particles of lime or mortar, water should be injected into the eye, in order to carry away what remains of the caustic may exist.

When gunpowder has been exploded into the eye, besides the burn which results, the grains may fix in the conjunctiva and in the cornea—in which case, unless carefully picked out, they will leave indelible marks and opacities..

Particles of such substances as potass, nitrate of silver, &c., getting into the eye, quickly become dissolved in the tears, and their injurious operation may spread like that of a caustic fluid, before they can be removed.

In this case, and in the case of caustic fluids, the application, in the first instance, should be some substance calculated to decompose them and render them inert, so as at least to arrest their further destructive action; thus, in the case of sulphuric acid, which has sometimes been thrown into the eyes of persons with a criminal intention, a solution of subcarbonate of soda—gr. iv. aq. ℥j; or magnesia suspended in water, should be immediately used as a lotion and injection for the eyes.

Simply hot substances, such as melted tallow, pitch, or lead, quickly cool of themselves, and all that requires to be done in the first instance is their removal. If pitch cannot be readily removed, sweet oil will promote its separation.

The penetration of foreign bodies into, and their lodgment within the eyeball; as also the effects of the intrusion of dif-

ferent foreign bodies into the eye, and their treatment, will be considered under the head of *Injuries of the Eye.*

Fig. 9.

Evacuation of the Aqueous Humor by puncture of the cornea.

The various objects for which this operation is had recourse to are detailed in their proper places. Here the operation itself only has to be described. It is simply the first step in making the section of the cornea for the extraction of a cataract. A cataract-knife or a lancet-shaped knife (Fig. 9) is the instrument best adapted for the purpose. If the operation is undertaken when the eye is very intolerant of light, there is great difficulty in exposing the cornea sufficiently for the purpose, as on the eyelids being opened, the eyeball is involuntarily rolled upwards. One eyelid requires to be secured by an assistant, while the surgeon takes charges of the other. The knife is entered at about one-twentieth of an inch from the sclerotica, and in doing so, the principal precaution to be observed is not to push the point on in the substance of the cornea, under the impression that it has penetrated into the anterior chamber. The extent to which the blade is pushed into the anterior chamber should be such, that its point do not advance beyond the temporal margin of the pupil, so that were the aqueous humor suddenly evacuated, the iris might be between the point of the instrument and the lens. Hence the propriety of using an instrument of the shape mentioned, which is calculated to make a sufficiently large puncture without penetrating far into the anterior chamber. The puncture having been sufficiently made, the instrument is to be withdrawn a little and slightly turned on its axis, so as to make the wound gape, and thus allow the aqueous humor to flow out. In proportion as this takes place, and the iris approaches the cornea, the knife is withdrawn.

CHAPTER II.

OPHTHALMIC INFLAMMATION.

As many of the most important diseases of the eye consist either in inflammation itself, or in its effects, and as all our operations on the organ must be regulated by the kind and degree of inflammatory reaction we expect to follow, an accurate knowledge of the ophthalmiæ must ever be considered the master-key of our subject, and worthy, therefore, of the most particular attention of the practitioner.

Section I.—Inflammation in General.

In entering on the study of ophthalmic inflammation, it will be useful to call to mind the following particulars respecting the nature of the phenomena of the inflammatory process in general.

INFLAMMATION PROPER.

The first step in inflammation proper, is *congestion*—the second, *increased exudation*. Congestion is manifested by *preternatural redness*, which is owing to the stagnation and accumulation of red blood-corpuscles in the small vessels. Exudation from the blood, first of serum, subsequently of lymph in increased quantity, supervenes, as an effect of the congestion; and is manifested in different ways, according to the structure of the part affected, *e. g.* by *swelling, thickening, opacity, phlyctenulæ, pustules, discharge, &c.*

None of the corpuscles of the blood escape along with the exuded plasma, but a rupture of some of the congested vessels may occur, in which case, there is *extravasation of blood*, which is manifested either by actual hemorrhage, or the infiltration of the tissue in the form of ecchymosis, &c. The redness of ecchymosis is in general readily distinguished from that of vascular congestion.

With exudation is completed the inflammatory process properly so called.

TERMINATIONS OR EVENTS OF INFLAMMATION.

Inflammation terminates either in the healing process or in mortification.

As congestion and exudation are the essential steps of inflammation proper, so re-establishment of the circulation, and absorption of the exuded matter, manifested by the disappearance of the redness, subsidence of the swelling, &c., constitute the most direct termination in recovery, viz.: *Resolution.*

In cases in which there is solution of continuity, the healing process is not so direct and the exuded matter plays a more important part. It is converted into new tissue, by which the wound is united or filled up, according as the circumstances are such as to permit of "adhesion" or "healing by the first intention;" or only of "granulation with suppuration," or "healing by the second intention." The congestion and exudation, and therefore the redness and swelling of the part, do not cease on the occurrence of either of these forms of the healing process. They continue until the wound is cicatrized—the congestion being the necessary condition of exudation; the exudation, again, that of the supply of material wherewith regeneration is effected.

When mortification takes place, the dead part tends to be thrown off in the form of a slough. The separation is effected by a process of softening of the dead part, and the establishment of suppuration at the surface of the living where there is congestion.

The process of *ulceration* is the opposite of that of *granulation.* For whereas in a granulating sore, the exuded matter is developed partly into tissues, partly into pus; in an ulcerating sore the exuded matter is not only not organized into new tissue, but that of the affected part loses its vitality, and is thrown off in minute portions from the surface along with the discharge, which is either a mere sanies, or at the most an imperfectly developed pus. From this it is seen that *ulceration* belongs to the head of *mortification.*

The phenomena of inflammation and its events above described are *objective,* or such as admit of being observed by the surgeon. The *subjective* phenomena, or those which the patient alone perceives, are the pain and other morbid sensations. The heat which attends inflammation is at once both objective and subjective.

The *objective increase of heat,* or that actual increase ascertainable by the thermometer, is owing to the congestion. The *subjective increase of heat,* or the patient's sensation of increased heat, depends partly on the objective increase, and partly on the exalted susceptibility of the sensitive nerves of the affected part.

The *pain* which may occur at first is a manifestation of the increased sensibility of the sensitive nerves occasioned by the exciting cause of the inflammation. The aggravation and new kinds of pain which supervene, are owing to the irritation of the nerves, already in a state of excitement, produced by the pressure

exerted by the congested vessels and exuded matter. Other parts than that which is the immediate seat of the inflammation, may be sympathetically affected.

DISTINCTION OF INFLAMMATION INTO ACUTE AND CHRONIC.

Acute and chronic inflammations are so named from the most striking parts of their character,—the former being distinguished by severity of symptoms, the latter by long continuance. In the acute form of inflammation, with severity of symptoms, there is combined rapidity of progress; and in the chronic form, long continuance is tempered by mildness of symptoms.

These differences, it will be observed, are merely differences in degree and continuance. There does not appear to be any essential difference in nature between the acute and chronic forms of inflammation. In both there is congestion, in both exudation, and in both the exuded matter undergoes analogous changes. Moreover, it is to be observed, that between well-marked acute and well-marked chronic inflammation, all intermediate forms are met with.

The conditions on which the striking parts of the character of acute and chronic inflammation appear to depend, are respectively the following:

In acute inflammation, the congestion is greater; and if resolution, to which there is a tendency, does not soon ensue, exudation of lymph takes place more or less copiously, the result of which is adhesion, or abscess, or thick puriform discharge, as the case may be, after which the circulation may gradually become re-established, and so there is an end of the inflammation.

In chronic inflammation, on the contrary, the congestion is less complete—there is but little tendency to resolution—and exudation is either not so copious within a given time, or it is more watery. Moreover, the congestion persists, and the exudation still goes on, the result of which is hypertrophies, gleets, &c., as the case may be.

Chronic inflammation may either succeed to acute inflammation, or come on slowly of itself, unpreceded by any acute stage. Acute inflammation may supervene on chronic inflammation.

SECTION II.—OPHTHALMIC INFLAMMATION IN GENERAL.

As inflammation is seldom or never confined to a single structure of the eye, but generally involves several at the same time, so a description of inflammation in individual structures would be, as has been remarked by a distinguished writer on the subject, a description of a state which seldom or never presents itself separately in nature. Notwithstanding this, it will be useful to premise

an abstract account of the characters peculiar to inflammation of individual structures, preparatory to entering upon the study of the varied combinations which actually present themselves in practice. Our descriptions will thus admit of being given both more briefly and more clearly.

INFLAMMATION AS IT OCCURS IN THE DIFFERENT TISSUES OF THE EYE.

In discussing this subject, I will first consider the objective phenomena of inflammation of the different structures of the eye, and then the subjective phenomena.

Conjunctivitis, or inflammation of the conjunctiva.

The principal forms of inflammation, of which the conjunctiva may be the seat, are pustular, catarrhal, purulent, and erysipelatous.

Pustular inflammation.—A small, often apparently isolated spot of vascular injection, with slight swelling of the sclerotic conjunctiva at some little distance from the margin of the cornea, with a flake of matter in the middle. Such are the manifestations of the congestion and consequent exudation in this most simple form of conjunctival inflammation.

In consequence of its little cohesion, the epithelium of the conjunctiva scleroticæ does not, like the epidermis of the skin, retain the matter exuded underneath it, but gives way, leaving an abrasion covered with the flake of exuded matter, now become pus or puriform.

Besides the red spots from vascular congestion, there may be patches of ecchymosis.

The inflammation extending, the continuity of the vessels of the spot of inflammatory injection with those of the rest of the conjunctiva, often at first not distinguishable by the naked eye, comes to be distinctly visible. By-and-by, inflammatory injection of the conjunctiva may supervene, but the injection continues greatest in the region of the pustule or the abraded or ulcerated surface left by it. Some puromucous secretion attends this extension of the inflammation as the result of the increased exudation. In such a case, it may be said that to the pustular, catarrhal inflammation has been superadded.

Healing process in pustular inflammation of the conjunctiva.—In cases left to themselves, we often find along with increase of the inflammatory congestion, the abrasion or superficial ulceration of the conjunctiva extended. But under the influence of irritating applications to the eye, the vascular injection speedily disappears,

and *pari passu*, healing of the abrasion or superficial ulceration takes place, the surface becoming covered with a new epithelium.

The cases in which pustules present themselves quite at the margin of the cornea are not of so simple a character as those above described, but constitute a transition to phlyctenular or common scrofulous ophthalmia. The injected vessels extend to the pustules, in fasciculi from the corresponding side of the sclerotic conjunctiva. The thick epithelium of the cornea is at the part opaque and slightly raised by the exuded matter, which, with the softened epithelium of the sclerotic conjunctiva of the spot affected, forms, as in the preceding case, the small yellow flake. This form of pustule thus presents a character intermediate between the phlyctenula or pustule of the cornea and the abraded spot of the sclerotic conjunctiva above described.

Catarrhal inflammation of the conjunctiva.—The conjunctiva of the eyelids and of the palpebral sinuses, is deep red. The conjunctiva oculi is also deep red at its circumference, but towards the cornea the redness is, at the commencement of the inflammation, gradually shaded off; when, however, the inflammation is fully established, the redness extends even to the margin of the cornea.

The injection of the highly developed capillary network of the palpebral conjunctiva gives rise to a uniform and intense redness, concealing from view the larger subjacent vessels. Except in a very high degree of inflammation, the injection of the less developed capillary network of the sclerotic conjunctiva does not conceal the larger subjacent vessels. Indeed, what most strikes the observer, is the network with large meshes formed by the intercrossing and inosculation of comparatively large and tortuous vessels, the ramifications of which tend towards the margin of the cornea. These vessels are the arteries and veins which carry the blood to and from the superficial capillary network—veins especially, for the arteries are rather constricted, and, therefore, not so apparent.

In consequence of the accumulation of blood in its vessels, the conjunctiva is thickened. The papillæ of the palpebral conjunctiva, being for the same reason swollen and erect, the inner surface of the eyelids has a velvety appearance.

The conjunctiva covering the caruncula lacrymalis, and forming the semilunar fold, is deep red, like the palpebral conjunctiva, and being at the same time thickened by the accumulation of blood in its vessels, both the lacrymal caruncle and semilunar fold appear much enlarged.

At the commencement of the inflammation a serous exudation takes place from the surface of the conjunctiva. By-and-by, a puromucous discharge, the presence of which is an important cha-

racter of the inflammation, is established. On everting the lower eyelid, a flake of exfoliated conjunctival epithelium with puro-mucus is generally seen in the lower palpebral sinus.

The eyelids, besides being somewhat red, are more or less swollen, from serous exudation into their cellular tissue. There may also be exudation into the cellular tissue underneath the sclerotic conjunctiva, raising it up like a wall round the cornea, constituting *chemosis*. Tumefaction of the eyelids and chemosis are analogous in their nature and mode of production to that swelling which takes place in the neighborhood of any active inflammation.

Ecchymotic spots sometimes present themselves, especially over the sclerotica, in consequence of extravasation of blood into the substance of the sclerotic conjunctiva, or into the cellular tissue underneath.

Healing process in catarrhal inflammation of the conjunctiva.—As vascular congestion, or in other words, the redness diminishes, the seromucous or puromucous discharge becomes less and less, and any accompanying chemosis and swelling of the eyelids subside. It is to be remarked, that the vascular congestion of the palpebral conjunctiva disappears less quickly than that of the ocular conjunctiva.

Purulent inflammation of the conjunctiva.—Here we have all the phenomena of catarrhal inflammation in an aggravated degree—the vascular injection more intense, the discharge more copious and purulent, the swelling of the eyelids and chemosis greater. There may be actual discharge of blood from the surface of the conjunctiva.

From the description now given of purulent inflammation of the conjunctiva, it appears that the matter which is exuded from the inflamed surface is converted into pus, though the surface is not ulcerated. On the other hand, the lymph which may have been exuded into the substance of the membrane is developed into tissue, which is the cause of that thickening of the palpebral conjunctiva, and enlargement of its papillæ, which remain for a greater or less length of time, or even permanently, after the inflammation has subsided.

Granular conjunctiva.—This morbid condition is peculiar to the conjunctiva of the eyelids, palpebral sinuses, and semilunar fold. It is a distinguishing character of that inflammation of the conjunctiva which prevails in workhouses, barracks, &c., usually chronic, but [liable to accessions of acute conjunctivitis termed "relapses" and] under favoring conditions running into the violent purulent ophthalmia.

The so-called granulations of the conjunctiva present themselves as unelevated yellowish points in the red and thickened conjunc-

tiva over the tarsal cartilages; but in the palpebral sinuses, they have the form of more or less elevated phlyctenulæ. Just within the edges of the eyelids, also, they are met with of the phlyctenular form, arranged in a row. The exuded matter contained in these phlyctenulæ is found at a certain stage, softened, and in the form of a grayish matter, consisting of cells in different phases of development. In a more advanced stage, the phlyctenulæ are found to have burst, and the matter oozing out from them. In this stage we find something like real granulations rising from the bottom or edges of the burst phlyctenulæ.

Another form of granulations appears to consist simply in hypertrophy of the papillæ of the palpebral conjunctiva, investing the tarsal cartilages.

Pseudo-membranous exudation on the conjunctiva.—In inflammation of mucous membranes it is well known that the matter exuded on the surface is sometimes found in the form of false membranes. This matter, however, does not, like that exuded by serous membranes, become organized into tissue; such false membranes are usually separated and thrown off.

In some cases of phlebitic ophthalmia, exuded lymph is found on the conjunctiva. An approach, perhaps, to pseudo-membranous exudation on the surface of the conjunctiva, also sometimes presents itself in the purulent ophthalmiæ.

The coagulation and exfoliation of the epithelium, especially of the cornea, in consequence of chemical injuries, must not be mistaken for pseudo-membranous formation.

Erysipelatous inflammation of the conjunctiva.—The most remarkable appearance in this ophthalmia is the watery exudation under the sclerotic conjunctiva, whereby the latter is raised up in folds which protrude like vesicles between the eyelids. The conjunctiva is of a light-red color, inclining to yellow, and presents here and there spots of ecchymosis, but few individual vessels are readily discernible. The mucous secretion of the conjunctiva is somewhat increased in quantity.

Mortification and ulceration of the conjunctiva.—Mortification of the conjunctiva, as a consequence of inflammation, does not appear to have been met with, but sloughing of parts of the conjunctiva, in consequence of chemical injury, sometimes occurs. Ulceration, except from a specific cause, seldom takes place.

Healing of wounds of the conjunctiva.—Wounds of the conjunctiva readily heal. The conjunctiva becomes injected at the edge of the wound, and lymph is exuded, which becomes organized in the manner already explained, according as the union is by the first or second intention, one or the other event being in general

determined by the apposition or non-apposition of the edges of the wound, as in the skin.

The palpebral and ocular surfaces of the conjunctiva, though inflamed, have no tendency to form adhesions even while kept in close apposition, unless previously made raw. When abrasion of the surfaces has been produced, especially by burns and escharotics, there is then great tendency to the formation of adhesions.

Sclerotitis, or inflammation of the sclerotica.

The redness is in the form of a pink or lake-colored zone, encircling the cornea; the injected vessels of the sclerotica being very minute, and disposed in straight radiating lines. The tint is deeper at the margin of the cornea, whilst it is shaded off, and disappears towards the orbit—the converse of what occurs in the injection attending conjunctival inflammation.

If the vascular congestion be alone taken as inflammation, then it must be said that the part of the sclerotica visible during life through the conjunctiva, is often inflamed, but if exudation and the changes which the exuded matter undergoes, be rather assumed to be indicative of inflammation, then it must be admitted that the sclerotica is comparatively rarely the seat of inflammation.

Fibrous tissues in general do not appear to be more frequently the seat of the effects of inflammation than the sclerotica, but are they not as frequently the seat of vascular congestion? Is rheumatism anything more in most cases than vascular congestion, in fibrous tissues, with, perhaps, serous exudation into neighboring parts? What is called rheumatic ophthalmia appears to be at least nothing more than inflammatory congestion of the sclerotica, usually with more or less implication of the cornea and iris.

Rheumatism or inflammatory congestion in fibrous structures, may at last lead to exudation of lymph either into the substance or on the surface of the part affected—in the one case giving rise to the thickening and induration of the fibrous structures, in the other, to effusions into the joints or adhesions, such as are met with in pericarditis. By repeated congestions, the sclerotica is indeed left in a somewhat altered state, but it is the cornea or iris which is principally the seat of exudation of lymph and the changes consequent on it, as the joints are in articular rheumatism.

Pink vascular injection, with thickening and elevation of the sclerotica in patches adjacent to the cornea, chiefly at the nasal, temporal, and lower margin, I have met with in scrofulous children from eight to twelve years of age. Though there was some conjunctival injection at the place, and slight dimness of the cor-

nea supervened, the sclerotica appeared to be the part principally affected. Recovery took place slowly under treatment, the congestion disappearing and the thickening subsiding.

The most marked example, perhaps, of the tissue of the sclerotica becoming the seat of changes from inflammation, occurs in sclerotico-choroiditis. The first change is a thickened and fleshy appearance of the sclerotica, but its texture becoming at the same time softened, it by-and-by yields to the distension from within the eye, protrudes and becomes attenuated, and of a dark color (*sclerotic staphyloma*). In some cases, however, instead of becoming attenuated and dark, the affected part of the sclerotica actually becomes thickened, and of a dense white pearly appearance.

[In such conditions a peculiar square or cuboidal form may be observed in the shape of the eyeball, which has been noticed as characteristic of rheumatism of this portion of the eye.]

Corneitis, or inflammation of the cornea.

The cornea, though vascular whilst being developed, is in its fully formed and healthy state non-vascular, and yet inflammation of the cornea is spoken of.

The cornea, there is reason to believe, derives the materials necessary for its nutrition from the blood circulating in the vessels of the adjoining parts of the conjunctiva and sclerotica. Let us inquire what takes place in the cornea when it suffers such injury as would excite inflammation in one of the vascular parts of the eye.

When the cornea is injured, then, congestion of the vessels of the adjoining parts of the conjunctiva and sclerotica takes place, and exudation into the substance of the cornea by-and-by ensues. Thus, though non-vascular, and of course, not the seat of inflammatory congestion, it becomes the seat of a very important part of the inflammatory process—the most important part, perhaps, as regards the events of the process.

The cornea in this state may therefore be said to be, to all intents and purposes, inflamed—the only difference in respect to it, as compared with vascular parts, being, that the vascular congestion is *not in it* but in *adjoining structures.*

On the other hand it is to be remarked, that although these adjoining structures are the seat of the congestion, little or no exudation may take place in them or on them, and they may therefore be said to be scarcely or not at all the seat of inflammation as regards the events of the process. When the conjunctiva and sclerotica are really inflamed, exudation in or on them may occur, but then the congestion is different in seat and extent from what it is when the cornea is the seat of the inflammation, and there may be no exudation into the cornea—the cornea may remain unaffected.

In the progress of inflammation of the cornea, this structure may become vascular, but such an event is owing to the development of new vessels, such as also happens in inflammation of vascular parts.

Though inflammation of the cornea, considered as a non-vascular part, has been thus dwelt on, the truth is, that all tissues, as regards their component elements, are properly speaking, non-vascular, and differ from the cornea only in the degree of proximity to the vessels, and therefore in inflammation only in the degree of proximity to the source of the exudation.

But this very difference in the case of the cornea affords a natural analysis of the inflammatory process. It enables us to observe separately the two great stages of inflammation proper—the *congestion* and *exudation*—the congestion in one place, the exudation in another. It also enables us to observe, in an uncomplicated manner, the eventual stages of inflammation, such as reorganization and suppuration.

That the cornea is the seat of exudation is manifested by opacities of various kinds, phlyctenulæ, and abscesses. When new vessels are developed in the exuded matter, the cornea then becomes the seat of more or less redness. This, however, is to be distinguished from that which may result from effused blood. When effusion of blood occurs, it appears usually in a patch near the edge of the cornea.

When resolution of inflammation of the cornea above referred to takes place, the irritability of the eye ceases, and, on the one hand, the congestion of the neighboring conjunctiva and sclerotica diminishes; then, on the other, the exudation in the substance of the cornea disappears.

The cornea has just been referred to as a part which, from its non-vascularity, forms a good subject for observing, in a manner uncomplicated by the presence of the vessels in which the blood is stagnant, the development and disposition of the exuded matter in the healing process. The matter exuded into the substance of the cornea from the vessels of the adjacent conjunctiva and sclerotica may (as far as examination with the naked eye, or the eye assisted merely by a magnifying glass goes) be seen to undergo the different modes of development above described.

It may be seen that pustules form, and that, in the healing of incisions and ulcers of the cornea, adhesion and granulation, and, lastly, cicatrization, may take place without the development of new vessels—a convincing proof that neither suppuration nor "organization" necessarily implies the development of new vessels.

But, as above hinted, new vessels may be formed in the matter exuded into the cornea, and this again affords a very interesting and readily observable example of the development of new vessels,

uncomplicated by the previous existence of other vessels in the part.

The new vessels, having served their purpose, shrink and disappear, and it is usually not until this has taken place that cicatrization is completed.

One or other of the three principal layers of the cornea may be more particularly the seat of the exuded matter; hence are distinguished inflammation of the proper substance of the cornea, of the conjunctiva corneæ, and of the membrane of Descemet.

Inflammation of the proper substance of the cornea.—In inflammation of the proper substance of the cornea, the vascular congestion is seated in the sclerotica in the form of the sclerotic circumcorneal zone, but sometimes the redness is very slightly marked. There is generally also congestion of the circumcorneal network of the conjunctiva.

The exuded matter is deposited either in the interstices of the tissue or on its surface, raising the epithelium in the form of a phlyctenula, or even a blister.

The exudation into the interstices of the proper substance of the cornea, may produce map-like patches of dimness and nothing more. Or the exudation being in greater quantity, a general grayish or yellowish-white opacity results, denser at some points than others, and intermixed with red from the presence of new vessels. In this case, the cornea presents a peculiar opalescent appearance.

In certain cases there is less exudation and development of vessels; the cornea still retains a degree of transparency, but is of a dirty yellowish-green color, and rough like ground glass, owing to minute vesicles on its surface, or minute points of ulceration, resulting from the bursting of the vesicles. There is softening of the cornea in all these cases.

When exudation into the proper substance of the cornea, or under the epithelium, takes place rapidly and copiously, the exuded matter is generally formed into pus or puriform matter, and the result is an abscess or a pustule. In such cases the inflammation is more of an acute character than in the preceding. There is more vascular congestion in the conjunctiva and sclerotica, so much so, that the cases in question are commonly viewed as examples of corneitis supervening on inflammation of the conjunctiva and sclerotica, while the preceding cases are, on account of the slight appearance of congestion in the conjunctiva and sclerotica, viewed as examples of primary corneitis. But from what has been above said of inflammation of the cornea, there is no *primary corneitis* in the sense here implied, *i. e.* with vascular congestion first in the cornea.

The depositions of yellow matter which occur in the interstices of the cornea at its lower part, and which, on account of their pre-

senting the form of the lunular spot at the root of the nails, are called *unguis* or *onyx*, and which are in general rapidly absorbed as the attendant inflammation is subdued, have not the character of abscesses like the circumscribed collections of matter which form in the centre of the cornea, appearing as a densely opaque spot, first white, then yellow, around which the rest of the cornea is more or less opaque from exuded lymph, in which there may be new vessels, as in the walls of abscesses elsewhere.

Most frequently the exuded matter is deposited on the surface of the proper substance of the cornea, raising the epithelium in the form of a phlyctenula or blister. The epithelium of the cornea being denser, thicker, and more coherent than that of the sclerotic conjunctiva, confines the matter which is exuded, in much the same way that the epidermis of the skin does. The matter being at first a transparent fluid, there is a phlyctenula; subsequently becoming puriform or purulent, there is a pustule. Often the process does not proceed so far as the formation of a pustule.

A phlyctenula or pustule of the cornea having burst, a small ulcer covered with purolymph is left, which may be compared to the spot on the sclerotic conjunctiva in pustular ophthalmia. A fasciculus of new vessels extending to this ulcer from the conjunctival circumcorneal network, may make its appearance.

Healing process in inflammation of proper substance of the cornea.—When the congestion around the cornea subsides, the matter exuded into its substance may gradually be absorbed. And this even when development of it has gone on to the formation of new vessels, though tardily, for the more the exuded matter has been developed, the less readily does it dissolve and become fitted for absorption. The new vessels first disappear, leaving a grayish-white opacity, which clears away from the circumference towards the centre of the cornea, where often more or less opacity remains.

A pustule on the surface of the cornea, or an abscess in its proper substance, may disappear by absorption of its contents, leaving, however, more or less opacity; but these collections of matter usually burst, and leave a sore, which may either commence to heal by granulation or run into ulceration.

Inflammation of the conjunctiva corneæ.—This usually accompanies acute inflammation of the proper substance of the cornea, or is an extension of inflammation of the sclerotic conjunctiva.

In consequence of the exudation, the conjunctiva corneæ becomes at some point opaque and thickened, and here new vessels are soon formed, which, connecting themselves with the conjunctival circumcorneal network—which at the place is in a state of congestion—appear as a mere extension of a fasciculus of vessels from it. The opacity and vascularity may gradually spread over the cornea.

In some cases of what may be called inflammation of the conjunctiva corneæ, there are fewer new vessels and less opacity, but there is superficial spreading ulceration. In certain cases the cornea presents here and there on its surface vascular fungous granulations.

The changes which the conjunctiva corneæ undergo in inflammation, the thickening and vascularity, are very apt to remain in the forms of pannus, vascular cornea, &c.; but often they disappear entirely, and the cornea resumes its natural appearance.

Inflammation of the membrane of Descemet.—In this inflammation, the vascular congestion is in the sclerotic zone. The exuded matter is deposited between the proper substance of the cornea and the membrane, and generally presents itself in the form of scattered punctiform opacities. Here also new vessels, when formed, make their appearance.

As the inflammatory congestion subsides, the exuded matter is removed by absorption.

Ulceration of the cornea.—The cornea is extremely prone to ulceration. The ulceration may be limited to a mere abrasion or exfoliation of the epithelium, or it may affect the proper substance of the cornea also. The membrane of Descemet does not appear to be liable to ulceration; but when exposed and deprived of support by penetrating ulceration of the proper substance of the cornea, it eventually bursts.

Abrasion of the epithelium presents itself either in that form, in which its substance looks like ground glass, or in a form like what is presented after death, when the epithelium begins to soften, and portions of it are detached by wiping the surface. The first form occurs in inflammation of the proper substance of the cornea. The second is rather a result of inflammation of the conjunctiva corneæ; there is superficial vascularity, and the abrasion, like ulceration, has a great tendency to spread; but while it spreads on one side, cicatrization may be seen taking place on another. The cicatrization gives rise to slight opacity.

Ulceration of the proper substance of the cornea generally commences by the bursting of an abscess or phlyctenula. Both the bottom and edges of the ulcer may be clear, and the cornea around scarcely, if at all, nebulous. In other cases the bottom of the ulcer is filled with a grayish, sloughy-looking matter, which is thrown off to be succeeded by the same thing, whilst the ulcer goes on increasing in depth, and may at last completely perforate the cornea.

Hernia of the cornea—(Keratocele).—When an ulcer has penetrated through the proper substance of the cornea, the membrane of Descemet, unable to withstand the pressure from within, is protruded at the bottom of the ulcer, in the form of a small vesicle filled with

aqueous humor. This hernia of the cornea, or rather prolapse of the membrane of Descemet, usually bursts ere long; the aqueous humor is thus allowed to escape, whereupon the iris falls forward into contact with the cornea, and perhaps a prolapse of it takes place through the ulcerated opening in the cornea.

If now a remission of the attending inflammation take place, which is apt to happen, in consequence of the relief of tension produced by the evacuation of the aqueous humor, the ulcerated opening in the cornea heals, the aqueous humor again accumulates, and the iris returns to its natural position, provided no prolapse of it had taken place.

In some cases, when ulceration of the cornea is both broad and deep, but not penetrating entirely through the proper substance, the hernia of the cornea which takes place is large, but still invested with some of the corneal tissue. In consequence of this it does not so readily burst, but may remain permanent as a thinned and projecting part of the cornea, with impaired transparency, resembling somewhat conical cornea, from which, however, it is to be distinguished. From partial staphyloma it differs in not being connected with the iris, and never being so opaque.

By the bursting of an abscess or onyx of the cornea inwards into the anterior chamber, the membrane of Descemet, and the inner part of the corneal substance, are destroyed; the outer part, then, incapable of withstanding the pressure from within, sometimes yields, and forms a prominence of a conical shape.

Mortification of the cornea.—The complete death of the cornea, and the separation of it in the form of a well-marked leathery slough, is of rare occurrence. The destruction of the cornea, which is so common in the purulent ophthalmiæ, takes place in a different manner.

The cornea, overlapped all round its margin by the chemosed conjunctiva, may be observed to continue for some time unaffected; but within a short interval it will be found to have become quite opaque and softened. To this succeeds the process of destruction, which consists in that form of mortification, with small sloughs, which constitutes ulceration. The destruction may involve the whole cornea in its whole thickness, or a part only in its whole thickness; or it may involve a superficial portion only, and this of greater or less size.

The immediate cause of all this mischief appears to be the infiltration of the substance of the cornea with exuded matter, and the mechanical pressure exerted by the chemosed conjunctiva, whereby the nutritive movements are more or less completely arrested.

Healing of wounds and ulcers of the cornea—by the first intention.—A simple incision of the cornea in general heals readily.

From the vessels of the conjunctiva and sclerotica, which are congested on that side of the cornea next the wound, lymph is exuded into the cornea at the seat of the wound, producing opacity to a greater or less extent, and of more or less intensity. The cut edges are agglutinated by the exuded lymph, and by its organization continuity of structure is restored. What of exuded matter remains in the substance of the cornea, producing opacity, is gradually absorbed, and the cornea clears in proportion as the injection of the conjunctival and sclerotic vessels subsides; a small speck perhaps, the cicatrice, merely remaining. No new vessels may have been formed in the cornea.

By the second intention.—Loss of substance of the cornea, whether produced by ulceration or otherwise, is restored by granulation. The granulations may be non-vascular, or they may be vascular, from new vessels which have been developed in the exuded matter, and which have formed a connection with those of the neighboring conjunctiva and sclerotica. These new vessels generally disappear when the process of granulation is completed, and preparatory to cicatrization. Thus, when an ulcer has filled up by vascular granulations, one vessel after another disappears, until all are gone, leaving an opaque streak where their course in the cornea had been.

At first the sore may be swollen, and more or less nebulous at the edges, and discharge a tough, yellow, puro-lymphy matter, which sometimes adheres to it, and hangs down from it in flakes. But when the ulcer begins to heal, its edges become decidedly gray and opaque, and in proportion as it becomes filled with granulations, the quantity of puro-lymphy matter discharged from it becomes less, until none at all is formed. At last cicatrization takes place, and the surrounding nebulosity diminishes until it disappears altogether.

The cicatrice is either a permanently opaque spot (*leucoma*) or it is a clear facet, presenting the appearance as if a small piece had been sliced from the convex surface of the cornea.

Effects of penetration of the cornea.—When the cornea is freely penetrated by wound, ulceration, or sloughing, prolapsus iridis takes place.

According to the size and position of the opening in the cornea, so is the extent of the prolapse of the iris, and so is the pupil more or less involved. The different degrees of prolapsus iridis have received different names; thus, when small it is called *myocephalon*, from its forming a small black point like the head of a fly;—when it is a little larger, and flattened down by the preesure of the eyelids, it has been compared to the head of a nail, whence the name *clavus*;—when larger and more prominent, it has been called *melon*,

or apple-shaped prolapse. When the iris is protruded at several openings, the appearance is somewhat like a bunch of grapes, whence the name *staphyloma racemosum*. When prolapsus iridis has taken place, all the symptoms of the attending inflammation are apt to be aggravated. But if the inflammation subsides, and if the opening in the cornea and prolapse of the iris be within certain limits, the latter gradually contracts and flattens as the ulcer of the cornea closes, and nothing at last remains but the cicatrice in the cornea, and adhesion between this and the iris—*synechia anterior*—with more or less deformed or contracted pupil. If in consequence of a more extensive destruction of the cornea, whether by ulceration or sloughing, the prolapse of the iris have exceeded the limits alluded to, it never collapses, but as will be by-and-by shown, lays the ground for the formation of a staphyloma of the cornea and iris, partial or complete.

Iritis, or inflammation of the iris.

In consequence of the coloration of the iris, it does not, like the conjunctiva, for example, when inflamed, appear red, but of a color which is a compound of its own natural color and that of the stagnant blood. Thus, as above mentioned (p. 56), a blue iris becomes greenish; brown iris reddish-brown. The pupillary circle is, however, usually rather pinkish. The brilliancy of the iris is at the same time impaired or lost. Subsequent changes in the color of the iris are owing to exuded matter and to changes in the pigment. The injected vessels are individually not very evident.

The circumcorneal zone of sclerotic congestion is well marked. The conjunctiva may be little or very much injected—so much sometimes as to hide the sclerotic injection.

The aqueous humor is at first somewhat increased in quantity by serous effusion. Exudation of lymph afterwards takes place; and that either on the surfaces or into the substance of the iris. The exudation from the anterior surface and from the pupillary margin may be directly seen. Most commonly the exudation takes place first from the pupillary margin obstructing the pupil. On the anterior surface the lymph presents itself in drops, and fine flakes of it may often be seen in the aqueous humor, rendering it turbid.

The lymph exuded at the pupillary margin soon becomes consolidated and organized, forming bands of adhesion between the margin of the pupil and the capsule of the lens (*synechia posterior*) —distorting the pupil, and sometimes contracting it to a point.

The mode in which closure of the pupil takes place appears to be this; the pupil having been in a state of contraction when the lymph was exuded, the lymph in consolidating, contracts and draws

together more closely the margin of the pupil from which it has been exuded, and to which it is adherent.

New vessels may make their appearance in the lymph forming the bands of adhesion, in that exuded on the anterior surface of the iris, and also in that filling up the pupil.

The lymph poured out at the pupil, forming bands of adhesion, becomes of a brown or yellow color from the deposition of pigment in it. Small red or brown masses of lymph are also sometimes seen on the outer circle of the iris, or at the margin of the pupil.

Though no distinct serous membrane can be demonstrated on the anterior surface of the iris, it thus, like the surface of inflamed organs, which are covered with serous membranes, pours out lymph, which gives rise to adhesions; but what is peculiar is, that the adhesion which takes place is generally between the iris and capsule of the lens, rarely, if ever, between the iris and the cornea.

Parenchymatous inflammation of the iris may be looked upon merely as a more intense degree of inflammation, in which, to exudation on the surface of the iris, there is added exudation into its substance.

There is, in acute parenchymatous inflammation of the iris, greater vascular congestion both of the conjunctiva and sclerotica, together with congestion of the choroid, as may be inferred from the accompanying photopsy during life, and from its having been found on dissection after death that there was lymph on the inner surface of the choroid.

Exudation into the substance of the iris takes place principally at the pupillary circle, and is manifested by a rusty or tawny color which that part of the iris presents.

Abscess is apt to form in such cases when acute. It appears as a small yellow tubercle on the surface of the iris, generally near its pupillary or ciliary edge, which, bursting into the anterior chamber, gives rise to a small hypopyon. The place where the abscess was afterwards appears black. When the abscess is quite at the ciliary margin, it may evacuate itself externally through the sclerotica, close to the place of its junction with the cornea.

Hæmorrhagic effusion also occurs in inflammation of the iris. The blood is usually in small quantity, forming a patch of greater or less size on the anterior surface of the iris, and tinging the exuded lymph. Sometimes an accumulation of blood appears at the bottom of the anterior chamber.

Healing process in inflammation of the iris.—As the congestion in iritis subsides, the progress of the absorption of the exuded matter is beautifully seen. Matter which has been recently exuded rapidly disappears. Tubercles of lymph with vessels ramifying on the surface progressively shrink and the blood in the vessels

becomes dark and dead-looking, like the blood in ecchymosis. Lymph, which has become organized into adhesions, having to undergo solution by a retrogressive metamorphosis, in order to be fitted for absorption, disappears slowly; and in many cases the organization is already so complete, that no process of removal takes place. Thickening and change of structure of the iris from exudation into its substance, together with contraction of the pupil and obstruction of it with lymph, are very often permanent.

Effused blood is in general readily absorbed, but after repeated effusions some remains unabsorbed, in the form of brown or black masses and patches, at the bottom of the anterior chamber and on the surface of the iris.

Inflammation of the lining membrane of the posterior chamber, or uveitis.—Lymph may be exuded in large quantity into the posterior chamber on the posterior surface of the iris, and on the anterior wall of the capsule of the lens. The source of this exudation is probably the vessels of the ciliary processes. See further on this head, infra, p. 102.

Choroiditis and retinitis, or inflammation of the choroid and retina.

The external redness of congestion, symptomatic of inflammation of the choroid and retina, cannot be seen, for, different from what is the case in regard to the structures hitherto considered, the bloodvessels of those under notice enter the eyeball at its back part.

By means of the ophthalmoscope, as above shown, pp. 48, 49, the retina and choroid may be directly observed during life, but not much has yet been made out concerning the anatomical characters of inflammation affecting them. The appearances above enumerated, viz., congestions, spots of extravasated blood, opacities of various appearance, pigment deposits, &c., as hitherto observed, have been the effects of past inflammation rather than the manifestations of inflammation in progress.[1] In active inflammation, of course, the eye could not bear examination.

As there has not yet been any opportunity of examining after death eyes which have been explored by the ophthalmoscope during life, no very accurate identification of the appearances observed in the latter case, with the changes which morbid anatomy has hitherto disclosed, can be expected.

The vessels of the choroid shine through the retina; but the

[1] An exception to this is a case of what appears to have been mild arthritic posterior internal ophthalmia, ending in glaucoma, related, by Dr. Jaeger, Jun., of Vienna, and quoted in the British and Foreign Medico-Chirurgical Review for October, 1854.

mode of distribution of the vessels of the retina and choroid is so characteristic, that inflammatory injection of the former can be readily distinguished from that of the latter independently of the difference of the seat and definition of the vessels.

Some of the opaque appearances which have been observed at the bottom of the eye are no doubt indications of exuded matter deposited between the choroid and retina, producing adhesion of the two membranes, with alteration of their textures, including the pigment membrane of the one and stratum bacillosum of the other, and has been repeatedly found on dissection. Others of the appearances again seem more distinctly referable to retinal exudation, extravasation and pigment deposit.

The retina bulged forward and tremulous is an indication of serous exudation between the choroid and it on the one hand, and dissolution of the vitreous humor on the other. In such cases the retina has appeared, sometimes, otherwise unchanged, sometimes degenerated.

Inflammation of the lenses of the eye.

These bodies being, like the cornea, non-vascular in the fully developed state, inflammation of them consists at first merely in exudation into or on them; the vascular congestion having its seat in adjacent parts.

Inflammation of the crystalline body.—Inflammation of the crystalline body is first evidenced by opacity of the capsule, resulting from exudation into or on it. In the exuded matter, new vessels may be developed. But where is the seat of the primary congestion? This appears to be different according as it is the anterior or the posterior wall of the capsule which is affected.

In uveitis, p. 101, the anterior wall of the capsule has often exuded matter deposited on it, in which new vessels are sometimes developed. This is the kind of case described as inflammation of the anterior wall of the capsule.

Whilst inflammation of the anterior wall of the capsule belongs to the head of inflammation of the anterior segment of the eye, what has been viewed as inflammation of the posterior wall of the capsule comes under the head of inflammation of the posterior segment.

When the capsule of the lens is affected, as above described, the lens itself becomes more or less altered in consequence,—opaque, dissolved, or even the seat of suppuration.

Healing process in the crystalline body.—Wounds of the crystalline body, it is well known, are, in the human eye, followed by opacity of the lens, which is eventually dissolved and absorbed.

As to the capsule it is very apt to become opaque, but is never absorbed like the lens. If small, a wound of the capsule may heal, in which case absorption of the lens will not go on though it may have become opaque.

Inflammation of the vitreous body.—The inflammatory changes of the vitreous body, such as deep-seated extravasations of blood, deposits of lymph, appear principally to depend on congestion of the retinal vessels. From Donders and Van Trigt's observations by means of the ophthalmoscope, however, it would appear that affection of the vitreous body is sometimes independent of, at other times proceeds, *pari passu*, with, affection of the retina and choroid. On the other hand, the retina and choroid may have undergone change of structure from chronic inflammation without any opacity of the vitreous having taken place.

Increased or suppressed lacrymation, increased or diminished Meibomian secretion, are objective phenomena, sympathetic with inflammation of different tissues of the eye.

The subjective phenomena of inflammation of the different structures of the eye come now to be considered. In entering on this part of the subject, it is, in the first place, necessary to distinguish between the morbid sensations depending on perversion of common sensibility and those depending on perversion of special sensibility.

Morbid sensations depending on perversion of common sensibility, accompanying inflammation of the different tissues.

Conjunctiva.—Like other mucous membranes close to the natural apertures of the body, the conjunctiva is endowed with a high degree of common sensibility; but being loose in texture, the pain which attends inflammation of it is not very severe. There is, however, considerable heat.

The most characteristic pain is like that produced by a foreign body in the eye—a sensation which attends inflammation of other mucous membranes near the surface of the body. The sensation as if a foreign body were in the eye is owing to enlargement of the vessels on the one hand, and to increased sensibility of the coujunctiva on the other.

Attendant on inflammation of the conjunctiva there are also itchiness and smarting at the edges of the eyelids, with occasional stitches of pain shooting from them.

Sclerotica.—Very severe pain of a rheumatic character around the orbit, in the temples, &c., is a characteristic of sclerotic in-

flammation or congestion, owing either to accompanying congestion in the parts mentioned, or to nervous irradiation.

Cornea.—The sensation in the cornea itself is one of pressure. But as inflammation of the cornea is attended with injection of the conjunctiva and sclerotica, there may be also the sensation of a foreign body in the eye peculiar to the former, and the rheumatic pain peculiar to the latter.

Iris.—When the iris is inflamed, there is necessarily more or less sclerotic congestion, hence the sclerotic rheumatic pain which so often accompanies iritis. As to the pain within the eyeball itself, it may be accounted for as much, perhaps, by the distension to which the exterior tunics are subjected by the increased accumulation of blood and fluids in the interior of the eye, as by supposing it to be seated in the iris, which indeed does not appear to possess much sensibility.

Choroid.—The choroid itself does not appear to be endowed with any sensibility. The pain which attends inflammation of it being probably owing to the distension of the eyeball, and to attending congestion of other parts.

Retina.—The morbid sensations depending on perversion of common sensibility, which may attend inflammation of the retina, have not their seat in the retina, but are merely owing to the distension of the eyeball, and accompanying congestion of other parts.

Morbid sensations depending on perversion of the special sensibility of the retina.

When nervous structures endowed with special sensation are irritated, the sensation produced is not pain, but various modifications of the sensation peculiar to the structure, and this whatever be the irritating agent. Thus, when the retina is in a morbidly sensible state, irritation of it by light gives rise to a dazzling glare, which is so distressing, that the patient seeks to protect the eye against light: this constitutes intolerance of light, or photophobia. But even in the dark the same dazzling glare, or various kinds of luminous spectra, may be produced by pressure, &c., and that in a degree more or less distressing, according to the morbid sensibility of the retina, and the intensity of the pressure or other irritating cause: this constitutes photopsy.

The appearance of a gauze or mist, or "a skin with veins in it," appears to be the proper subjective effect of the congestion and exudation in inflammation of the retina.

The other special morbid sensations, photopsy, a morbid sensibility to common impressions, and photophoby, occur rather as accompaniments of inflammation of other structures of the eye than

of the retina itself. Thus the morbid sensibility of the retina, on which intolerance of light depends, is an accompaniment of those acute inflammations in which the cornea is especially involved. Luminous spectra again appear to be occasioned in inflammation of the choroid, principally by the pressure on the retina, arising from the congestion and exudation. This is illustrated by the well-known effect of pressure of the point of the finger on the exterior of the eyeball.

The phenomena of inflammation, and its events, having thus been abstractedly considered, as they occur in the different textures of the eye, a comparative survey may now be taken of the modifications which those phenomena present, according to the structure affected.

Objective phenomena.—The more vascular conjunctiva, when inflamed, is redder than the less vascular sclerotica; and the non-vascular cornea is not red at all, but the congestion, and consequently the redness attending inflammation of it, are seated in adjacent parts. Redness of the cornea, itself, however, may be subsequently superadded by the development of new vessels in it. Lastly, in the colored iris, the congestion is not manifested by redness, but by a color a compound of the yellowish redness of a thin stratum of blood and the natural color of the inflamed structure.

Exudation takes place more copiously from the conjunctiva and iris than from the less vascular sclerotica, and *cæteris paribus*, the exudation is in proportion to the degree of inflammatory congestion. The exuded matter is for the most part poured out from the surfaces of the conjunctiva and iris, and there is little swelling and thickening, manifesting interstitial exudation, in comparison with the whole quantity of matter exuded; whereas in parenchymatous structures, the exuded matter being received into their interstices, exudation is manifested by more or less considerable swelling. Exudation may give rise to phlyctenulæ and pustules on the surface of the cornea,—to abrasion on that of the conjunctiva; a difference which is owing to the difference in the resistance of the epithelium investing the two surfaces. Exudation may take place into the cellular tissue underneath the conjunctiva in inflammation of that membrane, in which case the swelling forms, called *chemosis*. Lastly, in congestion of the sclerotica, there is comparatively little disposition to exudation, and when it does take place, it is often rather into the neighboring cornea than into the substance of the sclerotica itself—a peculiarity which seems to hold in the case of other fibrous structures, for example, those around joints in rheumatic gout.

From the surface of the conjunctiva, when it is the seat of intense inflammatory congestion, slight hemorrhage readily occurs; but in

less intense inflammation, extravasation of blood occurs in the form of patches of ecchymosis into the loose cellular tissue underneath the sclerotic conjunctiva. Effusion of blood may take place from the surface of the inflamed iris, analogous to the hemorrhagic exudations of inflamed serous membranes—and extravasation may also occur into its substance. But in the latter case, as also in that of extravasation into the substance of the cornea, the spots of ecchymosis are small in comparison with those which present themselves in the loose subconjunctival tissue. The readiness with which bleeding takes place from the surface of the conjunctiva, when the seat of intense congestion, is explicable by the exposure to foreign contact of its delicate superficial capillary network in a state of great distension.

A modification of the phenomena of the events of inflammation might *à priori* be presumed to occur in different structures, in consequence of that physiological difference which determines the mode of assimilation peculiar to each structure. That such a modification holds to a certain extent only, and is readily broken through by modifying influences, is shown by the formation of pus in very different structures, and by the circumstance, that a kind of cellular tissue and bloodvessels are the new structures most commonly regenerated, whatever the original structure may be.

An influence which manifestly modifies the manner in which the exuded matter is disposed of, consists in the exposure or non-exposure of it to the contact of foreign bodies, including the external air. The matter exuded on the surface of the conjunctiva in contact with the external air, tends to be converted into pus or puriform matter, whilst that exuded on the surface of the iris out of contact with air, is more disposed to be converted into tissue, forming bands of adhesion.

The mode in which exposure to the contact of foreign bodies operates in determining suppuration, is probably by their irritation keeping up the congestion, and thus causing exudation in large quantity and of a certain quality. In the cases in which the exuded matter is converted into pus, though not in contact with foreign bodies, the exuded matter has been deposited in large quantity, in consequence of the greatness of the congestion from other causes.

In the cornea, there may be observed what will perhaps be admitted as an exemplification of the influence of comparative quantity of exuded matter, in the disposal of it. When exudation takes place slowly and in small quantity, it is developed into tissues; but when exudation takes place rapidly and in large quantity, suppuration results.

The disposition of the iris to form adhesions with the capsule of

the lens, as in the case of serous surfaces, presents a remarkable contrast to the indisposition, which, in common with other mucous surfaces, those of the inflamed conjunctiva have to adhere, even when in close apposition, except when abraded, and therefore no longer mucous surfaces. This appears to point to some peculiarity in the matter, considered as a blastema, exuded from mucous surfaces. Sometimes, indeed, the matter exuded on mucous surfaces presents itself in the form of pseudo-membranes; these, however, do not become organized, like the pseudo-membranes of serous surfaces, but are eventually separated and thrown off like dead parts.

In regard to the formation of adhesions between the iris and capsule of the lens (*synechia posterior*), it has been contended, that the condition for their formation is not exudation of plastic lymph from an inflamed iris alone, but that the capsule, as well as the iris, must be in a state of inflammation at the same time.

However this may be as regards serous membranes generally, it is to be observed of the case under notice, that since inflammation of the anterior wall of the capsule of the lens consists at first merely in exudation into or on it, the exuded matter having its source in congestion of neighboring parts, there can scarcely be any difference whether the lymph is exuded from the pupillary margin of the iris, or from the same source as in those cases which are considered to come properly under the head of anterior capsulitis (p. 102). It must be admitted, that synechia posterior occurs in cases in which it would be rather too much to say, that in addition to the iritis, there was anterior capsulitis also.

On the other hand, there is great indisposition to the formation of synechia anterior, even when the corresponding surfaces of both iris and cornea are inflamed and in contact, except when there is abrasion of the corneal surface.

Of the different structures of the eye, the cornea is that most prone to mortification and ulceration, though perhaps the changes which sometimes take place in the lens and vitreous body might properly be referred to this head.

Subjective phenomena. — The most striking modification of these, perhaps, is the difference of pain. Thus the pain which attends inflammation of the conjunctiva is like that produced by a foreign body in the eye, whilst the pain in inflammatory congestion of the sclerotica is of a rheumatic character, and seated around the orbit, in the temples, &c. Dimness of vision attends inflammation of the retina. The various morbid visual sensations are the result of the pressure, irritation, &c., to which the retina is subjected in inflammation of other structures of the eye.

CAUSES OF OPHTHALMIC INFLAMMATION.

The practical advantage of being acquainted with the causes of ophthalmic inflammation is to know how to avoid them, and thus to prevent the inflammation, or, if they have already produced inflammation, to know how to remove them if still in operation and removable.

The causes of ophthalmic inflammation may be referred to three heads, viz.: 1st. Those which operate directly on the eyes. 2d. Diseases of other parts with which the eyes sympathize, or which spread to the eyes. 3d. States of constitution and constitutional diseases, which, though they do not necessarily determine inflammation of the eyes, at least predispose them to be affected by other causes, and modify inflammations thereby excited.

To the first head belong:—Direct injuries—direct influence of cold—the direct action of very strong light, or of this and strong heat together—the irritation of reflected light—over-exertion of the sight, especially in bad light, either too weak or too strong, with much stooping of the head—the direct influence of acrid vapors—epidemic or endemic influences—the direct application of contagious matters. These are all exciting causes; but some of them require to be assisted by other causes, so that they operate partly as predisposing causes also.[1]

To the second head belong diseases of the skin, especially the exanthematous diseases.

To the third head belong the scrofulous, rheumatic or gouty diathesis, and constitutional syphilis.

Under the influence of these causes, different forms of ophthalmic inflammation are produced.

The influence of the exciting cause in modifying inflammation, appears to consist, sometimes in merely determining inflammation in a particular tissue, as when exposure to cold causes a catarrhal ophthalmia; sometimes, also in the circumstance, that the exciting cause exerts a specific action, as in the case of the primary operation of the syphilitic or variolous poison.

The influence of the state of the constitution or of constitutional disease, appears to consist in modifying the action of the exciting cause, as regards its effect in determining inflammation in a particular tissue, at the same time that it may impart peculiar charac-

[1] When the eyes are much exposed to irritating vapors, inflammation, usually of the conjunctiva, is excited and kept up. In like manner, the nitrate of silver ointment, nitrate of silver in substance, bluestone, and the like, when too frequently repeated, aggravate the ophthalmia, against which they are used, and render it obstinately chronic. In such cases, we find the conjunctiva thickened, cuticular, and shrunk. The contraction, telling very much upon the looseness of the folds of the conjunctiva at the upper and lower palpebral sinuses, great restriction in the movements of the eyeball at the same time results.

ters to the inflammation,—thus, in particular states of constitution, exposure to cold will determine phlyctenular rather than simple catarrhal ophthalmia; or in a constitution tainted with syphilis, for example, it will determine parenchymatous iritis rather than any other form of ophthalmic inflammation.

It would, however, be endless, if not impossible, to trace the innumerable combinations of influences modifying inflammation.

TREATMENT OF OPHTHALMIC INFLAMMATION.

In consequence of the peculiarity of the structure and functions of the eye, its usefulness is apt to be interfered with by such effects of inflammation as in most other organs would be of little or no moment. Hence, though the treatment of ophthalmic inflammation must be conducted on the same general principles as that of inflammation of any other part of the body, it is necessary, *cæteris paribus* to push it with more activity, and at the same time to attend to numerous special details. Thus in iritis, bloodletting and mercurialization require to be pushed to a greater extent than might in another organ be thought advisable for the same kind and degree of inflammation. But supposing bloodletting and mercurialization thus pushed have been successful in subduing the inflammation, the neglect of such details as the application of belladonna to keep the pupil dilated, may have allowed it to become closed, or the lens spotted over with depositions of lymph, in which case vision will be lost or greatly impaired.

In the treatment of ophthalmic inflammation, the first points to be attended to (besides, as a matter of course, the removal of the exciting cause, if still in operation and removable), are the protection of the eyes from everything which can cause or keep up irritation—such as using them or exposing them to strong light—and the avoidance of whatever is calculated to operate injuriously on the system in general, such as exposure to the weather, corporeal exertion, errors of diet, &c.

When ophthalmic inflammation is sympathetically connected with disease of some other organ, as the exanthematous ophthalmiæ are with the inflammation of the skin, or symptomatically connected with some general diathesis, as scrofula, or disease, as syphilis, the treatment of the ophthalmic inflammation ought not to be delayed until the removal of the disease with which it is sympathetic, or of which it is symptomatic.

It is true that the local disease cannot always be cured or alleviated until the removal of the general disease, and that the removal of the general disease will, of itself, often determine the

subsidence of the local. This, however, ought not to prevent us from at least attempting to relieve the eyes as quickly as possible.

For the cure of ophthalmic inflammation, as for that of inflammation generally, different plans of treatment are required according to the structure or structures affected, the degree and stage of the inflammation, &c.

The treatment of ophthalmic inflammation is divided into general and local, of each of which there are two principal plans. The two principal plans of general treatment are—the antiphlogistic, properly so called, including mercurialization—and the tonic and alterative. These two plans may be variously modified and combined, according to the circumstances of the case. The two principal plans of local treatment are—the antiphlogistic and soothing, —and the irritating or stimulant. These again may be variously modified or even alternately employed according to the circumstances of the case.

General.—a. Antiphlogistic treatment.

General bleeding.—This is often required in acute ophthalmia, whether external or internal, but especially the latter. Incompressibility of pulse, hot skin, and white tongue, are the general indications of the propriety of bleeding. The objective and subjective states of the eye will often of themselves furnish indications, irrespective of those just mentioned. Circumorbital pain, for example, is a good indication; for when an ophthalmia is attended by it, venesection in general soon gives relief and promotes the operation of other remedies.

It is to be remarked that when circumorbital pain is severe, and has already continued some time, there may be a state of depression. This, however, ought not to forbid the abstraction of blood; on the contrary, venesection, by relieving the pain, removes the state of apparent depression.

The quantity of blood abstracted must depend on the nature of the inflammation and the strength of the patient—from ten to twenty ounces may in general be safely taken. Nor need a repetition of the abstraction of the same quantity be dreaded. In severe inflammation, the system in general tolerates a greater abstraction of blood as it does larger doses of tartar emetic, &c. Arteriotomy does not appear to have any advantage over venesection.

Cupping, a sort of mean between venesection and leeches, may sometimes be employed to supersede venesection, but, in general, cupping is more applicable in chronic internal ophthalmia—cases in which the tonic and alterative plan of treatment is indicated.

In acute internal inflammation, by trusting to cupping, the system may be drained of blood without any advantage to the eye; but, on the contrary, the cure will be protracted, and the organ left

weak and relaxed, so that the vessels will be for a long time liable to become congested from the slightest cause.

Mercurialization.—In the internal ophthalmiæ, mercury is an indispensable remedy. In acute iritis, for example, when the system is brought under the influence of mercury, the inflammation is in general observed to abate, and as this abatement goes on, the effused lymph becomes absorbed. The operation of the mercury is promoted by combination with opium, and by the preceding venesection.

The action of mercury is commonly described as simply sorbefacient; but it appears to be sorbefacient merely because it subdues the inflammation, which has caused the exudation or the congestion which prevents the absorption.

Mercury is both antiphlogistic and tonic, contrastimulant, or hyposthenisant, as the Italian therapeutists affirm; but how does it act—primarily on the organic contractile fibre, or primarily on the blood, or on both at the same time?

Turpentine has been employed with considerable success in iritis and some forms of corneitis, but it is not so certain a remedy as mercury. Combined with cod-liver oil, I have found it very beneficial in scrofulous corneitis. [It is equally so in scrofulous iritis.]

Emetics, purgatives, diaphoretics.—The antiphlogistic powers of tartar emetic are not, perhaps, so strikingly displayed in ophthalmic as in pulmonary inflammation; considerable advantage is, however, often obtained from it. The treatment of the phlyctenular ophthalmia of children, for example, is often very materially assisted by tartar emetic, first in emetic, and afterwards in nauseating doses.

As regards the use of purgatives in ophthalmic inflammation, it is to be observed, that it is sometimes only after a free action on the bowels that a decided abatement of the inflammation takes place.

In general, however, it may be said, that emetics and purgatives are not to be trusted to as a principal means of cure in ophthalmic inflammation. This is still more applicable to diaphoretics.

Nitre is a favorite remedy in inflammation generally. It has been highly recommended in ophthalmic inflammation, sometimes even, in preference to mercury and tartar emetic; not affecting the gums like the former, nor causing vomiting like the latter.

Belladonna.—This is a most important medicine in the treatment of ophthalmic inflammation. It is employed to keep the iris contracted in iritis, and thus to oppose the tendency to closure of the pupil, and thereby to prevent depositions of lymph on the middle part of the anterior capsule and synechia posterior. Against intolerance of light, and especially that which is so distressing a symptom in phlyctenular ophthalmia, it sometimes acts like a charm.

But besides these effects, belladonna appears to exert an influence in subduing the inflammation itself. Indeed, in respect of antiphlogistic powers, the Italian therapeutists have compared it to bleeding, tartar emetic, &c.

β. Tonic and alterative treatment.

Tonics are of extensive use in ophthalmic inflammation—sometimes to promote convalescence, after inflammation has been subdued by depletion and mercurialization—sometimes even in the height of the inflammation; thus in the scrofulous ophthalmiæ, quina has been shown by Dr. Mackenzie to be scarcely less efficacious than mercury is in iritis. Cod-liver oil, iron, zinc, and the mineral acids, are also useful in various cases, complicated with anæmia, dyspepsia, &c.

In chronic internal ophthalmia, mercury as an alterative, given in conjunction or not with sarsaparilla, quina, &c., is a most useful remedy—also iodide of potassium.

Local.—a. Antiphlogistic and soothing treatment.

Local bleeding—Leeches.—Though in acute internal ophthalmia, leeches are inadequate to produce a very decided effect, they may often be usefully made to follow up venesection. Leeches alone are applicable in ordinary cases of conjunctiva, corneitis, &c.

Scarification is very beneficial when the vessels of the palpebral conjunctiva are much gorged with blood, as in the purulent ophthalmiæ. When chemosis is present, incisions are made in the elevated conjunctiva, as above directed (p. 78); partly for the sake of relieving tension and partly for the abstraction of blood.

Evacuation of the aqueous humor.—This has been recommended as a remedy in ophthalmic inflammation. It operates by relieving distension of the eyeball from increased accumulation of aqueous humor—a state attended by suffusion of the cornea, and the cause at once of considerable distress, and of a continuance of the inflammatory action. The practice is certainly sometimes advantageous, but the aggregate results have been on the whole not very favorable; moreover, the operation is too nice a one to warrant its adoption, except on particular occasions (see p. 83.)

Counter-irritation is of much use in ophthalmic inflammation, after the acute symptoms have been subdued, and in chronic inflammations.

Cold and warm applications.—The cases in which cold applications are adapted, are conjunctivitis in its earlier stages, and in-

juries of the eye, in order to ward off or moderate the traumatic inflammation. In most other cases of ophthalmic inflammation, warm applications are preferable. But it is to be observed, that the choice of cold or warm applications may be in general best determined by the feelings of the patient. [He frequently does better without either.]

β. Irritating applications.

It may be laid down as an axiom, that (to use the words of Dr. Mackenzie) in the internal ophthalmiæ, and especially in the acute stage, the application of stimulants is useless or destructive; while in conjunctival inflammations, more is effected by their means than by almost any other kind of remedy. Indeed, the plan of treatment adopted for acute iritis, if trusted to in severe conjunctivitis, would expose the eye to almost certain destruction.

But in regard even to conjunctival inflammations, it is to be observed, that as they are frequently dependent on the state of the constitution, or on an affection of some other organ, he who in treating them should direct his attention exclusively to the eye affected, might often exhaust his whole ophthalmic formulary in vain. On the other hand, however, it is not to be denied, that in many cases the inflammation is either purely local, or though connected with constitutional causes, can have its cure effected only by local treatment. This must not be overlooked; for though it has been more usually the error to treat ophthalmic inflammations as mere local affections, still some practitioners have run into the opposite extreme of neglecting local treatment entirely.

In regard to the mode of action of irritating applications in conjunctival inflammation, I have elsewhere[1] observed as follows:

"We have above seen reason to conjecture that inflammation of the conjunctiva, for example, from cold or from the irritation of a foreign particle in the eye, commences by constriction of the small arteries, which allows of the blood-corpuscles to accumulate in the capillaries and venous radicles. That in such a case, resolution is owing to dilatation of the arteries and coincident acceleration of the flow of blood, we have above seen equal reason to conjecture. Nay, we have above shown, by experiment on the frog, that dilatation of the arteries, and the coincident acceleration of the flow of blood, are the first steps to resolution of inflammation,—an experiment, let it be repeated, which is an interesting illustration of the *modus operandi* of stimulating collyria, applied to the eye for the cure of catarrhal ophthalmia."

[1] Guy's Hospital Reports, October, 1850.

Section III.—The Ophthalmiæ.

Ophthalmic inflammations, considered as a class, may be divided into four orders, viz.:

I. Ophthalmia externa.
II. Ophthalmia interna anterior.
III. Ophthalmia interna posterior.
IV. Panophthalmitis.

The genera of these orders are distinguished and designated according to the particular structure which is the chief seat of the inflammation—I say the chief seat, for the inflammation is seldom confined altogether to a single structure.

Ophthalmia externa thus comprehends, according as the conjunctiva, sclerotica, or cornea is the chief seat of the inflammation, the genera

Conjunctivitis.
Sclerotitis.
Corneitis.

Ophthalmia interna anterior, on the same principle, comprehends the genera

Aquo-capsulitis.
Iritis.
Crystallino-capsulitis anterior.

Ophthalmia interna posterior, again, comprehends the genera

Choroiditis.
Retinitis.
Vitreo-capsulitis.
Crystallino-capsulitis posterior.

Panophthalmitis is both order and genus.

The circumstances which principally distinguish and give name to the species and varieties of the ophthalmiæ, are—1, the particular part affected of the structure which is the chief seat of the inflammation—2, the structures which are co-affected—3, the nature of the exciting cause—4, the state of the constitution, or the constitutional disease by which the inflammation appears to be modified—5, the nature of the event of the inflammation.

Cases of ophthalmia are of constant occurrence in which there have been repeated attacks of inflammation throughout a series of

years, and of which the result consists in various changes of structure and affections of sight, but of which cases, the phenomena, objective and subjective, are such that they can scarcely be referred to any particular heading.

Order I.—ophthalmia externa.

The order of ophthalmia externa comprehends the genera conjunctivitis, sclerotitis, and corneitis. Each of these, as has been shown, may be more or less complicated with some degree of the other; but when the conjunctiva and sclerotica, or conjunctiva and cornea, or the conjunctiva, sclerotica, and cornea, are equally affected at the same time, then the case must be considered as coming under the head of a fourth genus, viz., compound external ophthalmia.

Genus I.—conjunctivitis.

The species of conjunctival ophthalmia are:—*pustular, catarrhal,* the different forms of *purulent ophthalmia*—viz., *Egyptian, gonorrhœal, ophthalmia neonatorum*—to which may be added the ophthalmia sometimes met with in female children in connection with puromucous vaginal discharge,—and *erysipelatous ophthalmia.*

Pustular ophthalmia.

This name is confined to the cases in which the pustules are situated on the sclerotic conjunctiva—a tenth or a twentieth of an inch from the margin of the cornea, or close to the margin of the cornea, but not on the cornea.

Objective symptoms.—To the objective description of pustular inflammation of the conjunctiva above given (p. 87), all that requires to be added here is, that the cornea is quite clear—that there is no decided lacrymation, though a flow of tears is readily excited by the movements of the eye—and that there is, with congestion of the palpebral conjunctiva, an increased Meibomian discharge, sufficient, perhaps, to cause gluing together of the eyelashes over night.

Subjective symptoms.—There is not the slightest intolerance of light, or perhaps any other local inconvenience, except a sensation like that from a foreign body in the eye, which is excited by the pustule and its enlarged vessels. It is not, however, distressing, in consequence of the general sensibility of the conjunctiva not being exalted.

Constitutional symptoms.—There is little or no constitutional disturbance.

When pustules present themselves close to the margin of the cornea (p. 87), the subjective symptoms may be as slight as above described; but the case in which this occurs is apt to pass into, if it is not already, one of scrofulo-catarrhal, or of phlyctenular corneitis, or common scrofulous ophthalmia, which is attended with great intolerance of light and lacrymation.

Causes.—Pustular ophthalmia occurs in children and young adults, especially females. It is usually excited by exposure of the eye to a draught of air. In a little boy, for example, it was brought on by looking through the keyhole of a door and receiving on the eye the current of air passing through.

Diagnosis and prognosis.—Practically, it is of importance not to confound pustular ophthalmia with phlyctenular. In the former, the application, two or three times repeated, of some irritating collyrium, will seldom fail to cure; whereas in the latter, the curability is entirely different. Seeing that when the pustules are at the margin of the cornea, the case is apt to be mixed up with phlyctenular ophthalmia, the curability is under such circumstances modified. The combination with catarrhal or scrofulo-catarrhal ophthalmia, has not so great a modifying influence.

Treatment.—Any application, such as the nitrate of silver drops (p. 71), or red precipitate salve (p. 72), &c., applied to the eye, at intervals of a day or two, will in general suffice for the cure. The vascular congestion speedily disappears, and *pari passu*, healing of the abrasion left by the pustule takes place. All the general treatment that may be necessary, is a dose of hydrargyrum cum creta, followed by a purgative and afterwards a tonic.

The above treatment is applicable, though not so rapidly effectual, when pustular is combined with catarrhal or scrofulo-catarrhal ophthalmia. When pustular is complicated with phlyctenular ophthalmia, the treatment is that applicable to the latter.

Catarrhal ophthalmia.[1]

Catarrhal ophthalmia is usually considered the type of conjunctival inflammation; for it is the form which inflammation of the conjunctiva, excited by other causes besides atmospheric influence —injury, for example—is most prone to assume.

Objective symptoms.—The eyelids are somewhat red and swollen, especially at their edges—the upper eyelid may be so much swollen as to overlap the edge of the lower. The white of the eye is bloodshot, and on examination, this is found to be owing to the reticular vascular injection above described, as characteristic of inflammatory congestion in the conjunctiva (p. 88). Besides the vascular injection, there are sometimes interspersed spots of ecchymosis (p. 89).

[1] Blepharophthalmo-conjunctivitis catarrhalis.—Ophthalmia purulenta mitior.

On everting the lower eyelid, it is seen, that towards the palpebral sinus, the redness of the sclerotic conjunctiva is more intense, and that the palpebral conjunctiva, at the same time that it is very red, is thickened and velvety-looking. The semilunar fold and lacrymal caruncle are red and swollen.

In the severer cases, in which the vascular injection of the sclerotic conjunctiva extends to the very margin of the cornea, there may be some degree of chemotic elevation of the conjunctiva, especially at the lower margin of the cornea.

The cornea may remain quite clear, and the color and activity of the iris unchanged.

There is at first watering of the eye, the result, partly, of the serous exudation from the conjunctiva, above mentioned (p. 88), but by-and-by a puromuculent discharge takes place. The matter accumulates in greater or less quantity at the inner corner of the eye, and in flakes in the palpebral sinuses. Films of this matter getting on the surface of the cornea every now and then, occasion transitory dimness and iridescence of vision. The eyelashes, also, are besmeared with the secretion; but another source of the matter, which is found incrusting them, and gluing the eyelids together over night, is the secretion of the Meibomian glands, which is poured out in increased quantity.

The watering of the eye at the commencement, as has been hinted, does not appear to be wholly the result of lacrymation, but partly of serous exudation from the congested vessels of the conjunctiva. A flood of tears, however, occasionally takes place.

Subjective symptoms.—Itchiness and smarting at the borders and angles of the eyelids, heat, and the sensation as if a foreign body were in the eye, are the subjective symptoms which usually usher in an attack of catarrhal ophthalmia.

There is not much intolerance of light, though there is a greater or less desire to shade the eye, and a feeling of weakness of it. The eyelids feel stiff, heavy, and tense. When the upper overlaps the lower, a very disagreeable sensation is experienced.

The discharge of tears, which occasionally takes place, is followed by temporary relief; and when the puromuculent secretion is established, the itchiness and smarting of the edges of the eyelids, and the sensation as if a foreign body were in the eye, are relieved.

There may be pain across the forehead, and in the region of the frontal and maxillary sinuses, but there is no pain like rheumatism around the orbit nor in the temples.

An exacerbation of the symptoms takes place towards evening; but the sensation as if a foreign body were in the eye, is felt much on first moving the eye in the morning.

Constitutional symptoms.—In general, there is not much or any constitutional disturbance; but the patient may be at the same time affected with a general catarrh.

The following is a good example of a case of catarrhal ophthalmia:

A. B., æt. 26. One day, about noon, felt a tickling in the eye, which gradually increased until it passed into severe pain, as if sand were in the eye. Towards midnight the distress became very great, entirely preventing sleep. Next day when the patient applied for advice, I found on examination great vascular injection of both palpebral and ocular conjunctiva, with patches of ecchymosis in the latter. Cornea quite clear. Iris and pupil natural. Little or no intolerance of light. Some lacrymation. Pain across the forehead, but none in the temples. Bowels confined. Laboring under general catarrh.

Predisposing causes.—The patient may be of any age, of either sex, and otherwise healthy; but it is often the case that he has been for some time out of health, or has been over-exerting the eyes.

Exciting causes.—This form of inflammation, though conventionally called catarrhal, may be excited, as above mentioned, by irritation or injury of the conjunctiva. It is in the majority of instances, however, excited by atmospheric influence. In this case it may occur epidemically. In some places it is so common, that it might be considered endemic. Under these circumstances, it is usually of a very severe form, partaking more of the characters of Egyptian ophthalmia in its milder degrees—like which, also, it sometimes appears to spread by contagion.

Very generally both eyes are affected, but one is usually more so than the other.

Diagnosis.—Simple catarrhal is, in general, distinguished from the other forms of puromucous ophthalmia, in not presenting such a degree of redness and swelling of conjunctiva, copiousness of the puriform discharge, nor swelling of the eyelids, and by the circumstances under which it occurs.

The ophthalmiæ from which catarrhal conjunctivitis requires to be principally distinguished, are phlyctenular and catarrho-rheumatic,[1] the former occurring in young persons, the latter in adults.

In phlyctenular ophthalmia, the conjunctival vessels which are injected are few in number, and ramify singly or in detached fasciculi towards the conjunctival circumcorneal network, which may be completely or partially injected. There is also some sclerotic circumcorneal injection. The general expression of the redness in

[1] Catarrhal ophthalmia is not likely to be confounded with rheumatic ophthalmia or sclerotitis. The difference in the seat and character of the vascular injection has been above pointed out (pp. 52, 91,) and the difference in the accompanying pain (pp. 63, 103).

phlyctenular ophthalmia is thus, different from what obtains in catarrhal ophthalmia, a faint blush on one side or all round the cornea, shaded off towards the circumference of the eyeball, together with a fasciculus of vessels, perhaps, proceeding to some point on the cornea where there is an ulcer.

In phlyctenular ophthalmia, the cornea, which is the essential seat of the disease, early becomes suffused, or presents phlyctenulæ, which, bursting, leave ulcers. In catarrhal ophthalmia, although ulceration of the cornea may eventually take place, the cornea is quite unaffected at first.

In phlyctenular ophthalmia there may be little or no increase of the Meibomian secretion, or of the mucous secretion of the conjunctiva, which are such prominent characters in catarrhal ophthalmia. But in phlyctenular ophthalmia there is great lacrymation and intolerance of light; whereas in catarrhal ophthalmia, these symptoms are slight or altogether absent.

But it is to be remarked, that phlyctenular and catarrhal ophthalmiæ may occur in combination, constituting scrofulo-catarrhal ophthalmia. Catarrhal may also occur in combination with pustular ophthalmia. Cases even occur of a combination of catarrhal, pustular, and phlyctenular ophthalmiæ.

The differences between catarrhal and catarrho-rheumatic ophthalmiæ are:—In catarrhal ophthalmia, there is simply conjunctival injection—in catarrho-rheumatic, both conjunctival and sclerotic. Hence, while in catarrhal ophthalmia, the sclerotic is observed white under the vascular network of the conjunctiva, it is pink in catarrho-rheumatic ophthalmia.

While in catarrhal ophthalmia, unless severe and of long continuance, the cornea is clear, and the color and motions of the iris natural, in catarrho-rheumatic ophthalmia, the cornea appears muddy, and not unfrequently presents a phlyctenula or ulcer, and the iris is discolored, and pupil sluggish. There is considerable intolerance of light in catarrho-rheumatic ophthalmia; and instead of the pain across the forehead, or in the frontal sinuses, which may exist in catarrhal ophthalmia, there is more or less severe circumorbital or temporal pain, aggravated when the patient is warm in bed.

Prognosis.—Catarrhal ophthalmia, in its simpler forms, is in general readily subdued; and that in a week or a fortnight. In its severer forms, if neglected or improperly treated, ulceration of the cornea may take place, and, above all, the palpebral conjunctiva is extremely apt to be left in a state of chronic inflammation —itself thickened, and its papillæ enlarged—a state which keeps up irritation of the eye, and which may lead to vascularity and opacity of the conjunctiva corneæ. In this, as also in the other

puromucous ophthalmiæ, entropium and ectropium are not unfrequent results.

Treatment.—In the simpler forms of this ophthalmia, if the case is seen at the very commencement, an attempt should be made to subdue the inflammation by soothing treatment. For this purpose, rest, quiet, and restricted diet should be enjoined, and a purgative of calomel and jalap, for example, prescribed; or an emeto-cathartic, especially if there is more than usual sensibility to the light—two grains of tartar emetic, and an ounce of Epsom salts, may be dissolved in half a pint of water, and two or three table-spoonfuls of the solution taken every half hour until vomiting; after which the same dose every four or six hours only.

As applications to the eye, lotions of tepid water three or four times a day, or, if more agreeable, the continued application of cold. The continued application of cold lotions, however, it is to be remarked, is apt, in middle-aged persons particularly, to excite sclerotic inflammation, and thus convert a catarrhal into a catarrhal rheumatic ophthalmia. As an occasional application, cold water is not well adapted. When used as such, an uncomfortable sensation of heat in the eye is felt soon after; whereas, when tepid water has been used, the eye for a time feels pleasantly cool. At bed-time the borders of the eyelids are to be anointed with simple ointment [or fresh cold-drawn castor oil].

Under this soothing treatment, the inflammation will sometimes subside without anything further being necessary; but if resolution does not begin to take place within twenty-four hours or so, irritating collyria will require to be used. The nitrate of silver solution for example, may be dropped into the eye every other day, and the alum, bichloride of mercury, or lapis divinus lotion, without addition of vinum opii (p. 69), used tepid, to bathe the eye three times a day. At bed-time the borders of the eyelids may be anointed with the weak red precipitate salve (p. 72).

If, notwithstanding this treatment, the inflammation persists, it will be proper to apply leeches—about six round the eye, or each eye, if both be affected. [Say from two to five dozen of American leeches to the temples—from four to ten fluid ounces of blood.]

In the severer forms of the complaint, blood should be at once abstracted, either by leeches as above, or if the patient be robust, by venesection, followed up, if necessary, by leeches. This treatment will save much subsequent inconvenience from a thickened state of the palpebral conjunctiva. After the bleeding, a pediluvium, and some diaphoretic, such as Dover's powder at bed-time, are to be prescribed, and a purgative draught in the morning. Locally, the same treatment as above indicated. [Care should be taken in these and all other cases to keep the head and shoulders well

elevated, to avoid all constricting and heating head-dresses, or caps, bands, handkerchiefs, shades or other similar appliances, and to abstain from frequent slopping of the eyes with lotions.]

As the inflammation remits, the redness of the sclerotic conjunctiva becomes less and less until it has quite disappeared; but though this has taken place, considerable congestion may still be presented by the palpebral conjunctiva, with enlargement of its papillæ. If this state of the palpebral conjunctiva continue obstinate, blisters behind the ears, scarification of the palpebral conjunctiva, and the pencilling of it with the strong red precipitate ointment, will be useful. When the palpebral conjunctiva is merely left relaxed and thickened, pencilling it a few times, at intervals of two or three days, with vinum opii, pure, or diluted with one or two waters, or with the lapis divinus drops, will do good. A return to generous diet, and the use of tonics, are at the same time to be enjoined.

Egyptian ophthalmia.[1]

This is the disease of the eyes which so severely affected the English and French troops in Egypt, and also after their return thence, and which has since raged in the armies of almost all the states of Europe.

The palpebral conjunctiva and semilunar fold are especially the focus of the disease; being the parts which are from the first, and continue to the last affected, whatever other parts may be also involved. But though the inflammation may thus remain almost entirely confined to the palpebral conjunctiva, it is peculiarly disposed to extend, and that with great violence, to the ocular conjunctiva, and even to the proper tunics of the eyeball itself. On this extension of the inflammation, depends the rapid destructiveness to the eye, which has so lamentably characterized the disease.

Different degrees of the ophthalmia—a first, a second, and a third degree—are accordingly recognized.

In the first degree, the inflammation is still in a great measure confined to the palpebral conjunctiva and semilunar fold; and, though there is some puromucous secretion, there is no decided blennorrhœa.

In the second degree the inflammation has extended to the ocular conjunctiva, which is raised up by exudation into a chemotic ridge at the margin of the cornea—usually the lower first—and there is more or less blennorrhœa.

In the third degree, the chemosis is complete, the eyelids are enormously swollen, there is profuse discharge of mucopurulent

[1] Granular or contagious ophthalmia.—Ophthalmia purulenta gravior, &c.

matter, and the proper tunics of the eyeball are either already involved, or in imminent danger of becoming so.

The disease may not advance beyond the first degree, but become chronic, or it may at once pass into the severer degrees. In its chronic state, it is still ready, on the application of any exciting cause, to pass into the severer degrees.

The second degree may arise at once as such, or be developed from the first degree.

The second degree has a great tendency either to become chronic or to pass into the third degree, and this especially if neglected or improperly treated. The third degree, indeed, generally, if not always, arises by a sudden aggravation of all the symptoms from the milder degrees, especially the second.

The morbid development on the conjunctiva of the eyelids and palpebral sinuses of what are called *granulations*, is an early and important effect of the inflammation. The nature of these granulations has been above pointed out (pp. 89, 90).

The development of a granular state of the palpebral conjunctiva is often the result of long-continued but slight congestion—so slight as scarcely to have attracted the patient's attention. Hence it has been maintained, that the formation of granulations takes place independently of inflammation; and when, in such cases, ophthalmia declares itself in a decided form, it has been alleged to be an effect or symptom of the granular state of the palpebral conjunctiva. But this is incorrect.

Both eyes, commonly, are affected, though one may suffer more than the other. When both eyes become affected, there is often an interval of some days between their first invasion.

The lower eyelid is usually first affected, but the upper soon becomes so, and suffers more than the lower—it, indeed, remains the nest of the disease.

Local symptoms in first and second degrees.—The *first* and *second* degrees of Egyptian ophthalmia do not essentially differ in their symptoms, either objective or subjective, from the milder and severer forms of catarrhal ophthalmia, except in the granular state of the conjunctiva, which, though it does in some degree exist in inveterate cases of catarrhal ophthalmia, presents itself in Egyptian ophthalmia even from the first, and remains to the last, so that it is justly considered the peculiar characteristic of the disease.

Constitutional symptoms in first and second degrees.—In general, there is no constitutional disturbance—no fever—no loss of appetite. When such do occur, they depend rather on the idiosyncrasy of the patient than on the disease.

Objective symptoms in the third degree.—In the third degree, the eyelids, especially the upper, are very much swollen, sometimes

enormously so, tense, livid, and hot. The upper eyelid hangs down over the lower.

If an attempt be made to open the eyelids, or even when the patient makes any effort whatever, protrusion of the conjunctiva of the palpebral sinuses, and eversion of the eyelids, are apt to take place, in consequence of the swollen and sarcomatous state of the conjunctiva, as well as the effusion beneath it. The eversion of the eyelids is at first reducible, but by-and-by it may cease to be so.

The semilunar fold and lacrymal caruncle are so red and swollen, as to look like sarcomatous excrescences rather than natural structures.

The sclerotic conjunctiva, likewise red and swollen, is raised up like a wall all round the cornea, which thus appears half buried (*chemosis*). The cornea may be as yet unaffected.

After some hours, the secretion of the conjunctiva, which was sero-muculent, becomes muco-purulent, and is poured out in such quantity, that it is constantly flowing down the cheek. If the eyelids are suddenly opened, the matter bursts out in a torrent.

An oozing of blood readily takes place from the conjunctival surface.

The inflammation does not remain confined to the conjunctiva, but extends to the proper tunics of the eyeball, the sclerotica, the cornea, and even the internal tunics. When the eyelids admit of being opened, the implication of the cornea can be seen, but that of the other parts is inferred from the subjective symptoms. When the eyelids cannot be opened, and the cornea seen, something may be inferred as to the degree to which it has suffered from the state of the discharge; if ill-conditioned, there is reason to dread mischief to it.

The cornea, though it sometimes escapes immediate material injury, is the part most subject to the destructive effects of the inflammation. It becomes more or less opaque from exudation into its substance. Its conjunctival layer may become thickened, opaque, vascular, and covered with fungous excrescences,—or phlyctenulæ form, burst, and run into perforating ulceration, which is followed by prolapsus iridis. In the worst cases, the cornea becomes wholly infiltrated with exuded matter, and is rapidly and completely destroyed by ulceration, or by mortification and sloughing. Sometimes it bursts, but probably not before being thinned by ulceration. Even if it should have escaped these destructive effects, an ulcerated trench will probably be found, when the swelling of the parts subsides, at the place where it was pressed on by the chemosed conjunctiva.

Subjective symptoms in the third degree.—The severity of the subjective symptoms in this degree of the disease, is principally

owing to implication of the proper tunics of the eyeball—the sclerotica, the cornea, and even the internal tunics.

There is burning hot pain in the eyelids, aggravated by the slightest touch, deep distending pain in the eyeball, and pain around the orbit, in the temple, or all over the side of the head. There is great intolerance of light, and often photopsy.

The pain around the orbits and in the temples occurs in nocturnal paroxysms, during one of which the cornea bursts. On the bursting of the cornea, the pain immediately remits, but returns again in another form, or passes to the opposite eye.

Constitutional symptoms in the third degree.—Even in the third degree, the constitutional symptoms are not severe. In some exceptional cases, indeed, before the disease has reached its greatest height, a symptomatic inflammatory fever arises, but is, notwithstanding the severity of the local affection, very moderate, and does not continue long. In the progress of the disease, however, the patient is apt to become much sunk both in strength and spirits.

Causes.—The cause of this disease was at one time supposed to be a peculiar contagion, first imported into Europe from Egypt (hence the epithet Egyptian), by the English and French armies. It is now, however, pretty generally conceded, that the disease does not depend upon any such peculiar contagion, but that it may arise from occasional atmospherical influences, sometimes sporadically, sometimes epidemically. There are also local influences which render it endemic, in many other places besides Egypt.

In whatever way it arises, it may, under favoring circumstances, as when large bodies of people are crowded together, and especially in dark, dirty, damp, and ill-drained dwellings, become infectious. This is the explanation of its propagation in armies, schools, and prisons.

It has been supposed that propagation takes place principally by infection *per contactum;* but experience appears to show that infection *in distans* is the more common way,[1] the air being the vehicle by which the infecting principle is conveyed in the latter case, the discharge from the eye in the former.[2] The communica-

[1] Eble, Die so-genannte contagiöse oder ägyptische Augenkrankheit. Stuttgardt. 1839.

[2] Piringer (Die Blennorhoë am Menschenauge. Gratz, 1841) has made a number of attempts to reproduce the disease, by the application of matter from an affected eye, for the purpose of curing pannus, as will be explained in the proper place, and the results he has come to in regard to the contagion of the disease, are the following:—The contagion is fixed, its vehicle the muciform secretion of the conjunctiva. The mucus of the second and third degree of the disease only is absolutely infectious; as the secretion becomes thinner, it loses its infectious power. Eyes which have been already diseased, appear to be less readily infected than perfectly sound eyes. The activity of the mucus is not retained beyond the third day after its removal from the body; the reaction takes place in from six to twenty-four hours, usually at night. The degree of the disease excited by the infection, depends on the quality of the contagion. Mucus from the first degree of the disease, or thin secretion from the second and third, occasions the first degree of the disease. Secretion from the second degree of the disease excites the third degree. The application of ice-cold water, and cleansing the eye, within three minutes after the matter has been applied, prevent the operation of the infection.

tion by contact has often taken place from the use in common of towels and basins, &c.

Though the disease has prevailed in the most opposite climates, and in all seasons, still it appears that a very warm, or warm and damp climate or season, is peculiarly favorable to its development and propagation.

As causes predisposing the individual to be attacked, may be mentioned fatigue, exposure, want of cleanliness, improper food, abuse of spirituous liquors, &c. The invasion of the disease is often sudden—soldiers on guard, and numbers of persons in the course of one night becoming affected. This has no doubt been owing to atmospherical influence favoring the development of the morbid germ already under incubation.

Diagnosis.—It has been above shown that the principal difference between catarrhal ophthalmia and the milder forms of Egyptian ophthalmia, consists in the great degree in which the conjunctiva of the eyelids is affected with granulations in the latter—a morbid state, which is very inveterate, and by its presence keeps up irritation and a tendency to relapse.

The severest degree of Egyptian ophthalmia is to be distinguished from the other forms of purulent ophthalmia, gonorrhœal, for example, principally by the circumstances of the case—and by this, that in true gonorrhœal ophthalmia one eye only is usually affected, and the ocular conjunctiva is perhaps more swollen, the eyelids less so.

Prognosis in general.—When the inflammation is of an active character, and not modified by any constitutional peculiarity, early and proper treatment promises success. When the inflammation is of a torpid character, and when the constitution is scrofulous, it less readily yields to treatment, subsides less quickly and perfectly, and fixing itself in the structures of the eye, is apt to produce degeneration of it. In erethitic irritable cases, the prognosis is also unfavorable, but less so than in torpid cases.

Sporadic cases are usually of middling severity. In an epidemic, the disease is at first mild, then increases in severity, and again becomes milder towards the end. When the disease is endemic, the cases, without being of the severest character, are in general very inveterate, if neglected.

The disease arising from contagion is more dangerous than when otherwise produced.

Prognosis in the first degree.—The disease in the first degree may in general be readily subdued. If not timely and properly treated, the disease may pass at once into the severer degree, or fall into a chronic state. In this state, however, it is still ready, on the application of any exciting cause, to rise into the severer degree.

Prognosis in the second degree.—The disease in the second degree, if taken in time and properly treated, may still be cured in three or four weeks. But if the inflammation has already been going on for a week or so, even if the cornea is still unaffected, though the inflammation may be readily removed from the sclerotic conjunctiva, the palpebral conjunctiva will remain long in a thickened and granulated state.

When the disease has become fully developed before medical assistance is called for, vascularization and ulceration of the cornea may have taken place. This affection of the cornea is kept up, if not aggravated, by the morbid state of the palpebral conjunctiva; hence the prognosis is very unfavorable, as opacity and permanent vascularity of the cornea may result.

Prognosis in the third degree.—In the third degree of the disease, a perfect cure is seldom effected. If the eye is not disorganized, which it may be in 24–36 hours, by destruction of the cornea, it may be very much injured by perforating ulceration and its consequences. Besides this, the morbid state in which the conjunctiva is left is long of being recovered from, perhaps never perfectly, and is a constant source of irritation.

Treatment.—In the first degree, leeches around the eye, and opening medicine, are to be first prescribed. Then the application, once a day, of the nitrate of silver drops (p. 71), or the strong red precipitate ointment (p. 72).

In the severer degrees of the disease, if the patient be of good strength, venesection to ʒxij—xvj—xx, followed at bed-time with Dover's powder, gr. x—xx, and calomel, gr. iij—v, and a black draught [Infus. sennæ comp.] next morning. In some cases, leeches around the eye may be required to follow up the venesection, or it may be necessary to repeat the latter. [Mustard pediluvia every night.]

After the bleeding, &c., the application to the conjunctiva of strong irritants should be made, as nitrate of silver in substance, salve, or solution, or the strong red precipitate salve once a day, and the eye bathed and cleansed frequently [every three or four hours] with the tepid solution of alum, or of bichloride of mercury (p. 69).

If chemosis exists, and if the cornea appear much buried and pressed on by it, incision of the chemosed ocular conjunctiva ought to be had recourse to without delay (p. 78). Incision of the chemosed conjunctiva relieves the eyeball, and especially the cornea, from the pressure which is considered, as above mentioned (p. 97), to be one great cause of its destruction.

When the iris and other internal structures of the eyeball become affected, as is indicated by change of color of iris and contraction of pupil, provided these can be seen, and by pulsative pain in and around the eye, with inflammatory fever, the propriety of

abstraction of blood, either by venesection, cupping or leeches, will again come under consideration. It will, in any case, be proper to give calomel, gr. ij, and opium, gr. ss. every four hours, until the gums are affected, and to apply belladonna around the eye. [Tinct. Opii. and Tinct. Bellad., or Atrop. Sulph. may be added to the lotions.]

When the violence of the inflammation has subsided, it will be advantageous to improve the diet, and give tonics,—quinine or bark, especially if there be periodical pains in or around the eye. Also to make counter-irritation behind the ears or on the nape of the neck.

The special treatment of granular conjunctiva, of pannus, of ulceration of the cornea, prolapsus iridis, &c., which may present themselves as the effects of the inflammation, will be treated of under the proper heads.

Eversion of the eyelids sometimes occurs, it has been above said, in consequence of the great tumefaction of the palpebral conjunctiva (p. 123). The inflammatory œdema of the eyelids, which for a time is excessive, beginning at length to subside, while no proportionate diminution of the swelling of the lining membrane of the lids has as yet taken place, the swollen and granulated conjunctiva loses that counterpoise which the external swelling afforded it, and is forced outwards by the action of the orbicularis palpebrarum. If the protrusion is not immediately returned, the upper part of the eyelid and the retroverted cartilage act like a ligature on the protruded conjunctiva; and as the swelling increases, the stricture becomes still stronger by the natural, but ineffectual efforts of the orbicularis to bring the tarsus into its proper position.

Ophthalmia of new-born infants.

It is generally within a week after birth that this ophthalmia makes its attack. Sometimes it is observed immediately after birth, sometimes again, as late as three or four weeks.

Objective symptoms.—It is first noticed, that the infant keeps the eyes shut, that the edges of the eyelids are slightly œdematous and red, and that they are gummed together after sleep with an inspissated yellow matter, which is the Meibomian secretion increased in quantity. On softening this, and separating and everting the eyelids for examination, the palpebral conjunctiva is found red and spongy; the sclerotic conjunctiva but little injected.

In this way, first one eye, and in a day or two the other, becomes affected. The first affected generally suffers more in the course of the disease.

The swelling and redness, which were at first confined to the

[1] Ophthalmia neonatorum—Purulent ophthalmia of infants.

edges, by-and-by involve the whole eyelids, especially the upper. The palpebral conjunctiva becomes still more red, swollen, and velvety. The lacrymal caruncle and semilunar fold are red and enlarged, and the sclerotic conjunctiva is now more or less injected, even to the margin of the cornea. A whitish sero-muculent discharge is at the same time established. This will perhaps flow out in some quantity when the eye is opened for examination, having been pent up and accumulated in the conjunctival space, in consequence of the gluing together of the edges of the eyelids.

As the disease approaches its height, the swelling of the eyelids increases, and their skin becomes of a brownish-red color, tense, and shining. The upper eyelid, which is always the more swollen, overlaps the edge of the lower.

On separating the eyelids, a quantity of thick puriform matter escapes, and the conjunctiva of the palpebral sinuses, swollen and sarcomatous-looking from the engorgement of its vessels with blood, readily protrudes. Eversion of the eyelids, and protrusion of the conjunctiva of the palpebral sinuses, may take place even by the contraction of the muscles when the infant cries. The lacrymal caruncle and semilunar fold are very much enlarged, and the sclerotic conjunctiva is in the state of chemosis. In this stage of the inflammation, discharge of blood readily takes place from the conjunctival surface.

Hitherto the cornea may have continued unaffected, or at the most may have been hazy; but chemosis has usually not existed long, before it suffers more or less injury, becoming the seat of ulceration, abscess, or destructive purulent infiltration. When such mischief as this occurs, the discharge becomes ichorous, and a diminution of the swelling and tension of the eyelids takes place.

Constitutional symptoms.—As the disease proceeds, the infant becomes fretful and uneasy, does not suck, nor sleep. Its mouth is often aphthous.

Causes.—The infants, the subjects of this ophthalmia, are generally weakly, often twins, or prematurely born.

Sometimes the disease can be attributed to no other exciting cause than such as gives rise to catarrhal ophthalmia. In many cases, exposure of the eyes to heat and light, or the direct intrusion of irritants, such as the soap or spirits used in washing the infant, appears to be the exciting cause. Inoculation with leucorrhœal matter from the vagina of the mother during parturition, there is reason to believe, a very common cause. Inoculation with gonorrhœal matter is, for obvious reasons, a less frequent cause. Dr. Cederschjöld, of Stockholm, found ophthalmia neonatorum occur in 20 out of 137, or 1 in 7 infants, the mothers of whom

were affected with vaginal discharge; and in 10 out of 181, or 1 in 18, the mothers of whom were not affected.

The disease may be propagated by infection *per contactum*. Adults having had the discharge from the infant's eyes accidentally applied to theirs, purulent ophthalmia has been produced, and that so severe as to destroy the eyes.

When there is a number of infants laboring under this disease, collected together, as in lying-in and foundling hospitals, infection appears to be propagated *in distans*.

As several cases generally come under my notice at the same time, and as a considerable period often elapses before any new cases present themselves, I have been led to believe that there is something epidemic in the occurrence of this ophthalmia.

Prognosis and course.—In whatever stage of the disease the medical man be called in, he may in general pronounce a favorable prognosis, if he finds the cornea still clear, or even though hazy, still free from ulceration and abscess. If ulceration or abscess have taken place, the extent to which the cornea will be preserved clear, whether it may not be perforated and prolapsus iridis take place, and this whether to the extent of constituting the condition for the formation of partial staphyloma, can only be doubtfully prognosticated until a decided stop is put to the inflammation. The prognosis may then be regulated by the degree and extent to which the cornea has suffered (pp. 96, 97). If the cornea has become completely infiltrated with matter, it is destroyed; it will be thrown off by ulceration or sloughing, the iris will protrude, and the condition be laid for a total staphyloma.

Though the eye may have otherwise escaped, it may be left affected with central capsular cataract, strabismus, or incomplete amaurosis.

The disease yielding, the swelling of the eyelids diminishes. From being tense and shining red, the skin becomes wrinkled and pale livid. The chemosis and redness of the sclerotic conjunctiva subside; but although the swelling of the palpebral conjunctiva becomes much diminished, its redness and the enlarged state of its papillæ more slowly disappear. The purulent discharge becomes less and less. All this, and the course to a cure, proceeds rapidly if the cornea have remained unaffected; but the existence of ulceration, &c., of the cornea necessarily retards the cure of the other parts, which, in fact, proceeds only in proportion as the cornea heals.

Treatment.—The disease may be successfully treated from the first by such applications as nitrate of silver drops or ointment, or strong red precipitate ointment (pp. 71—74). These remedies

must be applied by the surgeon himself once every second day. Before the application, the eye is to be cleansed from discharge.

The nurse should use the alum, or bichloride of mercury collyrium tepid, three times a day, for bathing and cleansing the eye; and the weak red or white precipitate ointment, for anointing the edges of the eyelids, to prevent them from being glued together.

When the conjunctiva of the eyelids and sinuses is already swollen, sarcomatous-looking and gorged with blood, as it generally is before the case comes under the care of the surgeon, it is necessary to scarify it immediately before applying the strong drops or ointment. The way of doing so is this:—The infant being laid by the nurse across her lap, and the head made to rest on the surgeon's knee, he cleanses away the matter with pieces of lint; and then having everted the upper eyelid, he scarifies the protruding conjunctiva. The blood, which flows freely, he takes up with pieces of lint, which he throws away as fast as they get soaked with blood. The conjunctiva of the lower lid is next scarified in the same manner. The bleeding having ceased, the strong red precipitate ointment, previously softened, is put in between the eyelids so that it may come into contact with the whole conjunctival surface. This scarification of the palpebral conjunctiva and application of the red precipitate ointment it may be necessary to repeat several times, but only at intervals of two or three days.

Whenever the eyelids become everted, they should be immediately restored to their proper position, which is done by seizing the eyelid between the finger and thumb, drawing it a little from the eyeball, and then turning it down. Should the eversion have been allowed to continue some time, and the eyelid cannot be restored to its proper position, the everted conjunctiva is to be scarified; and when it has thus been somewhat emptied of blood, it will admit of being returned more readily.

Cleansing of the eyes by the nurse with the bichloride lotion three times a day, and thereafter the application of the weak red precipitate ointment to the edges of the eyelids are to be continued.

Small blisters behind the ear in severe cases promote the action of the preceding treatment.

Internally, a grain or two of gray powder, a little castor-oil, or rhubarb and magnesia, is to be given as occasion requires; and when the cornea is threatened, small doses of calomel and quina, gr. ¼ of the former, and gr. ss. of the latter, rubbed up with sugar, twice a day.

The diet of the nurse is to be carefully regulated. During the height of the disease it may be advisable for her to abstain from animal food and strong drinks; but as it declines she may take, besides animal food and wine or porter, tincture of iron.

When the puriform discharge has ceased, but the conjunctiva

continues red and relaxed, the four grain solution of nitrate of silver, or vinum opii diluted with an equal part of water, or the lapis divinus solution (p. 69), may require to be dropped into the eyes several times at intervals of two or three days.

Gonorrhœal ophthalmia.

Diagnosis—This ophthalmia resembles very much the severest form of Egyptian ophthalmia. If there is any difference, it is this:—In gonorrhœal ophthalmia, the sclerotic conjunctiva is affected from the very first, and great and inveterate chemosis rapidly forms; whereas in Egyptian ophthalmia, the sclerotic conjunctiva becomes affected subsequently to the palpebral conjunctiva, the chemosis does not form so rapidly, nor is it so inveterate. In gonorrhœal ophthalmia, though the inflammation of the palpebral conjunctiva and swelling of the eyelids may be very great, it is in general not so considerable as in Egyptian ophthalmia; and, at any rate, granulated conjunctiva is not so marked a character of gonorrhœal as of Egyptian ophthalmia.

In consequence of the greater severity of the inflammation of the sclerotic conjunctiva, the cornea is still more liable to suffer and be destroyed in gonorrhœal than in Egyptian ophthalmia. Indeed, gonorrhœal ophthalmia is one of the most rapidly destructive diseases the eye is subject to.

Males are oftener affected with this disease than females; but it is of comparatively rare occurrence in either sex. It is sometimes met with in children.

In general one eye only is affected in gonorrhœal ophthalmia; whereas in Egyptian ophthalmia, it is extremely rare to meet with a case in which the disease remains confined to one eye.

These differences, it will be observed, are not sufficiently strict to serve as a practical ground of diagnosis. The history of the disease forms the best criterion.

Cause.—Inoculation with gonorrhœal matter. The matter is sometimes accidentally applied to the eye of a healthy person through the medium of foul cloths, &c. It is in this way that children are inoculated.

Prognosis.—Until, with a cornea safe, or at least not much ulcerated, the disease is on the decline, which is known by the subsidence of the swelling of the eyelids and of the chemosis, with diminution of the discharge, the prognosis must be extremely unfavorable. The eye may be destroyed in forty-eight hours from the commencement of the disease. Even when the eyeball is not actually destroyed, it may be left atrophic and vision annihilated.

[1] Ophthalmia gonorrhoica vera.—Acute gonorrhœal inflammation of the conjunctiva.

Treatment.—The treatment must be the same as in the severest form of Egyptian ophthalmia, only, if possible, more active. No delay of treatment can be admitted. Incision of the chemosed conjunctiva should be early had recourse to.

Mild gonorrhœal ophthalmia.

A milder form of ophthalmia is met with in persons laboring under gonorrhœa, which, however, does not appear to differ from common catarrhal ophthalmia. The cases of the kind which I have seen have not appeared to me in any other way dependent on gonorrhœa, than that at the time the system was in consequence of it more susceptible to cold, the exposure to which, at the same time that it excited the ophthalmia, operated in checking the discharge from the urethra. They readily yielded to the same treatment as is above indicated for catarrhal ophthalmia.

Sometimes the inflammation presents the characters of, and requires then the treatment for, catarrho-rheumatic ophthalmia.

Puromucous ophthalmia occurring in female children, in connection with puromucous discharge from the vagina.

This ophthalmia, though sometimes severe, is usually of a mild character.

Symptoms.—In a case of two or three days' standing, the eyelids were red and swollen, but not tense, and admitted of being readily opened. The conjunctiva was red but not intensely so—the palpebral conjunctiva spongy—the sclerotic conjunctiva raised up over the lower margin of the cornea in a state of slight chemosis. The cornea was still quite clear. There was a serous discharge, mixed with considerable flakes of thick whitish-yellow matter. No pain, and little or no intolerance of light.

Treatment.—Scarification of the palpebral conjunctiva—the nitrate of silver drops once a day—the alum lotion two or three times a day for cleansing the eye—the red precipitate ointment at bed-time and some laxative medicine—check the inflammation in a few days. The healing process was then promoted by a blister behind the ear, pencilling the conjunctiva with lapis divinus drops, and the exhibition of quina.

When the chemosis subsided, superficial ulceration was discovered where the cornea had been pressed on by the fold of conjunctiva. This readily healed, leaving a slight opacity, but was the cause of retarding somewhat the recovery.

The vaginal discharge subsided under the use of a sulphate of zinc injection.

[1] Iritis, in connection with gonorrhœa, will be considered farther on, under the head of *Iritis*.

Erysipelatous ophthalmia.[1]

The conjunctiva is always more or less affected in erysipelas of the eyelids, but idiopathic erysipelatous ophthalmia is not of frequent occurrence.

Objective symptoms.—To the anatomical description of erysipelatous inflammation of the conjunctiva above given, it only remains to add under this head, that the eyelids and cheek are œdematous, that in consequence of the gravitation of the fluid or pressure of the upper eyelid, the serous chemosis is greater below than above —that the cornea appears half buried by it—that there is some puromucous secretion with occasional lacrymation and increased Meibomian discharge.

In some cases, I have found this ophthalmia and stye co-existing.

Subjective symptoms.—The patient complains of an uneasy sensation of pressure and tension about the eye when it is moved, with itching and smarting at the edge or corners of the eyelids, especially when a stye is forming, and some impatience of light.

Constitutional symptoms.—The subjects of this ophthalmia are most commonly persons of weakly constitutions, advanced in life, or laboring under gastric derangement: but these conditions are to be viewed rather as the predisposing causes than as the symptoms of the ophthalmia.

Causes.—The *predisposing causes* have been just referred to. *Exciting causes.*—Exposure to cold and wet. Injuries, chemical or mechanical, of the conjunctiva; it sometimes occurs after needle operations for cataract. In an old man affected with small irritable ulcers on his legs, with surrounding erythema, I once saw it occur as if by metastasis on the application of warm fomentations to the legs.

Diagnosis.—The nature of the conjunctival inflammation is at once perceived; but in forming the diagnosis, it should be determined whether there be any complication—such as sclerotitis.

Prognosis and course.—The prognosis is good. The disease usually begins to subside in a few days—the watery effusion is gradually absorbed—and the conjunctiva becomes again applied to the sclerotica, but continues for some time in a loose flaccid state. During this process, the injection of the conjunctiva disappears, but the spots of extravasated blood are some time of being absorbed. The lacrymal, Meibomian, and conjunctival secretions return to their natural quantity and quality.

Treatment.—Three grains of mercurial chalk, with watery extract of aloes, and extract of hyoscyamus, of each one grain at bedtime, followed by a purgative draught in the morning; and as a

[1] Conjunctivitis erysipelatosa idiopathica.

collyrium, the solution of the bichloride of mercury, with vinum opii (p. 69), will in general suffice to check the disease. Good diet, cordials, and tonics, may be afterwards given.

Instead of a lotion, some prefer dry warmth, by means of medicated bags (p. 67), hung over the eye. [We have found the best dressing of this kind, when desired, to be clean raw cotton or carded wool, particularly in neuralgic and rheumatic patients.] If more agreeable to the patient, this may be adopted; but in either case it will be necessary afterwards to drop in vinum opii to give tone to the relaxed membrane.

Genus II.—sclerotitis.

The species of this genus admitted, are rheumatic ophthalmia, and scrofulous sclerotitis.

Rheumatic Ophthalmia.[1]

In rheumatic ophthalmia, the sclerotica is the principal seat of the vascular congestion; but, as above shown (p. 119), there is usually some degree of implication of the cornea and iris in the inflammation, the former from exudation, the latter from both congestion and exudation. Rheumatic ophthalmia, considered as a pure sclerotitis, or a sclerotitis with the slight complications mentioned, is of rare occurrence, in consequence of its tendency to merge into corneitis, catarrho-rheumatic ophthalmia, aquo-capsulitis, or decided iritis.

Objective symptoms—Redness.—At the commencement, the principal redness is from the sclerotic injection, the characters of which have been above described. By-and-by there is added some injection of the conjunctiva, especially of its circumcorneal zone.

State of the cornea.—The cornea becomes dim from exudation into it; and over its margin, at some side, or even all round, vessels may be seen shooting to the extent of one-twentieth or one-tenth of an inch, and then suddenly stopping.

State of the iris.—The iris becomes discolored, the pupil contracted, sluggish in its motions, and perhaps hazy from slight exudation.

There is lacrymation, but no increased conjunctival nor Meibomian secretion.

Subjective symptoms.—The most striking subjective symptom is the rheumatic pain around the orbit, in the temples, face, &c., becoming exacerbated at night when the patient gets warm in bed, and remitting only towards morning. Besides this rheumatic pain, there is deep-seated, distending, and pulsative pain of the eyeball.

[1] Sclerotitis rheumatica vel idiopathica.

There is intolerance of light accompanying the lacrymation, usually in proportion to the degree of implication of the cornea and iris.

The vision is dim in proportion to the dimness of the cornea and haziness of the pupil.

Constitutional symptoms.—Resembling rheumatism in accompanying pain and its exacerbations, this disease resembles it also in the constitutional symptoms, inflammatory fever, derangement of digestive organs, &c.

Causes.—This disease likewise resembles rheumatism in respect of its causes, predisposing as well as exciting; but the subjects of it, who are always adults, may never have suffered from rheumatism in any other part of the body.

Both eyes are seldom affected together. When they are so, one is much less severely affected than the other.

Diagnosis.—Rheumatic is readily distinguished from catarrhal ophthalmia by the seat and character of the vascular injection (pp. 52, 91), by the absence of any mucous secretion from the conjunctiva in the former, and especially by the difference in the character of the pain. Catarrho-rheumatic ophthalmia is attended by all the symptoms of rheumatic ophthalmia, with the superaddition of those of catarrhal, and a greater tendency to mischief in the cornea than in either. From aquo-capsulitis or iritis, rheumatic ophthalmia is distinguished by the slight degree, if not absence of affection of the membrane of the aqueous humor or iris.

Prognosis.—This ophthalmia may prove slight and soon go off, but even when not so slight the prognosis is in general good. The degree to which the cornea or iris may have become affected, however, will of course modify the prognosis. A person having once suffered from it is very liable to renewed attacks. Sometimes it occurs in a chronic state, and proves obstinate without being severe.

Treatment.—In incipient or slight cases, the following treatment will sometimes check the disease—calomel, gr. iv, and Dover's powder, gr. x, at bedtime, and a purgative draught in the morning. After this fifteen or twenty drops of the wine or tincture of *colchicum*, in combination with an alkali or magnesia, may be given twice or thrice a day; but if no decided effect is produced after the third or fourth dose, its use should not be persisted in.

If the disease is not checked, and if the rheumatic pain is severe and the cornea and iris threatened, blood should be at once abstracted. According to the strength of the patient, the venesection should be carried to ℥xij—xvj—xx. [Mustard pediluvia every night.]

After the bleeding, calomel and Dover's powder, or calomel and James's powder, are to be given at bedtime, and a purgative draught in the morning; after which calomel and opium (gr. j—

gr. ¼), three times a day, until the gums are just touched. If the bowels become confined, a solution of Epsom salts, ʒj, and tartar emetic, gr. ij, in water, ʒviij, in doses of two table-spoonfuls in the morning may be prescribed. [We have been very successful in addition to anodynes, with the prescriptions (modified more or less according to the case) recommended by Dr. Hays, in his edition of Lawrence (3d ed. pp. 428 and 441):

℞.—Cal. gr. viij–x;
Pot. Nitrat. ʒj;
Ant. Tart. gr. j. M. et in chart viij divide.
S. One every four hours.

This is to be followed, if necessary, with Scudamore's mixture, combined with oil of turpentine in the following formula:

℞.—Magnes. Sulph. ʒiv–ʒvss;
Magnes. Carb. ʒij;
Vin. Rad. Colch. fʒj–fʒij;
Ol. Tereb. fʒj–fʒij;
Syr. Cort. Aurant. fʒj;
Aq. Carbon. fʒvij. M.
S. One to two fluid ounces every three or four hours.

The eye is to be bathed occasionally with tepid water, and in the intervals kept lightly covered with a dry compress. As a means, though only subsidiary to the venesection and calomel and Dover's powder, of moderating the rheumatic pain around the orbit, or in the temples, &c., friction over the seat of pain, with mercurial ointment, combined with an equal part of extract of belladonna; with a tincture of tobacco (p. 78); or with morphia dissolved in almond oil, may be employed at bedtime. The belladonna application will at the same time serve to keep the pupil dilated, which is a point to be attended to when there is implication of the iris.

Counter-irritation, by blisters or tartar emetic ointment to the nape of the neck or scalp, is useful, in the decline of the inflammation.

When by the above treatment the disease has been checked, tonics promote convalescence. Bark and carbonate of soda, in doses of five grains each, two or three times a day, is a favorite tonic; quina also is useful. [So also is iodide of potassium in from five to ten grain doses t. d.]

Scrofulous sclerotitis.

The anatomical characters of this ophthalmia have been above sketched (p. 91). In illustration of its course and treatment, the following case is given: A girl, aged 8, of scrofulous constitution, has had the eyes slightly bloodshot for a month past—the

more affected than the left. On examination, there is seen right eye, on the nasal and temporal sides of the cornea, a yellowish-gray elevation depending chiefly on thickening of otica; there is sclerotic and also slight conjunctival injec- he place. No pain nor intolerance of light. Sight quite

three or four two-grain doses of hydrargyrum cum creta, me, the eyes were found better, the redness much dimi- but improvement not advancing, two leeches were twice at an interval of six days; each time with benefit. Cod- was then given, and after that the vascular injection and ng of the sclerotica progressively diminished, until, about of two months the eyes were quite well, and the sclerotica ıtural appearance.

e case just related, there was no pain, and the cornea re- quite clear; but in another case, the patient, a girl of or thirteen, complained of some pain, especially over the ys, and the cornea became somewhat nebulous. In this girl, in whom the inflammation was altogether more severe, y took place under similar treatment, but more slowly.

inflammation must not be confounded with pustular oph- a, on the one hand, nor with sclerotico-choroiditis on the other.

Genus III.—corneitis.[1]

Whilst congestion was taken as the characteristic of sclerotitis, exudation, for the reasons above given (p. 91, et seq.), must be taken as the characteristic of corneitis.

As species of corneitis, I rank, 1st, common scrofulous or phlyctenular ophthalmia, 2d, scrofulous corneitis, and 3d, rheumatic corneitis.

Scrofulous or phlyctenular ophthalmia is usually ranked as a conjunctival inflammation, but with no good reason, seeing that although the conjunctiva is the seat of injection, the redness is neither great nor uniform, the vessels being few in number, and running singly or in detached fasciculi towards the cornea—an injection of the conjunctiva which is the consequence rather of the afflux of blood towards the primarily affected cornea; and seeing that it is the cornea which is the seat of the exudation—of phlyctenulæ, of ulcers, and of new vessels into which those of the conjunctiva are continued. Moreover, besides conjunctival, there is some degree of sclerotic injection.

Corneitis, commonly so called, comprising both scrofulous and rheumatic corneitis, is an inflammation of the "adhesive" character,

[1] Keratitis.

involving principally the proper substance of the cornea; hence it has been also named *parenchymatous* corneitis, though the conjunctiva corneæ, on the one hand, and the membrane of Descemet, on the other, may also become affected.

While in phlyctenular ophthalmia and corneitis, commonly so called, the iris is apt to become involved, it is always more or less so in inflammation of the membrane of Descemet. Indeed, affection of the iris constitutes a part of this ophthalmia, which has thence been named *kerato-iritis*, and also *aquo-capsulitis*, under the impression that the membrane of Descemet extends over the anterior surface of the iris, and thus constitutes the investing membrane of the anterior chamber of the aqueous humor. The inflammation in question will thus be best treated of under the head of *ophthalmia interna anterior*.

The other ophthalmiæ, in which the cornea, whether its proper substance, or its conjunctival layer, is implicated, belong to the genus of compound external ophthalmia (p. 147).

Scrofulous or phlyctenular ophthalmia.[1]

This is the most common form of ophthalmia in children of from one to twelve years of age. Out of 100 cases of ophthalmia at that time of life, it has been estimated that 90 are cases of this kind. Although the subjects of it often present the scrofulous diathesis in a well-marked manner, and not unfrequently are laboring at the same time under scrofulous affections of other parts, it is to be remembered that cases frequently occur in which there are no such evidences of scrofula. Unless, therefore, we chose to view, as some do, this form of ophthalmia itself as a manifestation of a scrofulous constitution, the term "scrofulous ophthalmia" must be received rather in a conventional than in a literal sense.

Objective symptoms.—When the little patient is brought into the light to be examined, the eyelids are found spasmodically closed, the eyebrows depressed, and the cheeks drawn up, the child endeavoring at the same time to cover the eyes with his hands in order to protect them from the light.

In consequence of the very forced closure of the eyelids, their borders are sometimes found so much inverted, that their cutaneous surfaces are in contact; and if this has been of long continuance, these surfaces will be moist and soft like mucous membrane.

There is greater or less redness and excoriation of the cheeks, and not unfrequently a pustular eruption, extending over the face, forehead, and temples.

As it is in general impossible for the child to open the eyelids, even if disposed, in consequence of the great intolerance of light,

[1] Conjunctivitis scrofulosa vel strumosa—Erethitic form of scrofulous ophthalmia.

and involuntary spasmodic closure of the eyelids, it is necessary for the surgeon to do so in order to examine the eyes. For the mode of procedure, see p. 50.

On opening the eyelids, which are probably somewhat red and tumid at their margins, a gush of hot tears takes place, which had been pent up in the oculo-palpebral space, in consequence of the continued closure of the eyelids.

The examination will probably not disclose much vascular injection of the sclerotic conjunctiva, and some of what is seen, even, may have been caused by the irritation of opening the eyelids. There may be merely a fine circumcorneal reticular blush, fed by some small pink scattered vessels running towards it, such as is occasioned by the irritation of a foreign particle which has got into the eye. Some larger vessels, however, will perhaps be seen collected into fasciculi, running from the angles towards the cornea. In addition to the conjunctival injection, there is also circumcorneal zonular redness of the sclerotica.

The palpebral conjunctiva is usually the seat of considerable congestion.

The cornea, though suffused, may be as yet free from any circumscribed speck; but ere long, one or more *phlyctenulæ* are met with, or small ulcers left by the bursting of phlyctenulæ.

The cornea may be still unpervaded by red vessels; or perhaps a single one may be detected running over its margin towards the phlyctenula; or if, instead of a phlyctenula, an ulcer already exists, there may or may not be a fasciculus of vessels extending into it (p. 95).

Sometimes there is onyx, sometimes an abscess or large pustule.

The pupil is usually rather contracted.

Whilst the lacrymation is so great, the conjunctival and Meibomian secretions are not much increased.

Both eyes are generally affected at the same time, but one is always worse than the other.

Subjective symptoms.—There is in general not much distress, except from the great intolerance of light; and this remits towards evening, or may be relieved at other times by darkening the room. There occur, however, occasional attacks of darting pain in the eye at night; and if phlyctenulæ or ulcers exist, there is the painful sensation as if a foreign body were in the eye, aggravated when the eyelids are moved. The irritation of the excoriated cheek by the tears also causes considerable distress.

Constitution and state of health.—As above mentioned, the constitution of the subjects of this ophthalmia is, in a great number of cases, that which is known by the name of scrofulous.

Along with the ophthalmia, a disordered state of the health will be found generally to exist. The digestive organs and skin espe-

cially will probably be found out of order, with feverishness and irritability of temper.

Causes.—The predisposing causes of scrofulous ophthalmia may be referred principally to the age, constitution, and state of health of the patient. That age predisposes, is shown by the circumstance, that it is the most common by far of all the inflammations of the eye in children, and that an inflammation originally of a different kind, in childhood, is extremely apt to run into it. That the constitution predisposes, may be inferred from the name of the disease being taken from that state of constitution in connection with which the ophthalmia so frequently manifests itself in early life. It is to be observed, that at such age, and in such constitutions, it may in one case be the eye, in another the ear, in a third some other organ which is affected; but in all, the digestive organs are found more or less at fault. Previous attacks, and also exanthematous diseases, predispose to it.—See *Exanthematous ophthalmiæ.*

Exciting causes.—This inflammation may be excited by any of the ordinary exciting causes of ophthalmic inflammation, the age, constitution, and state of health determining its particular character. Any common inflammation of the eye is in such circumstances apt to merge into this. The ophthalmia often appears to be excited and kept up by the irritation of teething.

Diagnosis.—The symptoms of this ophthalmia are so very striking, that it can scarcely be confounded with any other, especially if the age of the patient be taken into account.

In so far as regards the slight degree of redness of the white of the eyes and the great intolerance of light, scrofulous corneitis resembles it; but the changes which take place in the cornea in the two ophthalmiæ are quite different. In scrofulous corneitis, there is no formation of phlyctenulæ, nor ulceration, and rarely onyx or abscess, but opaque adhesive exudation into the substance of the cornea, and development of a general deep-seated vascularity, with increased prominence of the cornea.

Scrofulo-catarrhal ophthalmia is distinguished from phlyctenular ophthalmia by the greater redness of the white of the eye, and the less degree or absence of intolerance of light.

The age of the patient alone, independent of other points of difference, distinguishes between this ophthalmia and catarrho-rheumatic.

Course and prognosis.—Phlyctenulæ on the cornea may either recede without being much matured, or pass into ulceration. If a phlyctenula on the cornea recede, it will leave a speck called *albugo* —round, smooth, slightly elevated, and densely opaque in its centre, but shaded off at its circumference. Sometimes a vessel or two may be seen running into an albugo, or a nebulous streak indicates where vessels had run.

If ulceration has taken place, the ulcer will probably be the point of termination of a fasciculus of vessels as above mentioned (p. 139); but when the healing process commences, one vessel after another shrinks and disappears. If the ulcer has penetrated to any depth, an opaque cicatrice or *leucoma* will be left (p. 98).

There is a circumscribed and rather deep ulcer of the cornea met with in this disease. It is circular, with smooth, round edges, quite clear to its bottom, unaccompanied by any extension of vessels into it, and the cornea around is scarcely, if at all, nebulous. The cornea looks simply as if a small piece had been scooped out of it. After this ulcer heals, a small clear facet remains (p. 98).

The inflammation continuing unchecked, ulcers which may have formed, often go on increasing in depth, until the proper substance of the cornea is perforated, in which case the membrane of Descemet is protruded through the opening at the bottom of the ulcer in the form of a small transparent vesicle (*hernia of the cornea*), which soon bursts, and the aqueous humor escapes, the consequences of which have been described above (p. 97, et seq.)

Iritis sometimes supervenes in this form of ophthalmia. Sometimes also, inflammation of the posterior tunics, by which the eye is left amaurotic, atrophic, or in a state of varicosity.

From long continuance of the forced closure of the eyelids (p. 138) entropium is apt to be induced.

There is less tendency to ophthalmia tarsi in this, than in scrofulo-catarrhal ophthalmia.

This is one of the most obstinate of all the acute inflammations of the eye, and one of those most liable to relapse. The disposition to the disease, however, diminishes on the approach of puberty.

If the cornea be still free from phlyctenulæ or ulcers the prognosis is good; but if phlyctenulæ or ulcers exist, the prognosis must be qualified by the likelihood of a speck or specks on the cornea. See above.

The state of the constitution, and the circumstances in which the patient is placed, must greatly influence the prognosis.

The dismissal, when cured, should always be accompanied by a warning as to the great tendency of the disease to return, and instructions as to the diet and regimen best calculated to guard against a relapse.

Treatment.—The treatment is always advantageously commenced with an emetic—and an antimonial emetic is the best. (Vin. antimon. ʒj; aq. pur. ʒij—a table-spoonful every ten minutes until vomiting). [Pulv. Ipecac. gr. v.–xx, every ten minutes, p. r. n., is less prostrating.]

After this small doses of hydrargyrum cum creta (gr. ij–iij),

in combination with powdered leaves of belladonna (gr. ss.–j), are to be given night and morning for a few days. A dose of calomel and rhubarb or scammony may be required in addition.

The digestive organs having been by the alteratives and purgatives brought into a better state, the disulphate of quina, in doses of gr. j–ij, three times a day, will be found, in a large proportion of cases, to act like a specific. [Cal. (gr. $\frac{1}{6}$–$\frac{1}{2}$) and quin. sulph. (gr. $\frac{1}{2}$–ij.), or hyd. chlor. corros. gr. $\frac{1}{16}$–$\frac{1}{2}$ in ext. cinchon. fluid. f ʒj.–ij., t. d. answer admirably.] Under its use, the inflammation and intolerance of light soon begin to subside, and this is followed by the disappearance of the phlyctenulæ and healing of the ulcers on the cornea.

Cod-liver oil, with or without quina [or with oil of turpentine], is often of great efficacy. In some cases, iron, or sulphuric acid, and in others, rhubarb with carbonate of soda, will be found useful as tonics. [In some cases ext. nuc. vomic. or ext. ignat. amar., and in others Fowler's solution, *cautiously employed*, are very useful.]

The application of a few leeches around the eye is occasionally required to relieve the congestion, and thus to promote the action of the other remedies. In a case, for example, attended with great intolerance of light, little or no impression was made on the inflammation by the ordinary remedies for a month, until after the application of two leeches to each eye, when the inflammation and intolerance of light began to diminish; and under the use of remedies which before proved ineffectual the case went on to a cure.

A warm bath at bedtime is useful, relieving feverishness and determining to the skin. [Warm or hot salt baths are often advantageous.]

Counter-irritation by blisters, kept open or repeatedly renewed, behind the ears, or behind and below the mastoid process, is always of great service; and afterwards, when the ophthalmia has declined, the application of a warm plaster between the shoulders.

As an application to the eye itself, the belladonna lotion may be used from the first. It soothes the eye, and greatly, if not wholly, relieves the intolerance of light. Steaming the eyes with the vapor of hot water impregnated with belladonna, has the same effect (p. 67). [The application of tincture of iodine around the eyes, and to the lids externally, every two or three days, often produces a very striking effect upon the photophobia, and affords the most gratifying relief.]

The acute symptoms having been overcome by the treatment above indicated, recourse may be had to the use of the bichloride of mercury lotion three times daily, and the weak red precipitate ointment at bedtime; whilst at intervals of two or three days the nitrate of silver solution may be dropped into the eyes.

If, under this treatment, the case does not improve, but the in-

flammation, on the contrary, continues active and severe, the iris, perhaps, becoming discolored, with the pupil contracted, and ulceration threatening to penetrate the cornea, the following treatment should, without delay, be had recourse to: Two or three leeches to the eye, half grain doses of calomel three times a day, in conjunction with the quina; and the resumption of the belladonna fomentation, to keep the pupil dilated if it is the centre of the cornea which is the seat of ulceration, in order, if penetration should take place, prolapsus iridis may be obviated; but if, on the contrary, the ulceration be towards the circumference, fomentations of warm water alone are to be used.

Where penetration of the cornea has actually taken place, and the aqueous humor in consequence escaped, and the iris fallen forwards against the cornea, the patient must be kept very quiet, the eye gently bathed with warm water occasionally, and the calomel and quina continued. The inflammation now remitting, the ulcer of the cornea closes, the aqueous humor reaccumulates, and the iris resumes its natural position if no prolapse has occurred. Under these circumstances the calomel is to be omitted, and the cod-liver oil and quina resumed. The irritating collyria to the eye will now promote the subsidence of the inflammation and the cicatrization of the ulcer.

The eyes are not to be bound up, but may be protected by a large shade like a bonnet front.

Good air, moderate light, friction of the skin, the tepid bath, [salt bath] comfortable clothing, and simple nourishing diet [and exercise] are important dietetical adjuvants in the treatment of this ophthalmia.

When there is great tendency to relapse, removal to a milder climate or a more sheltered situation, will often be advantageous.

Scrofulous corneitis.[1]

There are two distinct forms of this disease, designated acute or erethitic, and chronic or torpid.

Acute, or erethitic form.

Objective symptoms.—There is little redness of the white of the eye, and what does exist is principally due to sclerotic injection. The proper substance of the cornea is the seat of exudation. This is manifested by a deep seated grayish-white opacity, denser at some points than others, which by-and-by becomes intermixed with red, in consequence of the development of vessels in the exuded matter. In this case, the cornea presents a peculiar opalescent appearance.

When the conjunctiva cornea is co-affected, as is generally more or less the case, it is in some part of its extent opaque, thickened, and vascular, the vessels being in continuation with those of the

[1] Keratitis parenchymatosa scrofulosa.

corresponding part of the circumcorneal network of the sclerotic conjunctiva, the injection of which part is greater than elsewhere. In the rest of its extent, the surface of the cornea is sometimes, though not always, rough and dim.

In the course of the disease, increased prominence of the cornea is apt to take place, owing to softening of its texture, on the one hand, and distension by increased accumulation of aqueous matter on the other.

Iritis may supervene, but this, on account of opacity of the cornea, may not be readily detected.

Subjective symptoms.—There is perhaps headache, but, in general, little pain in the eyeball—an uneasy feeling merely of distension or of pressure over it—the intolerance of light is more or less considerable, and, as usual, accompanied by lacrymation. Of course, there is dimness of vision, in proportion to the opacity of the cornea.

Constitutional symptoms.—When the local symptoms are most severe, so are the constitutional, viz., general feverishness, dry skin, white tongue, loss of appetite, and headache.

Exacerbations and remissions of the disease occur.

Predisposing causes.—These are much the same as in common scrofulous ophthalmia, only the subjects of the disease are generally somewhat older—from eight to eighteen. Females are more frequently affected than males, and in them, when of the age of puberty, there is often disturbed menstruation.

Exciting causes.—The disease sometimes supervenes on another ophthalmia. Injury of the cornea, or exposure to cold and wet, often appears to be the exciting cause. Sometimes the inflammation comes on after the retrocession of some disease of the skin. Often the etiology is obscure.

Diagnosis.—This ophthalmia is distinguished from phlyctenular ophthalmia by the difference in the changes which take place in the cornea; from the compound ophthalmiæ, in which the cornea is implicated, by the slight degree of redness of the white of the eye, and the peculiar changes in the cornea; from the chronic form, by the intolerance of light, and the greater opacity of the cornea, and the other changes in its appearance, mentioned in their proper places (p. 146).

When conjunctival opacity, thickening, and vascularity extend over the whole cornea, they conceal the affection of the proper substance; but the existence of this, and the distinction of such a case from that in which the conjunctiva corneæ alone, and not the proper substance, is affected, as it may be found in scrofulo-catarrhal ophthalmia, are indicated by the great intolerance of light, and by the increased prominence of the cornea, which generally after a time presents itself.

Course and prognosis.—Inflammation of the proper substance of the cornea is an obstinate disease. It may go on for a long time, alternately getting better and worse. Inflammation of the membrane of Descemet and iritis readily supervene, and the sclerotica, choroid, and ciliary body may also become involved, in which case there is added to the increased prominence of the cornea a conical projection of the whole front of the eyeball, in consequence of an attenuation and yielding of the anterior part of the sclerotica. Under such circumstances, the retina has usually also suffered; and there are consequently more or less amaurotic symptoms.

When the inflammation is arrested, the cornea clears sometimes very rapidly, and to an extent not previously expected. The clearing of the cornea takes place from the circumference towards the centre, where opacity usually lingers, and often continues fixed.

Increased prominence of the cornea having once taken place, is permanent.

Relapses are frequent.

Treatment.—This is to be conducted very much on the same plan as the treatment of phlyctenular ophthalmia. If the patient be a grown-up female, attention should be directed to the state of menstruation.

The general abstraction of blood is not often required, but the occasional application of leeches around the eye is generally necessary.

The bowels having been cleared out, the hydrargyrum c. creta and belladonna powders, or calomel, in half-grain doses, may be given three times a day for a few days. If, after this, the acuteness of the disease be checked, quinine, bark and soda, or other tonics, such as iron, baryta, &c., according to the condition of the patient, will prove of great advantage. Counter-irritation is, at the same time, to be employed.

Oil of turpentine, in doses of 3ss. three times a day, often operates beneficially. It may be given in milk. I find it especially efficacious in combination with cod-liver oil (3ij). The use of the turpentine is not to be continued longer than two or three days, for if a good effect does take place, it generally appears within that time. The cod-liver oil, however, may in any case be continued, with or without a grain or two of quina [or with liq. ferri iod.], in each dose.

Steaming the eyes with hot water impregnated with belladonna (p. 67), and bathing them with the belladonna lotion, in general soothe the eyes, and mitigate the intolerance of light. Belladonna is also of use for the purpose of keeping the pupil dilated (p. 60), when it is feared the iris has become affected.

When the inflammation has been fairly arrested, the clearing of

the cornea will be promoted by the occasional use of the bichloride of mercury lotion, the weak red precipitate ointment, or the like.

Evacuation of the aqueous humor is sometimes of use, especially in cases with great distension of the cornea.

Chronic or torpid form.

Objective symptoms.—Though there is not much redness of the eye to attract notice, still, on close examination, it will be found that it is pervaded by red vessels, both conjunctival and sclerotic, besides being dull and dirty-looking.

There is little exudation into the substance of the cornea—at the most, enough to produce streaks or clouds of opacity; but the most peculiar appearance which the cornea presents, is the roughness of its surface, like ground glass, and a dirty yellowish-green color, as above mentioned (p. 94.) The cornea is at the same time unnaturally prominent, sometimes increased in diameter, with corresponding enlargement of the anterior chamber.

Subjective symptoms.—There is merely dimness of vision, without any pain or intolerance of light.

Constitution.—The subjects of this form of corneitis are usually of a dull, leucophlegmatic, scrofulous habit. They often are at the same time affected with deafness.

Treatment.—The treatment applicable in this form of corneitis, will be understood from what is laid down in the preceding article.

The diet and regimen above recommended for phlyctenular ophthalmia (p. 142), are equally called for in both the forms of corneitis now described.

Rheumatic corneitis.[1]

When parenchymatous corneitis occurs in persons about middle age, as it sometimes, though not usually does, it is accompanied by rheumatic characters, and is designated *rheumatic corneitis*, in contradistinction to the name *scrofulous corneitis*, given to the disease when it occurs in young persons, as is generally the case.

The following is an example of this species of inflammation of the cornea:

A. E., aged 37, first seen Nov. 12.—Subject to rheumatism. The right eye has been affected for the last six or seven weeks; during all which time he has occasionally suffered pain over the eyebrow and in the temple. Yesterday the pain was more severe than it has yet been.

On examination (Nov. 12), the cornea of the right eye in its upper third, was found quite red from vascular injection. In the

[1] Keratitis parenchymatosa rheumatica.

rest of its extent, dim and rough on its surface. Considerable vascular injection of both conjunctiva and sclerotica, especially intense next the vascular part of the cornea. The palpebral conjunctiva congested, and the edges of the eyelids red, and slightly swollen.

Venesection to ʒviij or ʒx, Dover's powder, gr. x, and calomel, gr. iij at bedtime, followed by black draught next morning. After that, calomel gr. j, and opium gr. ¼, night and morning.

Nov. 14.—Eye is very much better to-day—the injection of the white of the eye considerably less; the vascularity of the upper part of the cornea, and the dimness of the rest of its extent, very sensibly diminished. To continue the calomel and opium, and to bathe the eye three times a day with warm water.

Nov. 23.—Much affected by the mercury. The inflammation subsiding very decidedly. The vessels in the upper part of the cornea much reduced in number. To continue the calomel at bedtime only, and apply a blister behind the right ear.

25th.—Eye continues to improve. Mouth not quite so sore.

28th.—The inflammation is rapidly diminishing. The redness of the white of the eye has in a great measure disappeared, and the new vessels in the cornea going on to shrink one after the other.

Dec. 1.—The vessels in the cornea have still further shrunk.

A few days after this some increase of the inflammation took place, but after the application of leeches and a repetition of the treatment, improvement again went on. The mercury was then omitted, and cod-liver oil given, under the use of which the inflammation wholly subsided;—the cornea became quite free from vascularity and cleared, with the exception of slight nebula at its upper part.

Genus IV.—compound external ophthalmia.

The ophthalmiæ, comprehended as species under this head, are scrofulo-catarrhal, and catarrho-rheumatic.

Scrofulo-catarrhal ophthalmia.[1]

This is a combination of common scrofulous or phlyctenular ophthalmia and catarrhal; having sometimes more of the characters of the former, sometimes more of the characters of the latter, with occasionally an admixture of pustular ophthalmia.

Objective symptoms.—This form of ophthalmia not being attended by any great intolerance of light, the eyelids are not spasmodically closed, but usually kept half open. Their borders are red and swollen, and perhaps nodulated, from enlargement of the glandular structures situated there, and the eyelashes are incrusted

[1] Torpid form of scrofulous ophthalmia.

with dried Meibomian secretion, which is poured out in increased quantity.

The vascular injection of the conjunctiva, both palpebral and sclerotic, is very considerable, and though with less uniformity, presents the catarrhal characters. There may be also some sclerotic injection.

Pustules may present themselves on the sclerotic conjunctiva, and at the margin of the cornea, but the cornea itself may as yet be clear, or it may be the seat of onyx, or of phlyctenulæ or ulceration. The phlyctenulæ on the cornea usually reach a larger size than those which occur in common phlyctenular ophthalmia—indeed, they mature into pustules, and bursting, leave large ulcers, with flabby, everted, and perhaps red edges, into which large fasciculi of vessels run from the neighboring conjunctiva and sclerotica.

Instead of the cornea suffering in this way, the conjunctiva corneæ may be found in some parts of its extent the seat of exudation —opaque, thickened, and vascular. The vessels are closely arranged side by side, and extend over the margin of the cornea, in continuation from those of the conjunctival circumcorneal zone, and with the opacity, and thickening of the conjunctiva corneæ stop abruptly (*vascular speck*).

The pupil is natural.

Lacrymation is comparatively inconsiderable, but there is a marked puromucous secretion from the conjunctiva, together with the increased discharge from the glands of the borders of the eyelids, above mentioned.

Subjective symptoms.—There is little intolerance of light or pain.

Constitutional symptoms.—There is no acute constitutional disturbance, but the patients are in general out of health—there is, perhaps, disordered digestion; and if a female at the period of puberty, the menstrual function is probably disturbed.

One eye alone may be affected, but often both. One is usually worse than the other, or it may be, that whilst one is affected more in the manner of a catarrhal ophthalmia, with the cornea clear, the pupil natural, and no intolerance, the other is affected more in the manner of phlyctenular ophthalmia—the cornea dim, the pupil contracted, and considerable intolerance of light.

Causes.—Perhaps this form of scrofulous ophthalmia is more disposed to occur in older subjects than common scrofulous or phlyctenular ophthalmia—more frequently about the age of puberty. It may be more generally connected with the torpid form of the scrofulous constitution, but it is to be observed, that in the same person one eye may be suffering from this form, whilst the other is suffering from the other. In females, disturbed menstruation often exists in causal connection with the ophthalmia.

Exciting causes.—These are the same as the exciting causes of catarrhal, pustular, and phlyctenular ophthalmiæ. The inflammation may come on first as a catarrhal or pustular ophthalmia.

Diagnosis.—This ophthalmia differs from catarrhal principally in the early implication of the cornea—from phlyctenular ophthalmia, and from parenchymatous corneitis, in the less degree of intolerance of light, or the total absence of it, and in the greater redness of the white of the eye.

That form of scrofulo-catarrhal ophthalmia in which there is opacity, thickening, and vascularity of the conjunctiva corneæ to a greater or less extent, and which is sometimes called *inflammation of the conjunctiva corneæ*, is distinguished from those cases of parenchymatous corneitis, in which there is in addition, the same affection of the conjunctiva corneæ, by the characters above mentioned (p. 144), and by what of the proper substance of the cornea, which may be still visible, not being opaque and vascular. Practically, the distinction between the two diseases is important, as the affection of the conjunctiva corneæ in scrofulo-catarrhal ophthalmia may be efficiently treated by local remedies which would be injurious in parenchymatous corneitis.

Course and prognosis.—Pustules having formed on the sclerotic conjunctiva, a large superficial abrasion is produced if the inflammation goes on unchecked.

If ulceration of the cornea has taken place, it may remain superficial, and become covered with small sarcomatous growths or real red granulations, or the ulceration, though rather indolent, may go on to penetrate the cornea, the result of which will be as above described (pp. 96, 97).

When opacity, thickening, and vascularity of the conjunctiva corneæ (*vascular specks*) take place, they may gradually spread from several points of the circumference of the cornea, and to such an extent, as to cover the whole cornea, forming what is called *pannus*.

The papillæ of the palpebral conjunctiva may become hypertrophied, constituting one form of granular conjunctiva.

Besides onyx, hypopyon may occur. Iritis, also, may supervene, if the cornea be much affected; but there is less tendency to iritis in this than in common scrofulous ophthalmia. When, however, internal inflammation does take place, there is perhaps a greater tendency for it to run into choroiditis and varicosity of the bulb, though this is a rare result in any case.

In consequence of the affection of the glandular structures at the borders of the eyelids, ophthalmia tarsi is apt to remain. Small abscesses at the roots of the eyelashes, and styes are also of frequent occurrence.

This ophthalmia is in general more easily cured than phlyctenular ophthalmia or parenchymatous corneitis, and the cure depends more on local treatment. General treatment, however, is also of great importance.

The prognosis in the course of the disease will depend on the extent to which the cornea is affected. In cases in which there are vascular specks on the cornea—vascularity, thickening, and opacity here and there of the conjunctiva corneæ, it may be prognosticated, that by a well-directed local stimulant treatment, the eye will be quickly freed from vascularity, any superficial ulceration of the cornea healed, and the cornea itself cleared, with the exception of some spots of gray opacity. It is to be kept in mind, however, that relapses are very apt to take place, especially if the state of the palpebral conjunctiva with its enlarged papillæ has not been improved.

Ulcers, though large and deep, in general heal readily under treatment, but of course leave *leucomata;* except they be of the transparent non-vascular kind, which leave a facet.

If the cornea has been penetrated by the ulceration, then the prognosis is unfavorable. Things will turn out as above mentioned (pp. 96, 97).

Onyx, if not to any great extent, readily disappears as the inflammation subsides.

Treatment—General.—Emetics are not in this ophthalmia of so much use as in phlyctenular ophthalmia, but the bowels require to be freely acted on, by repeated doses of calomel and jalap. After this, mercurial chalk may be given, in doses of two or three grains once or twice a day for a short time if the liver appear to be inactive.

The stomach and bowels having been put into order, tonics may be prescribed in addition to nourishing diet.

If the patient be a female about the age of puberty, attention must be directed to the state of the catamenial discharge.

Local treatment.—If there be much inflammation, a few leeches may be applied to the eyes, and blisters behind the ears; but local stimulants, which may be commenced at once, will be found to act more efficiently in this ophthalmia than in phlyctenular, even when there is ulceration, large, deep, and threatening to penetrate. It is from not having used the local stimulating treatment, that this ophthalmia has been erroneously put down as even more difficult of cure than phlyctenular ophthalmia.

The nitrate of silver solution is to be dropped into the eye once a day, or once every second day; the bichloride of mercury eye-water is to be used three times a day, and the red precipitate salve to the edges of the eyelids at bed-time.

In the chronic state, into which this ophthalmia is so apt to fall if neglected or not properly treated, the direct application of some strong stimulant, especially the strong red precipitate salve (p. 72), will be found to produce very decided results. The salve is to be introduced under the upper eyelid, and diffused over the whole surface of the conjunctiva, by rubbing with the point of the finger over the eyelid. Two or three such applications I have often found sufficient to remove the most marked appearances of the chronic disease, such as the vascularity and red specks of the cornea, and the injection of the sclerotic conjunctiva.

Catarrho-rheumatic Ophthalmia.[1]

In this ophthalmia, there is a combination of the symptoms of catarrhal and rheumatic ophthalmiæ, with a greater tendency in the cornea to become the seat of phlyctenula or abscess and ulcer.

Catarrho-rheumatic ophthalmia is of much more frequent occurrence than rheumatic ophthalmia, but not so common as catarrhal. The comparative frequency of the three ophthalmiæ is usually stated thus:—Rheumatic, 1—Catarrho-rheumatic, 6—Catarrhal, 10.

Objective Symptoms.—The edges of the eyelids are red and somewhat swollen. The white of the eye red, from both conjunctival and sclerotic injection. Generally, the sclerotic injection is great—the conjunctival only middling, but the contrary is sometimes the case. There is often some degree of serous chemosis, concealing the sclerotic injection. The redness of the palpebral conjunctiva is very considerable.

The disease has not in general existed beyond a few days, before the cornea becomes implicated. The epithelium of the cornea may be raised up, by exudation underneath it, in the form of a large phlyctenula, or even blister (p. 95), or the exudation being into the proper substance of the cornea, and development into pus or puriform matter taking place, an onyx or abscess is the result (p. 96). By the bursting of the phlyctenula or blister, an ulcer is left, which may remain superficial and cicatrize without opacity, but it may also penetrate deep into the substance of the cornea—even through and through it. Ulceration may also take place when there is onyx or abscess; the cornea over the collection of matter ulcerates, the matter is evacuated, and a large deep ulcer is left, which may go on to penetrate the cornea through and through. Instead of thus bursting externally, the onyx or abscess may burst into the anterior chamber, and give rise to what is called false hypopyon.

This ophthalmia is attended by lacrymation in proportion to the intolerance of light. The conjunctival mucous secretion is increased,

[1] Conjunctivo-sclerotitis—Conjunctivo-scloro-keratitis.

but in general not to a great degree, rarely to such a degree as to constitute blennorrhœa. The Meibomian secretion is poured out in increased quantity, so that the eyelids are glued together over night.

The iris and pupil are apt to become affected—the color of the iris changed—the pupil contracted and sluggish in its movements, perhaps hazy from exudation. A deposit of matter at the bottom of the anterior chamber sometimes occurs, or a true hypopyon.

Subjective symptoms.—Along with the feeling as if sand were in the eye, indicative of the conjunctival affection, and which is most troublesome in the morning, there is the severe circumorbital or temporal pain coming on at night, characteristic of the sclerotic part of the ophthalmia, and the intolerance of light, which appears to be dependent on the implication of the cornea.

The conjunctival and sclerotic parts of the affection may commence at the same time, or the conjunctival first, or the sclerotic first; in the one case, catarrhal,—in the other, rheumatic, merging into catarrho-rheumatic ophthalmia.

Constitutional symptoms.—Considerable fever, and derangement of digestive organs—pulse generally quick and sharp—tongue white, and mouth ill-tasted—sleep prevented until towards morning by the nocturnal pain.

Causes.—The predisposing causes are much the same as those of rheumatic ophthalmia.

The exciting cause is most generally cold. The disease is most prevalent during northeasterly winds. A somewhat similar inflammation occurs from traumatic causes, such as abrasion of the cornea. See below.

Diagnosis.—This ophthalmia is distinguished—

From catarrhal, by the superaddition of circumcorneal sclerotic injection, severe implication of the cornea, and the circumorbital or temporal pain (p. 119).

From rheumatic ophthalmia, by the superaddition of the conjunctivitis, and the greater affection of the cornea (p. 135).

From phlyctenular ophthalmia, by the age of the patient, and the circumorbital or temporal pain.

From corneitis, by the great redness of the white of the eye, and the difference in the kind of affection of the cornea (p 144).

From iritis, by the absence of affection of the iris, or if present, by its comparative slightness, and by the presence of the corneal affection.

Prognosis and course.—The prognosis is good, when proper treatment is begun before the cornea is much or at all affected. The rheumatic symptoms depending on the sclerotic part of the disease usually decline first, the conjunctival part of the disease receding more slowly.

When the cornea is affected with ulcer or onyx, the prognosis is doubtful until a check has been put to the inflammation. According to the state in which the cornea is, so will be the prognosis, both as regards how soon recovery of the eye is likely to take place, and to what extent the recovery may be—opacities of the cornea, synechia anterior, or partial staphyloma, may be left.

Treatment.—This comprises first the general treatment for rheumatic ophthalmia:—Venesection, if there be much circumorbital or temporal pain;—calomel (gr. iij–v), and Dover's powder (gr. x–xv) at bedtime, with black draught [infusion of "senna and salts"] next morning. After that, pills of calomel (gr. j), and opium (gr. ¼), two or three times a day. Locally, warm water fomentations.

Subsequently when, as is usually the case, the inflammation is by this treatment checked, the local treatment for catarrhal ophthalmia may be had recourse to, viz.;—the nitrate of silver drops (gr. iv–ʒj) at intervals of two or three days,—the bichloride of mercury lotion to bathe the eye with three times a day, and the weak red precipitate salve to anoint the edges of the eyelids with at bedtime.

The bowels being free, cinchona-bark and sesquicarbonate of soda (āā gr. v or gr. x), or two grains of quina, three times a day, may be now prescribed with advantage, and counter-irritation behind the ear.

In old and weakly persons, especially if the inflammation has already existed for some two or three weeks before consultation, it is often necessary to commence this tonic treatment at once. A dose of calomel, and Dover's powder at bedtime, and black draught next morning, only being premised.

Sometimes evacuation of the aqueous humor is useful when an ulcer threatens to penetrate the cornea; and if it is the middle of the cornea which is threatened with penetration, the pupil should be kept dilated by belladonna, as above directed in phlyctenular ophthalmia (p. 143).

Order II.—Ophthalmia Interna Anterior.

As genera of this order, *aquo-capsulitis*, *iritis*, and *crystallino-capsulitis anterior*, have been above admitted (p. 114).

In aquo-capsulitis, the inflammation involves not only the membrane of Descemet, but also the anterior surface of the iris. In crystallino-capsulitis anterior, the seat of the inflammation is not only the anterior wall of the capsule of the lens, but also the uvea.

Seeing thus, that in both aquo-capsulitis and crystallino-capsulitis anterior, the iris is superficially affected, some authors admit iritis as the only genus of ophthalmia interna anterior, viewing aquo-

capsulitis and crystallino-capsulitis anterior as species of **iritis**, under the names of *iritis serosa anterior*, and *iritis serosa posterior*, the species of iritis in which the whole substance of the iris is involved, being named *iritis parenchymatosa*.

Iritis serosa, however, does not comprehend all the cases which may be referred to the head of aquo-capsulitis and crystallino-capsulitis; whilst there are, on the other hand, cases of iritis serosa which cannot be considered as coming under the head of aquo-capsulitis or crystallino-capsulitis, but which properly come under the head of iritis only, especially as they are disposed to pass into iritis parenchymatosa.

Ophthalmia interna anterior may be acute or chronic. In the latter case, it is to be distinguished into that which has supervened on acute inflammation, and that which has had a chronic character from the first.

Ophthalmia interna anterior, in some one of its forms, may occur as a primary affection; but it may become more or less complicated with some degree of external or posterior internal ophthalmia, by extension of inflammation to the external or posterior tunics. On the other hand, it may arise secondarily by extension of inflammation from the external or posterior tunics.

To determine how the case stands in these respects, is an important point in the diagnosis, as both prognosis and treatment are much influenced by it.

Again, the different forms of anterior internal ophthalmia may occur as primary affections, or arise secondarily as extensions from each other. Indeed, it seldom happens but that one form is more or less complicated with some degree of another.

As the iris is always involved, either primarily and principally, or secondarily and to a greater or less degree, and as the affection of it constitutes the point on which the treatment especially hinges, the general observations which remain to be made on ophthalmia interna anterior have reference to iritis.

The *objective characters of iritis* in general have been above pointed out (p. 99, et seq.)

Of the *subjective symptoms*, the kinds of pain have been also referred to. Here it is farther to be remarked, that the pain of rheumatic character around the orbit, in the temples, &c., though usually severe and considerable, is sometimes absent. The same may be said of the intolerance of light. As to the disturbance of vision, it is in proportion to the obstruction of the pupil, unless the posterior segment of the eyeball be at the same time involved, when, with photopsy, &c., the sight may be much impaired.

Constitutional symptoms.—Sometimes there is smart inflammatory fever,—sometimes, however, little or no constitutional disturbance.

Causes.—Scrofula, rheumatism, gonorrhœa, syphilis, gout, &c., act as predisposing, modifying, or even exciting causes of iritis. The disease is most frequent in adult age, less so before puberty, and in old age. In young persons, it is usually connected with the scrofulous diathesis—in adults, with rheumatism—common or gonorrhœal—or with syphilis—in old persons, with gout. Males are more frequently the subjects of iritis than females. The left eye, it is said, is more prone to be affected—when the cause, of course, is of a general nature—than the right, and when both are affected, it usually suffers more.

Occasional causes.—Injuries. Over-exertion of the eyes may act both as a predisposing and exciting cause; also exposure of them to too strong light and heat. Exposure to cold is a common exciting cause. Iritis is apt to be occasioned by the spread of inflammation from other parts of the eye—to supervene on external ophthalmia, or on posterior internal ophthalmia. One eye being affected, the opposite usually becomes affected also—and this even in traumatic cases.

Diagnosis.—In the diagnosis of iritis, attention is to be paid principally to the changes in the iris and pupil. The external redness, pain, &c., are not all pathognomonic, inasmuch as the same may occur in other ophthalmiæ, such as rheumatic, catarrho-rheumatic, &c. In these ophthalmiæ, however, as also in choroiditis, retinitis, &c., an extension of inflammation to the iris is prone to take place. When there is dilated pupil, it will probably be found that the iritis has arisen by extension of inflammation from the posterior tunics.

There are certain cases commonly described as chronic iritis, in which the disease proceeds to diminution or destruction of vision of one eye so insidiously, that the patient perhaps becomes aware of his malady only by accidentally discovering the defect of vision. On examination, the iris is found more or less altered in structure, and its pupillary margin adherent by bands of lymph to the capsule of the lens, which is perhaps the seat of some opacity, or even vascularity, but the pupil may not be much, if at all, obstructed with lymph. The defect of vision, therefore, is not owing to the iritis, but is the result of chronic inflammation of the posterior segment of the eyeball, on which the affection of the iris has supervened. Such cases, therefore, properly come under the head of *ophthalmia interna posterior.* The other eye is apt, sooner or later, to become affected.

Prognosis.—The great danger of iritis is, that it may leave the pupil obstructed with lymph, contracted, or actually closed, or the anterior capsule of the lens opaque. Another danger of iritis is, that the inflammation is apt to spread to the deeper parts of the

eye, the ultimate result of which may be more or less complete disorganization of the organ—such as atrophy, dissolution of the vitreous body, hydrophthalmus, staphyloma sclerotica, &c., with loss of vision.

Treatment.—The chief indication is to arrest the inflammation; in other words, to remove the inflammatory congestion as quickly as possible. It is by this only that a stop can be put to the exudation, and the condition established for the absorption of what matter has been exuded. It is by this also that the pain is most quickly and decidedly relieved. Bleeding and mercurialization are the principal means by which this indication is in general most effectually fulfilled. In some cases, however, as when the patient has had repeated relapses, and has been exhausted by the treatment, they are either not admissible, or a modification requires to be made in their employment. Oil of turpentine is sometimes of use in such cases.

Another indication is to guard the pupil from being contracted or closed by the exuded lymph. This is accomplished by keeping it, throughout the disease, under the influence of belladonna.

The treatment in chronic iritis consists chiefly in tonics and alteratives, such as bark and soda; bichloride of mercury, in doses of from one-thirtieth to one-sixteenth or one-eighth of a grain three times a day, with bark and sarsaparilla;—or arseniate of potass, in doses of one-thirtieth of a grain, three times a day; counter-irritation being at the same time used.

Genus I.—AQUO-CAPSULITIS.[1]

In the disease to which this name has been given, the inflammation involves the membrane of Descemet on the one hand, and the anterior surface of the iris on the other—sometimes the one, sometimes the other being the part first or most affected—sometimes both at the same time, and equally. The disease occurs either in an acute or chronic form.

The external redness, which is slight, is owing principally to sclerotic circumcorneal, with more or less scattered conjunctival injection. Between the redness and the margin of the cornea, there sometimes intervenes the narrow bluish-white ring, usually called the *arthritic ring* (pp. 54, 55).

The affection of the membrane of Descemet is manifested by deep-seated dimness, interspersed with grayish or yellowish-white specks, from the size of a pin's head to microscopical minuteness, of the cornea, produced, as above mentioned (p. 94), by exudation

[1] Inflammation of the membrane of the anterior chamber of the aqueous humor—Keratitis serosa—Iritis serosa anterior—Kerato-iritis.

between the proper substance of the cornea, and the membrane of Descemet. There are at first no vessels in this situation, and when subsequently vessels make their appearance, they are of new formation.

The affection of the iris is manifested first by the usual loss of brilliancy and change of color, by contraction and sluggishness, or immobility of the pupil, and subsequently by exudation of lymph into the pupil, and on the surface of the iris, where new vessels may make their appearance.

Along with these changes in the membrane of Descemet and iris, there is increased accumulation of aqueous humor, causing abnormal distension, if not prominence, of the cornea—an effect of which distension is dimness or suffusion of the corneal substance, superadded to the mottled opacity from exudation between it and the membrane of Descemet.

When the opacity of the cornea is not so great as to conceal the parts behind, flakes of lymph may be observed in the aqueous humor. Sometimes there is hypopyon.

Subjective symptoms.—A feeling of distension and fulness in the eyeball, with a dull aching pain in the forehead, sometimes extending to the occiput, annoys the patient. In acute cases, circumorbital or temporal pain occurs in nocturnal paroxysms, as in rheumatic ophthalmia and iritis.

Intolerance of light and lacrymation exist, but not to a great degree.

Vision is disturbed in proportion to the opacity from exudation both between the substance of the cornea and the membrane of Descemet, and into the pupil.

Constitutional symptoms.—In acute cases there is some febrile disturbance. The scrofulous constitution, or other disordered state of health which usually exists, belongs to the head of predisposing cause.

Causes.—The disease is sometimes of traumatic origin. In the disordered state of health just alluded to, such causes as over-exertion of the eyes, and suppressed perspiration, have been found to excite the disease. It most usually occurs in persons below middle age.

Diagnosis.—Aquo-capsulitis requires to be distinguished from common corneitis on the one hand, and from common iritis on the other. From common corneitis, it is distinguished by the deep situation, and the peculiar mottled appearance of the opacity of the cornea; and the presence of this opacity, in addition to the changes in the iris, distinguishes the disease from simple iritis.

Prognosis.—The disease, especially the chronic form of it, is sometimes obstinate. Relapses are liable to occur.

Treatment.—This should be much the same as is above recommended for corneitis, with the addition of a more decided use of mercury for the accompanying iritis—and also the moderate abstraction of blood. When abstraction of blood is not called for or not admissible, the treatment may be commenced with an emetocathartic (p. 120), after which the use of mercury should be commenced and pushed so as to affect the gums slightly. Quinine may be given at the same time, or afterwards, according to circumstances.

Turpentine is sometimes efficacious, as above mentioned in corneitis (p. 145).

Counter-irritation is of great use.

As a fomentation and to keep the pupil dilated, the belladonna lotion (p. 69) may be prescribed.

No irritating drop or salve is admissible.

Genus II.—iritis.

The species or varieties of iritis to be considered here, are such cases as are primary, or at most occur only as extensions from the external tunics. Those cases of iritis which occur as extensions of posterior internal inflammation, will be considered under the head of ophthalmia interna posterior.

The varieties of primary iritis are—scrofulous, rheumatic, syphilitic, and arthritic, the two former coming under the head of *iritis serosa*, the two latter under that of *iritis parenchymatosa*. In many cases, certain of these varieties of iritis are variously mixed up or complicated with each other—a circumstance which requires to be taken into consideration in forming a diagnosis, delivering a prognosis, and planning the treatment.

Scrofulous iritis.[1]

In phlyctenular ophthalmia, and in corneitis, the inflammation, as above mentioned (pp. 138, 141), is apt to extend to the anterior surface and pupillary circle of the iris. In some cases, the iris appears to be primarily affected. These cases, spoken of as cases of scrofulous iritis, usually occur in persons below or about the age of puberty.

In addition to the treatment above indicated for the phlyctenular ophthalmia, or for the corneitis, it is necessary to give mercury, so as to affect the gums, with the precautions which the constitution of the patient requires; or, instead of mercury, oil of turpentine, as above indicated, may be tried. The pupil should be kept under the influence of belladonna.

[1] Ophthalmia scrofulosa interna anterior.

A chronic form of scrofulous iritis is also met with, usually in connection with chronic corneitis—sometimes with inflammation of the posterior tunics. A tonic and alterative treatment is indicated in such cases.

Rheumatic iritis.

In rheumatic and catarrho-rheumatic ophthalmiæ, it has been above seen (pp. 134, 152), that the iris is apt to be somewhat involved in the inflammation. When in an ophthalmia occurring under the same circumstances as rheumatic or catarrho-rheumatic ophthalmia usually does, the iris is the principal seat of the inflammation, the case is conventionally said to be one of *rheumatic iritis*—and this whether the patient has been subject to rheumatism in any other part of the body or not.

Rheumatic iritis constitutes what is called an *iritis serosa anterior*, as the inflammation principally affects the anterior surface of the iris. It may, however, also extend to the proper substance of the membrane.

Symptoms at the commencement.—Slight superficial pain of the eye, with increased sensibility to light and lacrymation, first attract the attention of the patient. On examination, the white of the eye may be found but slightly red, and this principally from scattered conjunctival vessels. No change may be perceptible in the iris, except, perhaps, that it is dull-looking, and its pupillary margin not so sharply defined as natural. As regards the pupil, its motions may be as yet unimpeded.

Sclerotic circumcorneal zonular injection now becoming well-marked, the appearance of the iris changes—first in its lesser circle, which is reddish and swollen—the pupil becomes dim, contracted, and sluggish, the pain in the eye increases, and after a nocturnal paroxysm of circumorbital or temporal pain, exudation of lymph is discovered to have taken place. The disease is thus fully formed.

Symptoms in the fully-formed state—Objective symptoms.—As has been above more particularly described (p. 99, et seq.), the white of the eye is red from sclerotic circumcorneal, and more or less conjunctival, injection. The color of the iris, if naturally blue, is now green, if naturally hazel, reddish-brown. Exuded lymph is seen in the now fixed and distorted pupil, and sometimes in flakes suspended in the aqueous humor.

Besides these changes, the cornea is distended from increase in the quantity of aqueous humor (p. 99); it is more or less dim; and if the inflammation has involved the membrane of Descemet, the deep punctiform opacities indicative of this, are presented.

The palpebral conjunctiva is injected, and the eyelids towards their tarsal borders are somewhat red and swollen.

Subjective symptoms.—Besides the nocturnal paroxysms of circumorbital or temporal rheumatic pain, such as occur in rheumatic or catarrho-rheumatic ophthalmia, there may be a painful feeling of distension in the eyeball, and a dull pain extending from the forehead to the occiput.

There is much intolerance of light, accompanied by lacrymation. Vision is very considerably disturbed.

Constitutional symptoms.—Rheumatic iritis, like rheumatic ophthalmia, is attended by inflammatory fever, manifested by the usual symptoms of full strong pulse, white and dry tongue, costiveness, thirst, loss of appetite, and want of sleep. The want of sleep is in part due to the severity of the nocturnal pain.

The causes, predisposing and exciting, of rheumatic iritis, are the same as those of rheumatic ophthalmia (p. 135). Rheumatic iritis, along with rheumatic inflammation of the joints, sometimes occurs as a consequence of gonorrhœa. A similar iritis is apt to occur during or after the use of mercury, the mercury rendering the system more susceptible to the action of cold. The iritis having once occurred, leaves a predisposition to subsequent attacks.

One eye only, or both, may be affected. In the latter case, the inflammation is usually more severe in the one than in the other.

Diagnosis.—The diagnosis of the disease, in its fully formed state, as an iritis, being made (p. 155), its rheumatic nature is determined, as above said, principally by the circumstances under which the attack has come on, taken in conjunction with the character of the symptoms.

Prognosis.—The prognosis is in general good if the disease is taken in time, before much exudation has occurred, and properly treated. In this case it may be cured in three or four weeks. A tendency to relapse, however, remains.

Left to itself, or improperly treated, the inflammation may fall into a chronic state, or it may eventually subside, but perhaps not until by exudation of lymph the pupil is obstructed or actually closed, or the anterior capsule opaque, and the eye is rendered more or less completely unfit for vision. The progress of the healing process of iritis, in general, as described in p. 100, is quite applicable to rheumatic iritis.

Treatment.—Venesection is the first remedy to be had recourse to, and it may be repeated. After bloodletting, three or four grains of calomel, and ten or fifteen grains of Dover's powder are to be given at bedtime, and next morning a purgative draught. The calomel and opium are then to be continued in smaller doses (gr. j–gr. $\frac{1}{4}$), every four hours until the gums are sore. [In these cases the nitrous powder and the colchicum mixture with turpentine (see ante, p. 136), to be followed by iodide of potassium (gr. v.–xv. t. d.), when the gums are touched, will be found to operate well.]

If, under this treatment, the gums do not soon become sore, and if the inflammation does not show indications of subsiding, the venesection should be repeated, after which, probably the gums will quickly become affected, and an evident diminution of the severity of the disease take place.

Low diet is to be enjoined, and the bowels kept open with castor oil, or an emeto-cathartic. Rest and quiet, and protection of the eyes from strong light, are important parts of the treatment.

The eye may be occasionally bathed with belladonna lotion, after which it is to be carefully dried, and covered lightly.

To assist in warding off nocturnal pain, inunction over the pained part is to be made with mercurial ointment, and belladonna, opium, tincture of tobacco, &c., as above indicated for rheumatic ophthalmia. [Hot mustard foot-baths are often very soothing.]

When the inflammation begins to yield, counter-irritation repeated occasionally will promote the cure.

The violence of the disease having subsided, absorption of exuded matter commences. After this, improved diet, and bark or quinine may be ordered.

When circumstances forbid the use or longer continuance of mercury, turpentine, as above recommended, may be tried as a substitute, in doses of ʒss to ʒj, three times a day.

In a case of rheumatic iritis, treated by venesection and mercurialization, in which after convalescence a relapse took place, forty drops of turpentine were ordered three times a day. The report, the second day after, was as follows:—Has taken five doses of turpentine. The eye is to-day very much better. States the improvement began yesterday. The action of the mercury on the mouth had become very much diminished, but since taking the turpentine the patient finds the mouth rather severely affected again.

Syphilitic iritis.

In syphilitic iritis the inflammation involves the whole substance of the iris (*parenchymatous iritis*), and is very apt to spread to other parts of the eye.

Objective symptoms.—In the fully formed state of the disease, there is well-marked external redness, not only from the usual sclerotic circumcorneal injection, which is great, but also from considerable conjunctival injection—the brick-red color of which may obscure the rose tint of the sclerotic injection. Through the dim and muddy-looking cornea, and aqueous humor, the iris is seen dull, and changed in color, but more intensely so than usual on account of the greater vascular congestion, especially at its inner circle, where the color is reddish-brown or tawny. The surface of the iris may present small points of extravasation of blood.

Besides these changes, there may be deposits of lymph free on the surface of the iris. New vessels may be developed in this lymph, which then presents the appearance of reddish-brown or yellow tubercular excrescences. Exudation into the substance of the iris causes swelling of it.

Abscess is apt to form in such cases, as above described (p. 100), which bursting, gives rise to hypopyon.

The pupil is found variously altered—fixed, contracted, angularly distorted; displaced upwards and inwards, more or less filled with lymph, its margin retracted and adherent to the capsule of the lens.

Subjective symptoms.—During the day, there is in general not much pain, but at night the paroxysms of circumorbital or temporal pain are sometimes peculiarly severe. There is intolerance of light and lacrymation. Sometimes, however, there is neither pain nor intolerance of light. Vision is considerably diminished in consequence of the great obstruction of the pupil, but it is still more disturbed if the posterior tunics have become implicated, in which case there is, moreover, photopsy.

State of health and general symptoms.—Besides the iritis, there are usually, though not always, other secondary symptoms present, such as eruptions, papular, scaly, tubercular, or pustular, ulceration of the throat and mouth, periosteal swellings, and pains in the limbs.

Constitutional symptoms attendant on the iritis.—There is usually inflammatory fever. Sometimes very little or none at all.

Both eyes generally suffer—one eye becoming affected after the other.

The disease is often insidious in its attack, commencing with slight symptoms. It may then assume an acute character, or, with symptoms still mild, continue to observe a chronic but not less destructive course.

Causes.—The constitutional disease appears to be, in some cases, both predisposing and exciting cause, but in other cases, the disease is excited by some occasional cause, such as exposure to cold, over use of the eyes, a slight injury, &c.

Diagnosis.—Though the tawny color of the smaller ring of the iris, the angular distortion and displacement upwards and inwards of the pupil, and the presence of the lymphy deposits on the surface of the iris, may some of them be met with in cases of iritis, not syphilitic, and may some of them be absent in syphilitic cases, they, nevertheless, are of such frequent occurrence in syphilitic iritis, that their presence alone constitutes strong ground for suspecting the nature of the case, and for inquiring as to whether or not other secondary symptoms exist. If such do exist, the nature of the case can no longer be doubtful.

Prognosis.—This is a very dangerous form of iritis. Left to itself, or inefficiently treated, it may spread to other parts, such as the choroid, retina, vitreous body, &c., and occasion disorganization of the whole eye, with consequent loss of vision.

In otherwise healthy persons, if timely and properly treated, the disease may be perfectly cured. It often, however, happens, especially when the health has been much pulled down by the general disease, that even when the iritis has been subdued, the eye remains for a long time weak, and relapses are liable, from slight causes, to be excited.

Treatment.—Bleeding and mercurialization are the great remedies in this as in rheumatic iritis—the mercurialization, however, not solely because the disease is syphilitic. The venesection may require to be repeated more than once, and the mercury (calomel and opium) must be pushed until decided salivation. After this the mercury may still be required to be continued in smaller doses, to promote the removal both of the effects of the iritis and of the constitutional disease.

Besides belladonna, to oppose the contraction of the pupil, anodyne frictions are made, as above prescribed in rheumatic ophthalmia and iritis, around the orbit or on the temple, to assist in mitigating the nocturnal pain.

When the disease has been checked by the bleeding and mercury, blisters are useful.

When, as sometimes happens, it is not advisable to push mercury to the necessary extent, or when mercury does not exert its usual curative effects, turpentine, in drachm doses, three times a day, is the next remedy on which most dependence can be placed in subduing the iritis.

Iodide of potassium may be also tried under such circumstances. It may be given in doses of three or four grains, in compound decoction of sarsaparilla, three times a day. [Doses amounting at least to ten grains, three or four times a day, are the best, if they can be borne. They should be taken in not less than a gill of syrup and water, before meals and never at bedtime.] In any case it is necessary to follow up the mercury with the iodide of potassium.

Arthritic iritis.[1]

In this, as in syphilitic iritis, the inflammation involves the substance of the iris (*parenchymatous iritis*).

Objective symptoms.—The redness of the white of the eye, which is owing not to sclerotic only, but also to considerable conjunctival injection, inclines to a livid tint. This is owing to the venous character of the conjunctival congestion, including the

[1] Ophthalmia arthritica interna anterior.

varicose enlargement of the rectal veins. Sometimes also to a dark tinge of the sclerotica.

Between the margin of the cornea and the redness of the white of the eye, there usually intervenes, either at the nasal and temporal sides only, or all around, a narrow bluish-white space, forming a more or less perfect ring round the cornea. Under the impression that this appearance is peculiar to arthritic inflammation of the eye, it has been named *arthritic ring*, but improperly, as above shown (pp. 54, 55).

This disease being a parenchymatous iritis, the iris is not only dull and discolored as usual, but also swollen, especially at the pupillary margin, which becomes retracted and adherent to the capsule of the lens, while the middle part of the iris is bolstered forward towards the cornea.

The pupil, at first contracted, may become filled with lymph, mixed, perhaps, with blood, and angularly distorted—sometimes wholly closed.

In consequence of the considerable degree of conjunctival congestion, there is some increased mucous secretion, and in consequence of the affection of the borders of the eyelids, which are red and swollen, there is increased Meibomian discharge. These matters, by the movements of the eyelids, collect towards the angles of the eyes, in the form of a whitish foam, which has been named *arthritic foam*, as if the appearance were peculiar to arthritic inflammation of the eye; but it is not, for the same appearance presents itself in other cases of ophthalmic inflammation.

Subjective symptoms.—Sometimes an attack of the disease is preceded by formication in the skin of the face, and a tingling sensation about the eye. Dependent on the conjunctival injection, there may be the sensation of a foreign body in the eye. There is also a feeling of fulness and distension of the eyeball; but the most distressing symptom is the racking pain, not only around the orbit and in the temple, but over the whole side of the head and face. It is most severe at night, but may not be wholly absent even during the day.

Intolerance of light exists to a greater or less degree, accompanied by lacrymation.

Vision is impaired only in proportion to the exudation into the pupil, except when the posterior tunics are involved (see below), when it is impaired to a much greater degree or even lost.

Usually one eye only is affected.

Constitution, state of health, and constitutional symptoms.—The persons who become affected with this disease are usually middle-aged, and of broken down constitution. They may or may not have been the subjects of regular gout. The disease when formed is attended by considerable inflammatory fever.

Causes.—The state of constitution just described may be viewed as the predisposing cause, and sometimes as exciting cause also, seeing that the disease may come on without any evident external exciting cause. More frequently, an inflammation of the eye being called forth by some exciting cause, such as over-exertion of the sight, damp and cold, &c., the state of the constitution causes it to assume the arthritic character. The patient will often be found to have suffered from previous attacks of inflammation of the eye.

Diagnosis.—The local symptoms and the state of the constitution point to the arthritic character of the disease; but the form of arthritic iritis under consideration requires to be distinguished from that which is a radiation or extension of *arthritic inflammation of the posterior tunics.* The principal ground of diagnosis is, that in the latter case, along with irregular gout, the primary symptoms indicate posterior internal ophthalmia, such as sclerotic redness at the circumference of the eyeball, diminishing towards the cornea, photopsy, and rapid diminution of vision. Consequently the pupil, when the disease extends from the posterior tunics, instead of being contracted, is dilated (and this perhaps more in one direction, so that it presents an oval shape), and is not the seat of so much, if any, lymphatic exudation; the lens, however, is seen to have become glaucomatous and enlarged, so that it projects through the dilated pupil.

Prognosis.—This is a very dangerous form of iritis—not only because the pupil is apt to become contracted and obstructed by exuded lymph, but because the inflammation is very obstinate, prone to relapse, and after several attacks, to spread to the choroid, retina, &c., and totally destroy vision.

Treatment.—Though this inflammation is so dangerous to the eye, and is attended by such severe symptoms, the state of the constitution is usually such, that the active treatment by bleeding and mercurialization, so beneficial in other cases of iritis, requires to be very cautiously employed.

After bleeding and mercurialization, so far as they may have been considered safe, or if they have not been employed at all, colchicum may be tried, given as above described (p. 135).

To relieve the racking pain, friction is to be made with one or other of the substances above mentioned (p. 136).—Sometimes one, sometimes another, will be found more efficacious. No application should be made to the eye itself.

The diet should be at first restricted, but when the violence of the inflammation has subsided, it may be improved, though it should still be temperate and carefully regulated. Tonics may also be given—for instance bark, and soda, five or ten grains of each, or two grains of disulphate of quina two or three times a day.

Counter-irritation behind the ear, or on the nape of the neck, is a very useful and necessary part of the treatment, but only when the disease has begun to decline.

GENUS III.—CRYSTALLINO-CAPSULITIS ANTERIOR.[1]

Crystallino-capsulitis anterior.

In this inflammation, the uvea, as the anterior wall of the capsule of the lens, is affected—hence the disease is also named *irido-periphakitis*.

The anatomical characters have been above given (pp. 102–107).

It in general observes a chronic course, and the symptoms are by no means strongly marked.

Objective symptoms.—There is not much external redness. The iris is slightly or not at all discolored, though, perhaps, dull-looking; the pupil, bordered by a fringe of uvea, is somewhat contracted, irregular in form, and either fixed or very sluggish in its movements. On close examination, patches of opacity, some of them tinged of a brown color, may be seen on the anterior wall of the capsule, with minute vessels terminating in them. If belladonna be applied, and the pupil yields to its influence, the few red vessels which were previously seen coming from behind it, are discovered to be derived from a looping network on the crystalline, forming an interrupted circle concentric with the pupil. This network may appear to the naked eye like mere brownish-red patches, but by the help of a magnifying glass of one inch or one half inch focus, these patches are discovered to be vascular. Between these vascular networks on the anterior wall of the capsule, and the membrane on the posterior surface of the iris, vascular bands of adhesion may extend, preventing the free dilatation of the pupil.

Subjective symptoms.—The dull pain in the eye and head which attends this inflammation is seldom such as to cause much distress; and any intolerance of light is so little, that the examination of the eye is not attended with much uneasiness. Muscæ volitantes, and photopsy, however, sometimes disturb the patient, and the dimness of vision is greater than the mere suffusion of the lens would alone indicate.

Prognosis.—In the early stage of inflammation of the anterior wall of the capsule, resolution is sometimes brought about; but, when the disease has existed for some time, it remains very obstinate.

Treatment.—The general treatment employed in anterior internal inflammation of the eye, viz., depletion, mercury, counter-irritation,

[1] Inflammation of the membrane of the posterior chamber of the aqueous humor—Irido-periphakitis.

and belladonna, in the early stage, and tonics in the latter stages, are the remedies which suggest themselves; but their employment must be regulated and modified according to the circumstances of the case.

Dr. Mackenzie mentions the following circumstances in regard to a case of inflammation of the anterior hemisphere of the capsule, which he treated. On the first day of his being called in, two minute reddish spots were seen projecting from behind the edge of the pupil. Next day there were five. In the course of a week, the symptoms totally disappeared, under the employment of venesection, leeches, calomel with opium, and belladonna. The mouth was made very sore. In the chronic stage, Dr. Mackenzie confesses, however, that this inflammation has in his hands proved one of the most obstinate.

Order III.—Ophthalmia interna posterior.

The anatomical characters of ophthalmia interna posterior, so far as they have been observed by means of the ophthalmoscope, have been above indicated (p. 103, et seq.) There are no objective symptoms pathognomonic of it. As subjective symptoms, there may be photopsy, dimness of vision, deep distending pain in the eyeball, intolerance of light, and headache. Of all these symptoms, the dimness of vision is the most constant.

As shown in p. 155, posterior internal ophthalmia may arise and proceed to diminution or destruction of vision in one eye, so insidiously, that the patient perhaps becomes aware of his malady only by accidentally shutting the opposite eye. On the other hand, the disease may run its course with such rapidity and severity, as, amidst great suffering, to destroy vision in the course of one night. Hence the distinction of ophthalmia interna posterior into acute and chronic.

Ophthalmia interna posterior may arise primarily or secondarily.

In primary ophthalmia interna posterior, an extension of the inflammation usually ere long takes place to the anterior segment of the eyeball. It is of the ophthalmia interna anterior thus supervening that the sclerotic circumcorneal injection which presents itself is symptomatic, not of the posterior internal inflammation. Such cases of ophthalmia interna posterior, with secondary ophthalmia interna anterior, are distinguished from primary ophthalmia interna anterior, by the changes in the anterior segment of the eyeball not being such as to account for the diminution or loss of vision, and by this diminution or loss of vision, having occurred, perhaps, before the changes in the anterior segment took place.

Secondary ophthalmia interna posterior arises by extension of inflammation in ophthalmia interna anterior.

Though genera of posterior internal ophthalmia are above admitted, it must be confessed, that in practice there is considerable uncertainty as to their diagnosis. Even the revelations of the ophthalmoscope do, as we have seen, little more than establish the existence of mischief at the bottom of the eye—the result: in one case, perhaps of choroiditis; in another, of retinitis; and in a third, of both combined.

There are no marked objective symptoms, as distinguished from anatomical characters, whereon to found a differential diagnosis between choroiditis and retinitis for example.

As to subjective symptoms, again, though there is reason to believe that photopsy is owing to pressure on the retina by an inflamed choroid, and dimness of sight alone occasioned by retinitis, these symptoms can scarcely be admitted as pathognomonic. Whilst pain appears to be dependent rather on the acuteness of the inflammation, and the degree to which other parts besides the choroid and retina may have become implicated, as above deserved.

Whatever advance may be made in the critical diagnosis of choroiditis, retinitis, &c., considered as genera of posterior internal ophthalmia, all that is really of importance practically, is to discriminate certain forms of posterior internal ophthalmia, characterized principally by the state of the constitution, or by the constitutional disease with which the ophthalmia appears to be connected, and by the course and effects of the inflammation.

The principal forms of posterior internal ophthalmia met with are:—1. Those cases of diminution or loss of vision above referred to (p. 155), as being sometimes described as cases of chronic iritis, and which are also sometimes described as retinitis. 2. Those cases which end in sclerotic staphyloma and posterior hydrophthalmia, and which are described by Dr. Mackenzie under the name of sclerotico-choroiditis. 3. Those cases which end in glaucoma, and which are described as forms of arthritic ophthalmia. 4. The cases in which there are no other than the subjective symptoms of diminution and disturbance of vision, but in which mischief at the bottom of the eye is detected by means of the ophthalmoscope.

These forms of ophthalmia, being usually of a chronic character at first, are seldom seen by the medical man, until, being already formed, they manifest themselves by their effects, or, becoming acute, by the severity of the subjective symptoms.

The two first forms might perhaps be viewed merely as different degrees of the same kind of posterior internal ophthalmia, and this might be named *scrofulous posterior internal ophthalmia*. The

third is a form of arthritic ophthalmia, and may be named *arthritic posterior internal ophthalmia* in contradistinction to arthritic iritis or arthritic anterior internal ophthalmia. The fourth has been hitherto referred to the indefinite head of amaurosis; but practically, may be considered under the head of scrofulous, or arthritic posterior internal ophthalmia, being merely a degree of the one or the other.

Scrofulous posterior internal ophthalmia.

Dimness of vision in a greater or less degree is the symptom which generally first seriously attracts attention. Fixed muscæ, photopsy, headache, intolerance of light, may or may not be precursors or accompaniments.

Objective Symptoms.—When, in consequence of these subjective symptoms, an examination of the eye is made, it will probably be found that the pupil is slightly dilated and sluggish or immovable, and its margin adherent by bands of lymph to the capsule of the lens. It will perhaps also be found that there is some external redness in the form of a sclerotic circumcorneal blush, which, together with the state of the iris and pupil, is a manifestation of the supervention of anterior internal ophthalmia.

In addition to these appearances, it will perhaps be observed that the sclerotica is attenuated and dark-colored, and that the white of the eye is pervaded by enlarged and tortuous recto-muscular vessels, ramifying towards the cornea. The cornea itself, perhaps, presents minute points of opacity.

The eye may never undergo any farther change than what is above described.

In some cases, on the contrary, especially after repeated acute attacks, manifested by actual inflammation of the sclerotica (p. 91), the latter membrane, in some part of its extent,—perhaps over the region of the ciliary body,—becomes more attenuated and darker colored, and bulges out here and there, forming sclerotic staphyloma. This is owing to a collection of fluid at the place, either between the sclerotica and choroid, or between the choroid and retina, or within the retina.

Towards the side next the sclerotic staphylomatous projection, the pupil may be displaced, and on the same side patches of opacity frequently form in the cornea.

The iris is sometimes little, sometimes much, implicated; in the latter case it is bolstered towards the cornea, and the pupil and posterior chambers are filled with lymph.

Degenerated and enlarged, the eyeball protrudes more or less from the orbit.

Subjective symptoms.—In the course of these changes, in addition to the dimness of vision and photopsy, &c., there is pain over the eyebrow and in the temple. Eventually vision becomes dimmer and dimmer until it is entirely lost.

In this stage of scrofulous posterior internal ophthalmia, remissions and exacerbations of the inflammation occur. During an exacerbation, the white of the eye is of a purple color, from the blending of the dark tint of the attenuated sclerotica and the red color of the injected vessels. There is very severe pain in the eyeball, in and around the orbit, and over the whole side of the head, with intolerance of light and lacrymation.

Constitutional symptoms.—To these local symptoms is added considerable constitutional disturbance.

Causes.—This form of posterior internal ophthalmia is met with principally in young adults of scrofulous constitution, more frequently females than males, and is commonly attributable to overuse of the eyes, with neglect of exercise, derangement of the stomach and bowels, disturbed menstruation, &c. Traumatic inflammation of the eye sometimes takes this form.

Diagnosis.—This may be inferred from what has been above said.

Prognosis.—The prognosis, as regards vision, is unfavorable; in the more advanced stage very much so. Still it does sometimes happen that the disorganizing progress of the inflammation is arrested, and some degree of vision preserved or restored.

Treatment.—If the case be seen early, venesection or cupping, according to the strength of the patient, free action on the bowels, and mercury pushed so as to affect the gums, constitute the proper treatment.

In the more advanced stages of the disease, the tonic and alterative treatment—the bichloride of mercury, in doses of one-thirtieth to one-sixteenth or one-eighth of a grain, three times a day, in tincture of bark; or the arseniate of potass, in doses of one-thirty-secondth of a grain, either in the form of Fowler's solution or in that of a pill—with counter-irritation, should be tried. The abstraction of blood by leeches may still occasionally be necessary.

During an exacerbation of the inflammation, the belladonna lotion (p. 69) is an excellent application to the eye. Under its use alone I have seen the inflammation diminish, and the pain and intolerance of light rapidly relieved.

When there is staphylomatous bulging of the sclerotica, the repeated evacuation of the accumulated fluid by puncture is sometimes had recourse to. See *Sclerotic Staphyloma.*

Arthritic posterior internal ophthalmia.

This disease occurs both in an acute and in a chronic form. The acute form may supervene on the chronic, or come on all at once. The chronic form usually comes on of itself unpreceded by the acute form.

The acute differs from the chronic disease principally in the greater rapidity with which it leads to the organic changes, causing destruction of the function of the eye,—vision being destroyed in the course of a few days, sometimes even in a single night; and in a correspondingly greater severity of the subjective symptoms.

Keeping in view the differences in the rapidity of their course, the following description of the objective symptoms is applicable to both the chronic and the acute form; but as regards the subjective symptoms, it will be necessary to give a separate description of them, both as they occur in the chronic, and as they occur in the acute form.

Objective symptoms.—The most characteristic of these at first is, the state of the pupil, which is sluggish or fixed, and dilated. Instead of being circular, it is sometimes of an oval shape;—the long diameter being transverse, or vertical, or diagonal—most commonly transverse. The pupillary margin of the iris is bordered with pigment.

A dimness is seen through the dilated pupil, and, on careful examination, this is discovered to be owing to that peculiar deep-seated green opaque appearance of the lens called *glaucoma*. See *Glaucoma*.

The white of the eye, dark and dirty-looking, is at first pervaded merely by large livid tortuous vessels derived from the recto-muscular, but the inflammation spreading to the iris, the white of the eye becomes the seat of vascular injection, conjunctival as well as sclerotic, partially or completely round the cornea, but separated from it by the bluish-white ring above referred to (pp. 54, 55). The resulting redness is of a livid tint.

The iris, which was at first merely dull-looking, becomes changed to a slate color, pervaded by varicose vessels, its pupillary margin retracted, its middle part inclined towards the cornea. There is no exudation of lymph.

The cornea may become dim and rough on its surface, like ground glass.

The eyeball is hard to the touch.

The sclerotica becomes attenuated here and there, and perhaps bulges out, constituting sclerotic staphyloma.

The lens may become cataractous (glaucomatous cataract), and protruding through the dilated pupil, sometimes presses against the cornea.

Subjective symptoms of the chronic forms.—Considerable dimness of vision, with photopsy, attracts the patient's attention, but so far from having intolerance of light, the patient sees best in good light. There may be at first no pain, at the most, uneasiness in the eyes, but in the progress of the disease a feeling of distension in the eyeball and occasional paroxysms of dull supra-orbital or circumorbital pain, distress the patient.

Bodily exertion or mental excitement or errors of diet, aggravate; rest and mental tranquillity, and moderate nutritious diet, mitigate the symptoms.

Diminution of vision goes on, sometimes gradually, sometimes suddenly, the photopsy at the same time increasing, and continuing even after vision is lost. Vision after being almost lost, is sometimes improved after an attack of gout.

Subjective symptoms in the acute form.—Severe burning, bursting pain in the eyeball, and racking pain in the supra-orbital or circumorbital region, in the temples, and from thence extending over the whole side of the head. The pains are severest towards midnight.

There is much intolerance of light, accompanied by lacrymation and the sensation as if a foreign body were in the eye.

With great photopsy, vision rapidly becomes dimmer and dimmer until all sensibility to external light even is lost, though the photopsy may still continue.

General symptoms.—In the chronic disease the system does not sympathize much, but in the acute disease there is severe inflammatory fever.

Predisposing causes.—This disease occurs in persons advanced in life—more frequently females than males—and who have not been previously quite healthy, having been perhaps the subjects of irregular gout, derangement of the digestive organs, piles, headaches, gutta rosacea, or the like.

In such persons the eyes have seldom remained altogether sound; the borders of the eyelids are swollen and pervaded by large vessels; the white of the eye is dark and dirty-looking, and pervaded by large varicose vessels derived from the rectal, filled with dark blood, the iris inclined towards the cornea, with the pupil rather large and sluggish, whilst a sensation of fulness is experienced in the eyeball; muscæ and temporary dimness of vision are apt to be occasioned by stooping, by being heated, &c.

Exciting causes.—In persons in the state of general health, and with the state of eyes above described, ophthalmic inflammation, induced by any common occasional cause, is prone to assume this form.

As more special causes may be mentioned, suppressed gout,

anxiety, and mental distress, suppression of hæmorrhoidal discharge, in the female the cessation of menstruation, the suppression of any other habitual discharge, continued over-exertion of the eyes, strong light, cold.

Both eyes may be attacked at once, but the inflammation is more severe in the one than the other. More usually one is first attacked and vision destroyed, and afterwards the other. One eye may however be spared.

Diagnosis.—This disease during its active state is to be distinguished from arthritic anterior internal ophthalmia (p. 162, et seq.) and the state in which the eye is left by it must be distinguished from cataract and amaurosis, properly so called.

The *Prognosis* is altogether unfavorable. Treatment has little influence on the disease. At the most it can merely mitigate or retard. Vision is sure to be abolished by a renewed attack. Eventually the eyeball may be destroyed.

In a woman about seventy the right eye was affected severely as above described (pp. 171, 172); the white of the eye pervaded by tortuous vessels, the cornea dim and rough, the pupil dilated and fixed, the lens glaucomatous and cataractous, and the eyeball hard to the touch, while vision was completely abolished. The left eye was in the state of predisposition above indicated. A new and severe attack of inflammation, attended by the subjective symptoms described in p. 172, supervened in the right eye, the consequence of which was that the cornea became infiltrated with matter, and at last gave way, allowing of partial evacuation of the humors, so that the eyeball shrank to a stump in the socket, with relief to the suffering. But inflammation supervening in the left eye, though with milder symptoms, vision in it was soon completely annihilated. On examination, the pupil was seen much dilated, and the lens glaucomatous.

Treatment.—The subjects of this disease do not bear much bleeding or mercurialization.

In the chronic form the occasional application of leeches may be necessary. The bowels having been freely opened by means of hydrarg. c. creta (gr. iij) and aloes (gr. j), with extract of hyoscyamus) gr. ij, followed by salts and senna, a mercurial alterative course may be commenced: the bichloride of mercury in doses of one-sixteenth to one-twentieth of a grain, three times a day, in tincture of bark and syrup of sarsaparilla. Counter-irritation should be kept up by means of blisters on the nape of the neck.

When there is much circumorbital or temporal pain, opiates internally and the anodyne frictions above recommended are to be had recourse to (p. 161).

During this treatment the diet should be light but nutritious,

and care taken to keep the bowels, the kidneys, and skin in good order, while rest and quiet should be enjoined.

Subsequently tonics will be useful.

In the acute form of the disease, if there is time for treatment, it should be the same as that above recommended for arthritic iritis, viz., bleeding and mercurialization, but employed with still greater precautions. If fortunately the violence of the disease be subdued before destruction of the eye, the subsequent treatment should be the same as just recommended for the chronic form of the complaint.

The following case is an example of the acute form, though not of the severest kind:

A woman æt. 55, had been out of health and in a desponding state for three months, when one day in the early part of December she attended a funeral, and was exposed for a considerable time to the cold air. This was followed by an attack of inflammation of the right eye, and a fortnight after a similar attack in the left.

There was both conjunctival and sclerotic injection. The surface of the cornea somewhat rough and dim. The iris inclined towards the cornea. Pupils dilated and irregular, and behind them a glaucomatous appearance.

The borders of the eyelids were red and swollen.

Impairment of vision and severe circumorbital pain were the subjective attendants on these objective phenomena.

After a fortnight's treatment, vascularity was much diminished, the sight improved, and pain all but gone. A week after this the report was, quite free from pain—vision greatly improved.

In the course of the succeeding month, however, there were alternate relapse and improvement; and although all active inflammation subsided, and the general health improved considerably, congestion, and the dilatation of the pupils with the glaucomatous appearance behind them continued, and the sight, instead of getting better, gradually became worse.

The treatment under which the temporary improvement took place principally consisted of cupping to ℥vj, ten grains of Dover's powder for some nights at bedtime—on two occasions combined with two or three grains of calomel—occasional laxatives, colchicum with magnesia, and afterwards a mixture of gentian with sulphuric acid. Friction with tincture of tobacco, and blisters to the nape of the neck and behind the ears were applied.

Order IV.—PANOPHTHALMITIS.

Panophthalmitis is inflammation of the whole eye. Primary panophthalmitis, *i. e.* inflammation invading the whole eye at once,

is of rare occurrence. Most commonly, panopthalmitis is secondary, being developed by extension of inflammation from one structure to another, as has been seen may take place in some of the ophthalmiæ above considered, especially the posterior internal.

As has been above said, panophthalmitis is genus as well as order.

GENUS.—PANOPHTHALMITIS.

The species or form of panophthalmitis which it is purposed to consider here is phlegmonous panophthalmitis or ocular phlegmon.

Phlegmonous panophthalmitis.

Objective symptoms.—The eyelids are red and swollen, especially the upper. There are inflammatory swelling of the cellular tissue of the orbit around the eyeball, and chemosis of the conjunctiva, in consequence of which the eyeball is fixed and protrudes from the orbit, stretching the upper eyelid and depressing or everting the lower.

If the cornea is still transparent enough to allow the iris to be visible, this is seen to be discolored and the pupil contracted and fixed.

Subjective symptoms.—Dimness of vision, independent of changes in the cornea and pupil, and photopsy, are indicative of the retina and choroid being involved in the inflammation.

As might be expected from the great distension of the eyeball from within, and the pressure to which it is subjected from without, the suffering is very severe. Besides the hot burning pain in the eyelids and the whole region of the eye, aggravated by the slightest touch or attempt at motion, there is deep distending throbbing pain in the eyeball as if it would burst, pain in the orbit extending to the back of the head, pain around the orbit, in the temples, or all over the side of the head and face. There is also great intolerance or light, with lacrymation.

Constitutional symptoms.—Inflammatory fever and sometimes delirium accompany the disease.

Course.—In this stage the inflammation may be arrested, in which case, with diminution of the pain, the swelling of the eyelids, the prominence of the eyeball and the chemosis subside. In proportion as the redness of the white of the eye is dissipated, any ulceration of the cornea heals, the iris recovers something of its natural appearance, but the sight remains more or less impaired, if not abolished.

If this favorable turn is not brought about, but, on the contrary, the disease advances, all the symptoms become aggravated, and

suppuration takes place; being ushered in by a feeling of weight and cold in the eye, and general rigors.

In consequence of accumulation of matter in its interior, the eyeball becomes much distended and enlarged, so that it protrudes still more from the orbit. The cornea is infiltrated with matter, and projects from the bottom of the fossa formed by the chemosed conjunctiva.

With the supervention of suppuration the suffering not only does not abate, but actually increases, in consequence of the strong outer tunics of the eyeball not readily yielding to the distension from the accumulated matter. At last, however, the eyeball bursts by the cornea or sclerotica giving way, and the abscess, together with blood and the humors of the eye, are evacuated. The pain which before this was of the severest character, is now at once greatly relieved and afterwards gradually subsides.

Causes.—This disease of the eye usually occurs in young robust individuals, in consequence of the intense operation of those causes of ophthalmic inflammation in general, which act directly on the eyes as above mentioned (p. 108), especially injuries, chemical or mechanical. The disease, as it occurs in connection with phlebitis, is described below under the name of *phlebitic ophthalmitis*.

Prognosis.—It is only when the disease is early and actively treated, that the eye can be saved as an organ of vision. When the disease has already made some progress, preservation of the form of the eye will perhaps be all that can be hoped for; the retina having been disorganized. When suppuration has taken place, even this can no longer be calculated on. If the eyeball be allowed to burst, the humors will be evacuated along with the matter, the tunics will therefore be permitted to collapse, and after cicatrization nothing of the eyeball will remain but a small stump at the bottom of the orbit.

Treatment.—Bloodletting, mercurialization, and opiates—incision of the chemosed conjunctiva (p. 78), evacuation of the aqueous humor, belladonna lotion, and anodyne frictions around the orbit or over the temples, &c., constitute the treatment, which must be carried into effect with vigor in the commencement of the disease, if the eye is to be saved. Subsequently, when suppuration threatens or has commenced, all that can be done is to apply a poultice, and when the abscess becomes prominent at some point, to evacuate it by puncture with a lancet, in order to relieve the suffering, and perhaps save as much of the eyeball as will form a stump for the support of an artificial eye. Puncture of the eyeball with a lancet may even be advisable before this, to relieve suffering by removing tension. After this it will be necessary to support the system with generous diet and tonics.

APPENDIX TO THE PRECEDING SECTION.

There are certain febrile and inflammatory diseases, viz., the exanthemata, hooping-cough, a particular form of epidemic fever, and phlebitis, in the course of or subsequent to which, inflammation of the eyes is apt to supervene. The inflammation is commonly named morbillous, scarlatinous, variolous, postfebrile, or phlebitic ophthalmia, or ophthalmitis, according to the general disease with which it is connected. It is, however, to be observed that in these cases the ophthalmia is essentially the same as some of the forms above described, being not only not a specific inflammation, but not even always of the same kind in different cases of the same general disease; thus exanthematous ophthalmia is sometimes phlyctenular, sometimes puromucous, sometimes even internal.

Whilst therefore the practitioner, in treating the general diseases above mentioned, must be prepared to encounter supervening ophthalmic inflammation, he must also be prepared to find that inflammation, more or less different in kind in different cases of the same disease, and requiring, therefore, different modes of treatment—modes of treatment, however, not differing from those above indicated for the particular species or form of inflammation, except in so far as is necessitated by the presence of the general disease.

Scarlatinous and morbillous ophthalmia.

An inflammation of the eye is apt to occur in scarlet fever and in measles, more frequently in the latter than the former, which usually resembles the phlyctenular or scrofulous ophthalmia, though sometimes it assumes the puromucous character, or even runs into internal inflammation. In general the inflammation is mild, but phlyctenulæ, or even abscess of the cornea, followed by more or less destructive ulceration of it, may take place.

Diagnosis.—Scarlatinous and morbillous ophthalmiæ in their commencement so much resemble scrofulous ophthalmia, that they might be taken for it before the general disease has declared itself by eruption. When this has taken place, the scarlatinous and morbillous nature of the ophthalmia will, of course, also be evident, irrespective of any differences in their nature in other respects, which may present themselves.

Prognosis.—Although, in general, these ophthalmiæ subside with the general disease, under very simple treatment, they should be as carefully watched as if they were idiopathic affections. By neglect, very serious or irretrievable injury may take place by ulceration of the cornea, to the extent even of its destruction, and the formation of staphyloma.

Scarlet fever and measles are apt to leave behind them a tendency to ophthalmia, especially scrofulous ophthalmia, ophthalmia tarsi, and blennorrhœa of the lacrymal passages.

Treatment.—The general treatment necessary for the general disease answers for that of the ophthalmia. Tonics may be necessary to promote convalescence.

The local treatment of the inflammation of the eye is to be conducted on the principles laid down for the idiopathic ophthalmia which it may more particularly resemble.

Variolous ophthalmia.

This is generally of a much more severe and dangerous character than the other exanthematous ophthalmiæ, as used to be exemplified with such lamentable frequency before the introduction of vaccination.

Variolous ophthalmia most commonly puts on a form resembling scrofulo-catarrhal ophthalmia, with more of the phlyctenular than catarrhal characters (p. 148), or catarrho-rheumatic ophthalmia. Sometimes it is a purulent ophthalmia. Sometimes the internal tunics are implicated.

It is about the eleventh or twelfth day or later from the first appearance of the eruption, and when the secondary fever has commenced, that the ophthalmia most commonly comes on.

There is conjunctival and sclerotic redness, accompanied by heat, pain, and the sensation as if a foreign body were in the eye, and intolerance of light, with lacrymation. Exudation takes place into the substance of the cornea; pustules or abscesses form and burst, and by the extension of the ulceration which supervenes, the cornea may be penetrated or destroyed to a greater or less extent.

When the disease puts on the form of purulent ophthalmia, this unfortunate result is still more apt to ensue.

The period of invasion of this ophthalmia being when the general eruption is on the decline, the pustules or small abscesses which are so apt to implicate the cornea ought not, Drs. Gregory and Marson justly insist, to be viewed as of a specific nature, like the pustules of the skin, but merely of the same nature as those which may occur in any acute external ophthalmia.

In the eruptive stage of small-pox there may be some degree of conjunctivitis, but this is neither frequent nor dangerous. When there are many pustules on the eyelids and their margins, indeed, the swelling may be so great that the eyelids cannot be opened, and there may be an increased Meibomian secretion, by which the edges of the eyelids are glued together and the eyelashes incrusted; but there is not much lacrymation, little or no pain in the eye or

manifestation of intolerance of light, and when at last, on the fading of the eruption, and subsidence of the swelling, the eyelids admit of being opened, the eyeball is found quite safe, the conjunctiva perhaps being merely somewhat injected, and the seat of a little increased mucous secretion.[1]

Small-pox, like scarlet fever and measles, leaves behind a tendency to catarrhal and phlyctenular ophthalmia, ophthalmia tarsi, blennorrhœa of the lacrymal passages, &c.

Treatment.—As a prophylactic measure during the eruptive stage, any matter which collects at the borders of the eyelids is to be frequently washed away by means of tepid water, and after each ablution, some mild ointment is to be smeared along the borders of the eyelids.

Ophthalmia having declared itself, the plan of treatment must be that adapted to the particular form which it has assumed.

When the inflammation has begun to abate, tonics and generous diet will be useful. If the system of the patient be in an exhausted state, good diet, cordials, and tonics, as far as they can be pushed, will be necessary from the first.

When the cornea is opaque, perforated by the ulceration or altogether destroyed, the prognosis and treatment of the case come under the heads of *opacities of the cornea, prolapsus iridis,* or *staphyloma iridis.* [See Hay's Lawrence, p. 329, 1854, for a good account of secondary or post-variolous ulceration of the cornea, quoted from a paper by Dr. I. Parrish, in the Transactions of the College of Physicians of Philadelphia, p. 335, July, 1852. The ulcerations of the cornea following this and the other eruptive fevers are apt to be extremely obstinate. They are nearly always attended with a depressed condition of the system, and consequently require a tonic course of treatment, with mild unperturbating applications to the eye, notwithstanding the occasional severity of the local irritation. In the great majority of cases, reducing measures, such as are frequently resorted to, will only protract the disease.]

Postfebrile ophthalmitis.

A remittent fever, sometimes attended with petechiæ, but not with the measly eruption of typhus, often accompanied with jaundice, its first paroxysm coming to a crisis within seven days, a relapse happening almost invariably, but the patient rarely suffering more than two paroxysms, and the mortality not exceeding three and a half per cent., which prevailed very extensively in Edinburgh and Glasgow in 1843–4, and has prevailed at different times in Dublin, was apt to be followed by various sequelæ, of which

[1] The injury which may result to the eyelids from bad cicatrices is considered under the head of diseases of the eyelids.

the most remarkable was the affection of the eye to be here noticed.

This disease appears to be a form of posterior internal ophthalmia, usually but not invariably with extension of the inflammation to the anterior segment of the eyeball.[1]

Symptoms.—At a period, varying from a fortnight to five or six months, after recovery from the fever, the posterior internal ophthalmia declared itself by the subjective symptoms of muscæ volitantes, and more or less dimness of vision, increasing perhaps until merely a perception of light and shade remained. When anterior internal ophthalmia was superadded to the posterior internal, attention was more forcibly drawn to the disease, not only by the inflammation having become objectively evident, but by the accompanying ocular and circumorbital pain.

The greatest number of cases of this ophthalmia occurred in young adults. One eye alone was more commonly affected than both. Of the two eyes the right appears to have been the one which more frequently suffered.

Exciting cause.—The onset of the disease of the eye was generally traceable to some such exciting cause as exposure to cold, using the eyes too early after recovery from the fever, &c.

Prognosis.—When early and properly treated the disease was in general found to yield completely though slowly; vision being restored even when it had become already extinguished. When not thus treated, or altogether neglected, irremediable sequelæ were found to remain, such as imperfect vision, muscæ volitantes, sclerotic staphyloma, opacity in pupil, &c.

Treatment.—Bleeding, mercury, and belladonna at the commencement; and when the acuteness of the disease began to subside, counter-irritation and quina appear to have constituted the most successful treatment. Though the patients labored under general debility at the time, it was nevertheless found that unless abstraction of blood was had recourse to, the recovery was slow and imperfect.[2]

Phlebitic ophthalmitis.

This is a panophthalmitis occurring in cases of phlebitis, traumatic, puerperal, or of other origin.

In some cases the inflammation comes on slowly, and does not cause much distress to the patient, in other cases it comes on suddenly, and is attended by very severe symptoms. In either case, however, supposing the patient does not sink under the primary

[1] In some cases, the inflammation of the eye arose in and was confined to the anterior segment, being an anterior internal, or sometimes merely an external ophthalmia. There were therefore no amaurotic symptoms.

[2] For detailed accounts of Postfebrile Ophthalmitis, as it occurred in Glasgow, see the papers of Dr. Mackenzie in the "Medical Gazette" for Nov. 1843, and of Dr. A. Anderson, in the "London and Edinburgh Monthly Medical Journal" for October, 1845. [See also Mackenzie's Treatise on the Eye, Hewson's Am. Ed., p. 579.]

disease, the eye is either destroyed by suppuration and bursting of the abscess, or left amaurotic and atrophic.

The constitutional symptoms which attend this disease are those of the phlebitis, which are of a typhoid character.

The general circumstances of the case sufficiently distinguish phlebitic ophthalmitis from common phlegmonous panophthalmitis, or ocular phlegmon, to which, as regards local symptoms, it has, especially in its acuter form, a great resemblance. There is a difference, perhaps, in the appearance of the chemosis, which in phlebitic ophthalmitis has been remarked to have more of the character of serous chemosis; whilst the conjunctiva was pale rather than bright red, and in some cases at least, covered on its surface with an exudation of lymph in the form of a pseudo-membrane.

Treatment.—Considering the grave nature of the primary disease, the affection of the eye constitutes but a comparatively secondary consideration in the case. The general treatment proper for the phlebitis is that which is also proper for the ophthalmitis. The local treatment should be much the same as that above indicated for phlegmonous panophthalmitis.

Traumatic and sympathetic ophthalmia.

Inflammation of the eye excited by injury puts on one or other of the various forms above described. The particular form of ophthalmia excited depends partly on the seat and degree of the injury, and partly on the age, constitution, and state of health of the patient. The influence of constitution and state of health, for example, is shown by the circumstance that a similar injury may give rise to a severe internal ophthalmia in one person, whilst in another it may occasion a comparatively unimportant inflammation.

The treatment of traumatic ophthalmia must be conducted on the same principles as that for the corresponding forms of ophthalmic inflammation above described.

In certain cases, the eye injured does not alone become inflamed, the opposite eye ere long becomes affected also, and suffers as much, sometimes even more. This is considered owing to the sympathy which exists between the two eyes, and hence the inflammation supervening in the uninjured eye has been named *sympathetic ophthalmia.*

The traumatic ophthalmia on which sympathetic inflammation of the opposite eye is most apt to supervene, involves the internal textures of the eyeball, posterior as well as anterior; and the injuries which most commonly excite this degree of internal inflammation, are penetrating and lacerating wounds in the region of the ciliary body, especially with some loss of vitreous humor, and prolapse of the iris, inflicted by cutting instruments, or by the forcible

projection of splinters of iron or stone, or the fragments of percussion caps.

The sympathetic ophthalmia likewise involves the internal textures, more especially those of the posterior segment of the eyeball; hence diminution of vision and photopsy are early symptoms.

The period of time after injury of one eye, at which the sympathetic ophthalmia supervenes in the other, is generally five or six weeks.

Though the subjects of sympathetic ophthalmia are apparently healthy at the time of the original accident, they do not in general appear to be of sound constitution, for their health readily breaks up under the treatment necessary for the traumatic ophthalmia, and the debilitated state of health thus induced is perhaps one of the conditions which operate in predisposing to the sympathetic ophthalmia.

The sympathetic attack sometimes cannot be traced to any *immediate* exciting cause; sometimes it appears to have been brought on by using the eye too soon after the injury of the opposite eye.

The wounded eye in general becomes atrophic and amaurotic, and the sympathetically affected one pretty certainly shares the same fate, in spite of the most carefully conducted and appropriate treatment.

Sympathetic ophthalmia having hitherto proved so little amenable to treatment, the greatest attention should be paid to every case of traumatic internal ophthalmia, however slight apparently at first, in the hope of obviating an attack of sympathetic ophthalmia. And after the cessation of the traumatic ophthalmia, especial care should be taken by the patient not to use either eye much for a considerable time to come.

It has been supposed that injuries attended with the lodgment of a foreign body in the interior of the eye, are those especially which are followed by sympathetic inflammation. This is, however, not always the case, for the inflammation has been found to occur in cases of injury of the eye in which there could be no suspicion that any foreign body had become lodged in its interior, and sympathetic ophthalmia does not always supervene in cases of injury of one eye, even when it is certain that a foreign body is lodged in its interior.

SECTION IV.—VARIOUS MORBID STATES OF THE EYE, ACCOMPANIMENTS OR CONSEQUENCES OF THE OPHTHALMIÆ.

Granular conjunctiva.[1]

This morbid state of the conjunctiva of the eyelids and of the palpebral sinuses, presents an appearance something like that of a

[1] Granular eyelid—Trachoma.

granulating sore, hence the name, but its nature is altogether different, as above explained (pp. 89, 90).

According to the degree of development of the granulations, the surface of the conjunctiva on the eyelids and sinuses appears, when the eyelids are everted, like red velvet—the enlarged papillæ being separated into groups by furrows or fissures; or tuberculated and sarcomatous-looking, like a mulberry. I have seen granulations like small pedunculated polypi.

The ocular conjunctiva is not subject to the disease. Any granular appearance which it may present either over the sclerotica or cornea is owing to real granulations.

In consequence of the great tendency to granular conjunctiva in the puromucous ophthalmiæ (pp. 119, 121), the surgeon should never allow himself to omit the examination of the inside of the eyelids and palpebral sinuses after the subsidence of these inflammations, for, although the sclerotic conjunctiva may have become free from redness, the palpebral will still be in the morbid state under notice (p. 119).

Granular conjunctiva is often found even in cases in which the sclerotic conjunctiva has not been much, if at all, involved in the inflammation, for as above shown, the inflammatory congestion on which the development of granular conjunctiva depends, may never reach beyond the palpebral conjunctiva, and may be so slight as scarcely to have attracted the patient's attention (p. 121). On this chronic inflammation, however, an acute attack of ophthalmia from slight causes (p. 122), is liable to supervene.

Superficial vascularity, thickening, and opacity of the upper half of the cornea often exist along with granular conjunctiva, and have been attributed to the friction exerted on it by the rough surface. This does not, however, appear to be the case, for vascularity, thickening, and opacity of the conjunctiva cornea, are met with in cases in which granular conjunctiva does not exist, and may be absent in cases in which granular conjunctiva is much developed. The morbid condition of the cornea just mentioned, is rather the result of the extension of the same inflammation which first gave rise to the granular conjunctiva, though there can be no doubt that it is kept up and aggravated by the friction exerted by the granular surface of the palpebral conjunctiva (p. 123).

Prognosis.—Granular conjunctiva is a very intractable disease. Even under the most favorable circumstances, the conjunctiva is long of regaining, if it ever regains, its natural state.[1]

[1] In Ireland, ophthalmia, with granular conjunctiva, and all its train of disastrous effects on the sight, appears to be endemic. Many years ago, being in Cork, the frequency of the disease in that city and neighborhood was forced on my attention. To this, I have to add, that almost all the persons affected with granular conjunctiva who present themselves at University College Eye Infirmary, I find, on inquiry, to be from the South of Ireland.

Treatment.—In the treatment of granular conjunctiva, care and perseverance are required. Carefully conducted diet and regimen, tonics, good air, and protection from changes of weather, are important general points of treatment. The local treatment *should* consist of, 1st, the application of a leech or two to the eyelids [to the temples or behind the ears, or cups to the temples or nuchæ] occasionally to relieve congestion; 2d, counter-irritation, kept up by repeated blisters [or tincture of iodine] behind the ears and over the eyelids; 3d, scarification of the affected conjunctiva (pp. 76, 77) every second or third day, and immediately thereafter the application to it of some strong salve, such as the red precipitate. In scarifying, it is important to lay open the vesicular granulations, one after the other, by puncture. When fungous, the granulations, if large and prominent, and especially if pedunculated, may be at once snipped off with curved scissors. After the operation the salve is to be applied as after the scarification merely. [Occasional scarification to relieve congestion may be very beneficial, like leeching or cupping, in case of plethora or acute relapse; but our experience has satisfied us that, in this country at least, the use of the knife and scissors, as well as of leeches and cups, is often injurious, and that scarification is quite as liable to misuse as the bluestone.]

In the treatment of granular conjunctiva, bluestone, as above observed (pp. 74, 75), has been sadly misused. Though by it and other caustics, the granulations may have been destroyed, the conjunctiva has been too often destroyed at the same time. The inflammation, the cure of which ought to be the great object aimed at, has been in general rendered more hopelessly incurable. As to the powdered acetate of lead, I cannot speak of it from much experience.

[The local remedies which have been found the most useful with us, are the nitrate of silver in solution (gr. viij to ℈ij in the fluid ounce of distilled water, according to the nature of the case), sulphate of copper in the crystal, and liquor plumbi subacetatis in drops. The first of these, in solutions of varying strength, according to the stage and character of the disorder and the susceptibilities of the organ to be acted on, appears to be the most frequently available and beneficial in its operation. It may occasionally be used with advantage, even in the proportion of from three to six grains only to the fluid ounce of water, dropped into the affected eye, once or twice a day, or every two days. Nor can it be tolerated in any other strength, by some patients, especially in the summer season. Generally, however, we prefer resorting to the stronger solutions (from ten grains to thirty in the fluid ounce), used at longer intervals and applied with the camel's-hair pencil to the granular surface of the everted lids. This surface should be gently

wiped with a soft clean sponge or piece of lint; the pencil, charged with the solution, should then be lightly and rapidly drawn to and fro over the granulations, until they are whitened; after which, the surface thus painted should be once more carefully wiped, and the lid replaced. An application of this kind may be repeated, more or less freely, every two, three, four, or six days, according to the amount of irritation and other effects produced.

The liquor plumbi subacetatis is dropped into the eyes, or on the inner surface of the separated lids, in two or three drops at a time, every two or three days, according to circumstances, in the same manner as the weaker solutions of lunar caustic. Like the stronger solutions of this latter salt it must be used less frequently, and may also be laid on with the brush or pencil in the same way.

The sulphate of copper is applied, at intervals of two, three, or four days, and with the same precautions as in the pencilling with the lunar caustic solutions just referred to. The crayon of "blue-stone" must be smooth on its face, clear and clean, rubbed or filed into a small wedge "of the size and shape of the spade of cards," and fixed in a quill or other convenient holder. It is to be drawn over the parts very lightly, with a single sweep in most instances; although in some indolent cases it may be rubbed on two or three times at one application, with manifest advantage as well as impunity. Sulphate of copper is probably best adapted to the pale form of granulation, in which the reaction, and generally the congestion, are comparatively slight—the subacute or the chronic form; and the mode of using it must depend upon the various and successive grades of irritability, which a cautious and intelligent employment of it may reveal in each case.

The acute and active, or the congestive, forms of granular conjunctivitis are more likely to be abated by the different strengths of the lunar caustic solution, and by the subacetate of lead. There are, however, so many varieties and shades of irritability, inflammation and granulation between the two extremes of the disease, that the same general rule may serve to regulate the management of all the different remedies; except that of the two last-mentioned, the former is contra-indicated by the presence of ulceration or any breach of continuity in the parts exposed to its action, and the latter, if too long continued, will produce a permanent olive-colored stain. We have, at different times, seen the application of each different agent, in very similar conditions, followed by equally gratifying results, although we are inclined to prefer the lead as a pioneer remedy, in the more acute or inflammatory cases. It is often well to substitute one agent for another; and much good is frequently done by alternating them in the course of the same

week: employing, for example, the nitrate of silver, or the blue-stone at discretion, one day, and the subacetate of lead the next, or the second or third day after. When this plan is not adopted, some one of the adjuvants, such as the borax, alum or rock-salt crayon in substance, or solutions of either of these, or the iodide of zinc or the sulphate of zinc and salt solution, or that of tannic acid, or the vinum opii, the diluted citrine ointment or red precipitate ointment being applied to the margins of the lids at night, should be daily employed in support of the strong applications and the general course of treatment. It is obviously impossible, in this volume, to dwell upon contingencies, and to lay down special rules of practice, in the management of this most troublesome and variable affection. Its great prevalence in many parts of the United States, especially among the immigrant population, has induced us to add a few hints to the author's very brief notice. More can be learned from the study of individual cases than from any attempt at detailed directions. For the best American article on the subject, with clinical illustrations, we may refer to the last American edition of Lawrence on the Eye, p. 285, et. seq., by Dr. Hays.]

Vascular cornea and pannus.

Vascularity and more or less opacity and thickening of the conjunctival layer of the cornea is a not unfrequent appearance in chronic conjunctivitis. In a slight degree it is named *vascular cornea;* but when the vascularity and thickening of the conjunctiva corneæ are so great that the cornea wholly or in part appears as if covered with a bit of red cloth, the state is named *pannus.*

Vascular cornea or pannus is, as has been just stated (p. 183), often kept up and aggravated by granular conjunctiva. The continued irritation from inverted eyelashes is also a very common cause of this morbid condition of cornea.

Treatment.—The source of irritation being removed, the vascularity of the cornea sometimes subsides of itself, or with the assistance of local applications, such as the strong red precipitate ointment (p. 72), counter-irritation, and] tonics, or good diet and change of air. Often, however, it persists, in spite of treatment, or, having been removed, readily returns.

A peculiar plan of treating the pannus left by Egyptian ophthalmia, suggested about forty-three years ago by Dr. Henry Walker,[1] and which, in many cases, has succeeded in the hands of Professor Jaeger of Vienna, Dr. Piringer of Gratz, and others, is to excite in the eye a new attack of the ophthalmia by means of inoculation (p. 124, *note*), and then to endeavor, by carefully conducted treatment, to bring the inflammation to a favorable termination.

[1] Edin. Med. and Surg. Journal, 1811.

This would seem a hit-or-miss proceeding, even if we could always calculate on the cornea becoming clear in the cases in which we might succeed in saving the eye from total destruction. Dr. Piringer, however, asserts that a second attack of purulent ophthalmia runs a less violent course than a first attack, and confidently declares that the results of his experience of the practice prove inoculation with blennorrhœal matter for the cure of pannus to be no doubtful remedy. But is the granular condition of the eyelids cured?

The matter (that from the eyes of the infant laboring under ophthalmia neonatorum will do, and is the most generally attainable for the purpose) is to be taken up with a camel's hair pencil and freely applied to the conjunctiva of the eye affected with pannus; whereupon, the desired inflammation supervenes in the course of from six to ninety hours.

Cuticular conjunctiva.[1]

In this disease, the conjunctiva is so changed in structure as to present more of the characters of skin than mucous membrane; its epithelium, the epithelium of the cornea included, being thickened, dry, and semi-opaque, like epidermis. Its surface is no longer duly lubricated with its natural mucous secretion, and in one case, that of a chimney-sweeper, I found it refuse being moistened with the tears, as if it had been greasy. Along with this change in structure, there is general contraction of the whole conjunctiva, even to obliteration of the palpebral sinuses.

Subjective symptoms.—The vision is impaired in proportion to the dimness of the epithelium of the cornea, the eye feels dry, the surface of the conjunctiva is but little sensible, and the movements of the eyeball and eyelids are restricted.

Causes.—Cuticular conjunctiva is commonly the result of some external ophthalmia, such as catarrhal, scrofulous, scrofulo-catarrhal, or the like, which by neglect or mistreatment has been allowed to fall into a chronic state, and which chronic state has been long kept up by exposure to dust and acrid vapors, by the inappropriate use of irritating applications, such as the nitrate of silver drops, or by the irritation of inverted eyelashes. The disease may also arise in consequence of the chronic conjunctivitis kept up by the exposure of the conjunctiva in ectropium.

The dryness of the eye in this disease, and even the disease itself, have been supposed to be immediately owing to obliteration of the lacrymal ducts; but though there may sometimes be suspension of the lacrymal discharge, this is not always so, for in some cases the

[1] Conjunctival xeroma or xerophthalmia.

patients have been found to shed tears. In the case above referred to, for example, the tears flowed copiously on some inverted eyelashes being plucked out. It is not, however, the tears which constitute the ordinary means of moistening the eye, but the conjunctival secretion. The suppression of this, therefore, is the cause of the dryness, and the cause of the suppression is the alteration in structure of the conjunctiva, above described. See *Lacrymal Xeroma*, under the head of Diseases of the Lacrymal Organs.

Prognosis and treatment.—Cuticular conjunctiva having been found incapable of radical cure, the treatment can only be palliative; and this must consist in occasionally bathing the eye with tepid water. When the surface of the conjunctiva repels the moisture, as if greasy, aqua potassa may be added to the water in the proportion of three or four drops to two ounces.

Onyx and abscess of the cornea.

The nature of onyx and abscess of the cornea has been above described (p. 94, et seq.), and their occurrence in various ophthalmiæ referred to when considering the latter. All that requires to be said here on the subject is, that in the treatment no direct interference with the onyx or abscess is in general admissible. The only indication is to subdue the inflammation which has given rise to it as quickly as possible, and then nature will do what can be done for its removal.

Ulcers of the cornea.

Ulceration of the cornea has been above described (p. 96, et seq.), and its occurrence and characters in the various ophthalmiæ considered. It may be here farther remarked that destructive ulceration of the cornea, without much or any appearance of inflammation of the eye, is sometimes observed in cases of great exhaustion of the system from whatever cause (as after typhus), and also in cases of disease of the fifth pair.

The *Treatment* of ulcers of the cornea comes under the head of that of the ophthalmia which has given rise to them; but such details as the following may be mentioned here:—1. As chronic superficial spreading ulceration of the cornea is frequently accompanied by a granulated state of the palpebral conjunctiva, this source of irritation requires to be particularly looked to. 2. When a deep ulcer is threatening to penetrate the cornea, evacuation of the aqueous humor often proves of great service by taking off the strain from the ulcerated part; and the inflammatory action usually receiving thereby a check, the conditions are rendered favorable for the operation of remedies and the establishment of granulation.

3. When an ulcer of the cornea near the centre threatens to penetrate, it is advisable to keep the pupil under the influence of belladonna, in order that, should perforation and consequent escape of the aqueous humor take place, prolapse of the iris may not follow.

Sometimes the whole surface of an ulcer of the cornea is found covered with a matter resembling (to use the comparison of Mr. Wardrop) wet chalk. This appearance is attributed by Dr. Jacob to a precipitate from the acetate of lead solution so frequently employed as an eye-water. Beer had frequently remarked that the use of lead lotions rendered the cornea opaque. Any part of the conjunctiva, whether abraded or not,[1] may be the seat of the deposit, but attention is most usually drawn to it when on the cornea. The white deposit is apt to become fixed in the cicatrice, which is then dense and indelible. Dr. Jacob[2] says that the opacity appears to be produced at once by a single application. He has seen it the day after a drop of solution of acetate of lead had been put into the eye by mistake. A white deposit does not take place in all cases in which the acetate is used; but Dr. Jacob says that he does not think he can state positively the precise condition of the ulcer which causes it.

Dr. Mackenzie recommends a cautious attempt to be made to remove, with a small silver spatula, the white deposit from the surface of the ulcer; and he tells us that in one case he succeeded in separating a scale of lead which had been deposited on the cornea.[3] In general, however, it is safer not to interfere in this manner. I have seen the scale become detached spontaneously, as the ulcer healed.

Suffusion, opacities, and specks of the cornea.

Suffusion of the cornea from distension.—A certain degree of tension is a necessary condition for the transparency and brilliancy of the cornea, as may be inferred from the dull appearance which the eye presents when the tone of the whole body is reduced by debilitating disease. Increased tension within certain limits adds to the brilliancy of the eye, as is seen in states of mental excitement, but beyond these limits of tension, the cornea becomes suffused. This takes place more or less in all inflammations of the eye, in consequence either of increased distension from within, or pressure from without.

That dimness or brilliancy of the cornea, in the degree referred

[1] This is well seen when the powdered acetate of lead has been applied in granular conjunctiva, see p. 74.

[2] Dublin Hospital Reports, vol. v. p. 370.

[3] Mr. Tyrrell describes a particular disease of the cornea under the name of "Inflammation of the Cornea with deposition of earthy matter," and this he thinks is the same as the alleged accidental deposition on ulcers of the cornea, from lead lotions, above described. Without denying that an insoluble precipitate may adhere to an ulcerated surface, Mr. Tyrrell considers that in all the cases which have come under his notice, the deposition had not this origin.

to, is dependent on its state of tension, is well illustrated by what may be demonstrated in the eye of an animal recently slaughtered. Thus, if a sheep's eye be removed from the orbit, and slightly compressed by grasping it in the hand, the cornea, which was before relaxed and dull, becomes distended and clear; but if the eye be more tightly grasped, the cornea is rendered more tense, but at the same time is suffused with a milky opacity. This however disappears on relaxing this pressure.

Opacity of the cornea is a frequent consequence of inflammation, and is owing either to interstitial deposition, or to the cicatrization of an ulcer. The opacity occurs in various degrees of density, extent, and permanency, from a mere speck, which tends ultimately to disappear, to a dense and indelible opacity, involving, perhaps, the whole centre of the cornea, and concealing the pupil.

Opacity from interstitial deposition—Nebula—Albugo.—The speck called *nebula*, is semi-transparent, and so shaded off at its circumference, that it presents no precise limits. An *albugo* is also shaded off at its circumference, but its centre is densely opaque, and slightly elevated; both of which characters are owing to the larger quantity of exuded lymph than in the simple nebula. A nebula is usually the result of diffused, but slight exudation; albugo, again is the result of circumscribed, but more copious exudation, which has not been matured into a phlyctenula or pustule.

Sometimes one or more vessels are seen running into an albugo, and very generally there may be observed, both in cases of albugo and of opaque cicatrice, nebulous streaks extending towards them from the circumference of the cornea, indicating where vessels had run.

Treatment of opacity from interstitial deposition.—In proportion as the inflammation subsides, the opacity diminishes; therefore no special remedy is required for the opacity in the first place, and in the second, it is proper to wait and see what the natural absorbent powers of the part can effect, which, especially in young persons, is often a great deal. If the opacity continues, and if it is so situated as to disturb vision, then we may try what local applications, counter-irritation, and especially tonics and change of air will do. The local applications which have been found most useful, are the drops of the bichloride of mercury with vinum opii (p. 71), and the red precipitate salve (p. 72).

Opacity from a cicatrice—Leucoma.—According as the ulcer of the cornea has involved merely the conjunctival layer, or both this and the proper substance, so is the cicatrice semi-transparent or perfectly white. The circumference of an opacity from a cicatrice, is usually more defined than that of opacity from simple deposition.

Though after the healing of some ulcers of the cornea, no opacity takes place, still, when the cicatrice of an ulcer is opaque, it is indelibly so, unless the ulcer has been a mere abrasion of the conjunctiva corneæ.

When an indelible opacity lies over the pupil, dilatation of this, kept up by the habitual use of a solution of extract of belladonna or of the sulphate of atropia (p. 71) dropped into the eye, is a very valuable resource. Figures 10 and 11.

Fig. 10.

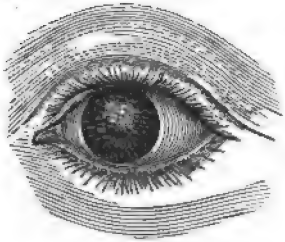

Central opacity of the cornea concealing the pupil.

Fig. 11.

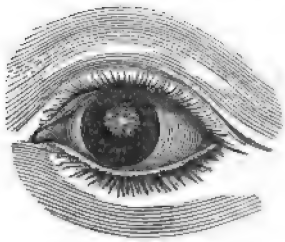

The same eye with the pupil dilated by belladonna.

In cases in which the opacity occupies too much of the centre of the cornea for the dilatation of the pupil to be of any use, recourse must be had to the operation of cutting out a piece of the iris opposite the clear part of the cornea (*artificial pupil by excision*); —that is, supposing the opposite eye affected in a similar manner, or the sight of it otherwise lost.

Dimness of the inner surface of the cornea.—The membrane of Descemet, when inflamed, is the seat of more or less milky suffusion, interspersed with numerous small opaque dots of an altogether peculiar appearance. When the membrane of Descemet, Dr. Jacob informs us, has been touched by the point of the needle in breaking up a cataract, an opacity is produced, closely resembling capsular cataract. I once observed a uniform but very slight suffusion of the membrane of Descemet produced in a woman, from whose eye I extracted a lenticular cataract, in consequence of her having, after the upper section of the cornea, suddenly turned up the eye, in which movement the flap, being caught by the upper eyelid, was folded down, and the membrane of Descemet consequently grazed by the edge of the lid. Notwithstanding this, recovery without any other untoward circumstance than the slight dimness above mentioned, rapidly took place. [We have often seen the inner surface of the cornea pricked by the needle or iris-knife without any opacity resulting from the accident.]

Hernia of the cornea (keratocele).

For the description of hernia of the cornea, see pp. 96, 97.

Prolapsus iridis.

This has been above described, under the head of "Effects of Penetration of the Cornea" (p. 98).

The treatment of prolapsus iridis from penetrating wound of the cornea is considered under the head of *Wounds of the Cornea.* When prolapsus iridis occurs in consequence of the cornea being penetrated by ulceration, there is much less likelihood of restoring the iris to its place than when it occurs in consequence of a penetrating wound of the cornea. Much may, however, be done to prevent prolapse of the iris, by keeping the pupil under the influence of belladonna, when an ulcer near the centre of the cornea is threatening to penetrate.

When, in consequence of penetrating ulcer of the cornea, prolapse of the iris has taken place, there should in general be no direct interference with the prolapsed iris. The attention ought rather to be continued to the removal of the inflammation, of which the prolapse of the iris is the remote consequence, in order to promote the result above described (p. 99). If the prolapsus iridis be of a size, however, likely to lead to partial staphyloma, a snip may be made in it with a pair of fine scissors, in order to allow the aqueous humor to drain away, and thus keep it collapsed while the cicatrice is being formed over it.

Staphyloma of the cornea and iris.

An unnatural prominence with opacity of a part or of the whole of the cornea, of a grayish-white or mother of pearl color:—Such is the definition which a first view would suggest of *partial* or *total spherical staphyloma* of the cornea and iris; that it is not quite accurate, however, will be shown when the nature of the morbid change comes under consideration.

Partial staphyloma.

Fig. 12.

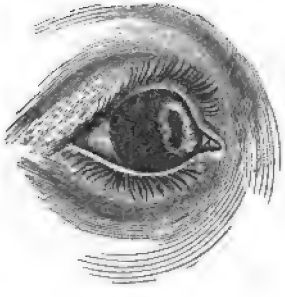

Objective characters. — Partial staphyloma most usually involves the lower or lateral part of the cornea, and may vary in extent from a quarter to a full half of the area of that membrane. On close examination, the iris is seen drawn towards and joined to the inner surface of the opaque projection. The anterior chamber is in consequence much contracted. According to the situation and extent of the staphyloma, so is the integrity of the pupil more or less interfered with; and that either by

direct incorporation of the pupillary margin of the iris, or by opacity extending to the part of the cornea over the pupil.

Subjective symptoms.—Vision is impaired in proportion to the degree in which the pupil is involved in the manner just stated. Besides this the prominence being on the one hand exposed to the desiccant and irritating action of the air, &c., and on the other, acting as a foreign body, frequent nictitation is excited, which frets both the staphyloma and eyelids;—whence the weak state of the eye and frequent attacks of inflammation.

Total spherical staphyloma.

Objective characters.—In this case, the opaque structure, which represents the cornea, forms a prominence so large as to stretch and press out the eyelids, or even to project considerably from between them.

Fig. 13.

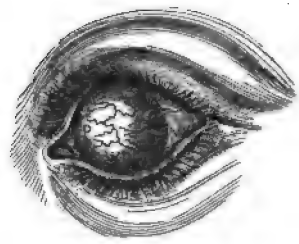

Subjective symptoms.—Vision is wholly lost; but a perception of light and shade, &c., remains.

Course.—The staphyloma may remain stationary, but sometimes it goes on increasing in size till it bursts. This is attended with very severe symptoms, such as distension in the eye, and circumorbital pain, preventing sleep, and exhausting the patient. On the bursting of the eye, these symptoms immediately subside, and if, together with aqueous humor, the lens and part of the vitreous humor have escaped, the eye does not again become distended, but contracts into a stump, marked with depressions at the places corresponding to the insertion of the straight muscles. If all the vitreous humor has escaped, the membranes shrink back in the orbit, and form a small shapeless mass at its bottom. If the aqueous humor only escapes, the staphyloma sinks for a day or two, but soon returns to its former state, when by the closure of the laceration, the aqueous humor is allowed to reaccumulate.

Pathology.—In consequence of inflammation, the structure of the cornea is changed, the iris adheres to it, surface to surface, and the two together are distended into an opaque prominence of more or less considerable size. Such, in a few words, was the commonly received opinion regarding the formation of staphyloma of the cornea and iris up to 1838, when I enunciated a different view of the matter.[1]

[1] Medical Gazette, February, 1838.

If in scrofulous, catarrhal, or catarrho-rheumatic ophthalmia, there be a penetrating ulcer of the cornea, the aqueous humor, as has been already mentioned, escapes, the iris falls forward into contact with the cornea, and a small part of it is perhaps prolapsed through the ulcerated opening. The progress of the ulceration being stopped by the yielding of the inflammation, the prolapsed portion of the iris and the ulcerated part of the cornea are involved in one cicatrice. The opening in the cornea being thus closed, the aqueous humor again collects, and the interior chamber is restored; though somewhat diminished, in consequence of the partial adhesion between the iris and cornea (*synechia anterior*). There is no prominent distension on the front of the eye in this case, because, as the inflammation subsides, the small protruded portion of iris shrinks and flattens; but if the destruction of the cornea has gone on farther, either by extension of ulceration from a continuance of the inflammation, or by the giving way of an abscess of the cornea, and considerably more of the iris has protruded, the prolapsed portion of the iris does not shrink when the inflammation begins to abate, as in the former case, but remains, and forms a projection at the part of the cornea implicated, which is generally the lower or lateral. This projection is at first merely a bag of the iris distended by the aqueous humor, and is called *staphyloma iridis;* but, by-and-by, its exposed surface becomes covered by an opaque firm tissue, of the nature of the *tissue of cicatrice,* and this tissue is incorporated at the base of the tumor with the sound cornea. The projection, the mode of origin of which I have just described, is a *partial staphyloma;* it is not a distension of the cornea itself, but a protruded portion of the iris covered by a *new tissue,* intended to supply the loss of substance which the cornea has sustained. The mode of origin of a *total staphyloma* is essentially the same, but differs only in degree. The whole or greater part of the cornea being destroyed, as occurs in gonorrhœal, purulent, and very often in variolous ophthalmia, as also in that of new-born infants, the iris falls forward, and its exposed surface gradually gets covered with an opaque cicatrice-like tissue or *pseudo-cornea,* of greater or less thickness; whilst a layer of lymph, as I have found, may be deposited on its posterior surface. The pupil becoming closed in the course of this process, the aqueous humor is allowed to reaccumulate in the posterior chamber, and by its pressure, the iris, with its pseudo-corneal-investment, is distended in the form of a tumor on the front of the eye, and a total staphyloma is the result. Sometimes the central part only of the cornea is destroyed, a ring of the circumference still remaining; the staphylomatous projection has then the form of a small globe stuck on the front of a larger; or if the cornea

at its junction with the pseudo-cornea has yielded to the pressure of the aqueous humor, and especially if disease has extended to the ciliary body, the whole front of the eye is prominent like a blunt cone—(*Conical staphyloma*).

Sometimes when the destruction of the cornea is of small extent, the cicatrice which is developed over the prolapsed iris may, though at first prominent, subsequently become flattened from contraction. By-and-by, however, in consequence of a new attack of inflammation, perhaps, aqueous humor is poured out in increased quantity into the posterior chamber (now cut off from all communication with the collapsed anterior chamber in consequence of the closure of the pupil), the cicatrice, unable to withstand the pressure from behind, is protruded into a staphylomatous projection.

The pseudo-cornea, both in partial and in spherical staphyloma, is more or less pervaded by dark-colored varicose vessels.

A circumstance in the pathological anatomy of staphyloma worthy of being noticed is, that when the tumor attains a large size, the iris, unable to expand to the same degree as the pseudo-cornea, and its texture much more frail, separates from the choroid and becomes torn into shreds; so that when we examine the internal surface of such a staphyloma, after death, or after it has been removed by operation, we find the iris, which adheres to the pseudo-cornea, broken and reticulated: whereas the internal surface of a staphyloma, which has not reached a great size, exhibits the iris still entire.[1]

That the cornea and iris do not unite, surface to surface, to form a staphyloma, may be inferred from what has been said above; but the following considerations, above merely glanced at (pp 100, 107), show that such a union is not prone to take place under any circumstances:

1. On examining a staphyloma, along with which the circumferential part of the true cornea, which still existed, had been removed by operation, I found the corresponding part of the iris, though in close contact with the latter, not at all adherent to its inner surface, on which the membrane of Descemet still existed.

2. In penetrating ulcer of the cornea, and prolapsus iridis, of course the prolapsed part of the iris adheres to the cornea at the one point. But though the two membranes have come into contact in the whole extent of their surfaces, in consequence of the escape of the aqueous humor through the opening in the cornea, made by the penetrating ulcer; and though, in consequence of the attending inflammation, the circumstances favorable for adhesion exist, still the iris does not adhere to the cornea, surface to surface, as the pleura pulmonalis does to the pleura costalis. On the contrary,

[1] Beer's Ansicht der staphylomatösen Metamorphosen des Auges. Wien, 1805. Mackenzie's Practical Treatise, Hewson's Am. edition, pp. 640, 1.

as soon as the ulcerated opening in the cornea closes, so that the aqueous humor is allowed to accumulate, the iris recedes from the cornea, and the anterior chamber is re-established. The only adhesion between the iris and cornea is at the one point where the prolapsus iridis took place.

3. Again, cases of penetrating ulcer of the cornea occur, in which the aqueous humor having escaped, and the iris come into contact with the cornea, but no prolapse of the former having taken place, no adhesion at all between the two ensues, but the iris recedes from the cornea as soon as the opening in the latter from the ulcer closes, and prevents the farther escape of aqueous humor.

4. One would suppose that if adhesion between the anterior surface of the iris and inner surface of the cornea were a thing prone to take place, that it would have been observed in those cases of inflammation of the membrane of the aqueous humor in which the operation for evacuating the latter has been performed; but I apprehend no one ever saw such a result. In the operation for the extraction of the lens in cataract, the aqueous humor having escaped, the iris comes into contact with the cornea, and continues so for a considerable period; but if there be no prolapsus iridis, adhesion never takes place. If the iris does not adhere to the cornea when these two parts come into contact, from the escape of the aqueous humor, and while in a state of inflammation, much less do they adhere, independently of the removal of that fluid.

But it may be said, it is not in consequence of such inflammations of the eye that staphyloma occurs, but that purulent, gonorrhœal, and variolous ophthalmia are the most frequent causes of staphyloma. True; but under what conditions does staphyloma occur in those diseases? Not by adhesion of the iris to the cornea, surface to surface, but only when the cornea has been more or less extensively destroyed. Now purulent, gonorrhœal, and variolous ophthalmiæ are the very diseases in which, as is well known, this takes place.

This view of the pathology of staphyloma, which I first published about sixteen years ago, and which has been, on insufficient grounds, objected to by some, and appropriated, without acknowledgment, by others, has been ably illustrated by Professor Roser, of Marburg, in an elaborate monograph.[1]

Diagnosis of partial staphyloma.—Conical cornea can scarcely be confounded with partial staphyloma, but a form of hernia corneæ resembles it in being prominent, though differing from it in not being so opaque, and in not having the iris adherent to it (p. 99). An albugo is opaque, but not so prominent as a partial staphyloma, and, as in the preceding instance, free of any adhesion with the iris.

[1] Die Lehre vom Hornhaut-Staphylom. Nach dem gegenwärtigen Standpunct der Wissenschaft zusammen gefast.

A leucoma is opaque, and may be combined with synechia anterior, but the adhesion of the iris is comparatively of small extent, and the prominence of staphyloma is wanting.

Prognosis and treatment.—If the staphyloma be small and do not implicate the pupil much, the less that is done, by way of treatment the better, but irritation is to be guarded against, and any tendency to inflammation kept down by occasionally dropping in a solution of nitrate of silver or diluted vinum opii. In a case in which the opposite eye is injured and vision lost, if the staphyloma implicate the pupil, it will be proper to attempt to diminish its projection in order to pave the way for making an artificial pupil.

The *treatment* which has been adopted with this view, consists in repeatedly touching the staphyloma with some caustic, such as chloride of antimony, nitrate of silver, or caustic potash, in order, by a slow inflammatory process, to produce condensation and contraction of it. The eschar of one cauterization should be allowed to fall off, and the other effects to subside before a repetition of the caustic. The best plan is to commence touching the base of the staphyloma at points all round, and then gradually proceeding towards the apex. The above-described treatment is assisted in effecting the consolidation and flattening of the pseudo-cornea by frequently evacuating the aqueous humor.

Mr. Tyrrell says he has succeeded in several instances, in effecting a reduction of partial staphyloma, by the careful application of nitrate of silver, or hydrate of potash, in substance. He applies the escharotic first at the base of the projection, taking care not to injure the remaining sound cornea: the effect has been the separation of a small slough; but previous to such separation, a deposit of lymph has taken place beneath, by which the deeper part has become more solid and strengthened. After the part has recovered from one application, he makes a second close to, but not upon, the same spot, and nearer to the summit of the projection. Again and again he repeats this operation, acting upon the more prominent part, until a considerable or perfect reduction of the staphyloma has been accomplished; and this has enabled him, in a few cases, to form an artificial pupil, of much more utility to the patient. He prefers the hydrate of potash, unless the projection be very small; for its use is followed by a much larger deposit of lymph than results from the nitrate of silver.[1]

Prognosis and treatment of total staphyloma.—When an inflammation of the eye has run so disastrous a course that the conditions for the formation of a total staphyloma are laid, any treatment which may be adopted can have for its object, not to save the eye as an organ of vision, but to prevent it from degene-

[1] A Practical Work on the Diseases of the Eye, &c., vol. i. p. 273. London. 1840.

rating into a tumor, which not only causes great deformity, but is a source of considerable irritation, even to the opposite eye, so much so that the patient seeks for its removal by operation, sooner or later.

Prophylactic treatment.—According to the account of the mode of formation of total staphyloma above given, it appears that the accumulation of aqueous humor in the still-existing posterior chamber, is what causes the distension of the iris, together with the pseudo-cornea developed on its surface. If this be the case, the destruction of the source of the aqueous humor, by breaking in upon the integrity of the posterior chamber, is a means which offers itself to prevent the development of the staphylomatous projection. The simplest plan of effecting this appearing to me to be the extraction of the lens, I put the operation in practice in the following case:

A man, about twenty-two years old, came to me, laboring under the effects of severe purulent ophthalmia of both eyes. In the right eye, the cornea being destroyed and the pupil closed, the iris protruded and was distended with aqueous humor. The left eye had also suffered very much; there was penetrating ulcer, prolapsus iridis, and consquently considerable distortion and contraction of the pupil. Both eyes were still affected with the inflammation, and it was very doubtful whether the left eye could be prevented from getting worse, especially as it was evidently kept in a state of additional irritation from the presence of the staphyloma in the right. By an incision with a Beer's cataract-knife through the protruding and distended iris, the lens was extracted. Severe reaction followed; less perhaps in consequence of the operation, than from the patient not being in a situation to take proper care of himself. The iris did not again become distended; on the contrary the eye shrank, and irritation being thus removed, the left eye progressively recovered, as far as the organic changes it had already undergone allowed, and further than there had been reason to hope for, as sufficient vision was preserved to enable the patient to resume his employment as a porter.

In those cases in which the eye is destroyed, whether in adults or new-born infants, by purulent ophthalmia, variolous ophthalmia, &c., and in which staphyloma does not result, but the pseudo-cornea which forms remains flat and the eyeball becomes atrophic, I suspect the lens has escaped on the giving way of the cornea. In a case of traumatic hypopyon, Professor Roser relates, that after the destruction of the cornea, he found the crystalline body exposed, and that on the bursting of the capsule two days after, the lens escaped. No staphyloma formed, but healing took place with a flat cicatrice.

A fully formed total spherical staphyloma is a source of great deformity; its removal therefore is often sought for in order that an artificial eye may be worn. But what principally demands its removal, sooner or later, is the irritation which it keeps up, and which is apt to be communicated to the opposite eye.

Operation for the removal of fully formed total spherical staphyloma.—Compression, ligature, seton, caustics, incision, variously modified or combined, have been recommended as a means of repressing staphyloma; but it is now agreed that the only proceeding to be depended on for its removal is abscission.

Fig. 14.

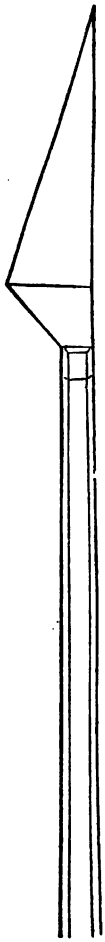

In determining the size of the piece to be cut away, we should take into consideration the circumstance, whether the patient intends to wear an artificial eye or not. In the one case, a larger piece should be cut away in order to reduce the eyeball to a proper sized stump for the support of an artificial eye (p. 207); in the other case, a smaller piece, and none of the circumferential part of the real cornea which may still exist, in order to preserve the size and natural appearance of the eyeball as far as possible.

The patient may lie on a table or be seated on a chair, with the side not to be operated on, next the window. When the patient is seated on a chair, he leans his head on the breast of an assistant who stands behind, and who also supports the chin with the palm of one hand, whilst with the fingers of the other he raises the upper eyelid. The surgeon himself, then depressing the lower eyelid with one hand, proceeds in the following manner:

With the staphyloma-knife, Fig. 14, its edge directed upwards, he transfixes the tumor from the temporal to the nasal side, and somewhat below its transverse diameter. Pushing the knife on, it cuts itself out, and a flap is formed, as in the operation for extracting the cataract. The flap thus made is seized with a hooked forceps, and the abscission completed with a pair of curved scissors. If the lens still exists, it is to be extracted, if it does not escape spontaneously.

After the operation, the eyelids of both eyes are to be kept closed by strips of court-plaster [or gauze and collodion], and covered with a light compress and roller.

There is usually little hemorrhage at the time; but it occasionally happens, especially in cases complicated

with sclerotic staphyloma, that, some hours after, the eyeball becomes distended with blood, and the clots, or infiltrated vitreous body, protrude from the wound. The bloody, dark-colored mass is to be cut away with scissors, and the eye covered with a compress soaked in cold water.

Under ordinary circumstances, the healing process proceeds favorably. The wound becomes covered with granulations. These are condensed into a semi-transparent membrane, which, by-and-by, becomes dense and opaque, forming a flat cicatrice, marked with bluish or brownish streaks. Sometimes a fungus grows from the wound, which, however, readily subsides after being occasionally touched with lunar caustic.

If severe reaction follows the operation, antiphlogistics, anodynes, and warm fomentations, &c., will be required.

Hypopyon.[1]

This name has been given to a collection of pus or puriform matter occupying the bottom of the anterior chamber. In a small hypopyon, the collection of matter necessarily takes a shape somewhat resembling that of *onyx* (p. 95), but the two kinds of cases are distinguishable from each other by the circumstances: that on turning the patient's head to one or other side, the matter of onyx does not change its place, whereas, that of hypopyon does, unless, as is sometimes the case, it is thick and glutinous; and that on looking at the cornea in profile, the deposition in onyx appears nearer the surface than that in hypopyon. Both onyx and hypopyon may exist at the same time.

Source of the matter in hypopyon.—This is different in different cases. The matter may, as would appear from all the circumstances of the case, be poured out from the unbroken surfaces of the walls of the aqueous chambers in the same way that matter is poured out by inflamed mucous and serous membranes; or, it may result from the bursting inwards of an abscess of the cornea (p. 98). An hypopyon formed in either of the last two ways has been named false (*hypopyon spurium*), in contradistinction to hypopyon formed in the first way, and which is named true (*hypopyon verum*).

Seeing thus that the source of accumulated matter in the anterior chamber may be different, it will be at once perceived that hypopyon may be the consequence of various forms of ophthalmic inflammation, external and internal.

Treatment.—As the inflammation in which hypopyon has originated is still going on, the first indication is to subdue it as quickly as possible, and then the accumulated matter will in general soon disappear.

[1] Oculus purulentus.

Prominent cornea and dropsy of the aqueous chambers.[1]

It has been already explained (pp. 144, 145), how an increase in the prominence and diameter of the cornea may take place in corneitis, in consequence of the softening of the texture of the cornea, on the one hand, and distension, by increased accumulation of aqueous humor, on the other. This constitutes one form of dropsy of the aqueous chambers—the form which belongs to this section.[2]

Diagnosis.—The prominent cornea in dropsy of the aqueous chambers is distinguished from conical cornea by its spheroidal curve.[3] See *Conical Cornea.*

Fig. 15.

Prognosis and treatment.—In consequence of the diminished elasticity and resistance of the cornea, it cannot regain its normal degree of prominence, and thus limit the increased exudation of aqueous humor. All that can be done, therefore, in the way of treatment, is to endeavor to subdue what inflammation may still exist, by the remedies adapted to the particular case, and to improve the general health by change of air, tonics, &c. Concave glasses help the sight.

Synechia.

Synechia is a morbid adhesion of the iris—generally its pupillary margin—to the cornea or to the anterior wall of the capsule of the lens. In the former case it is named *synechia anterior*—in the latter, *synechia posterior;* and according as it is a part or the whole of the pupillary margin of the iris which is involved in the adhesion, the synechia is named *partial* or *total.* The principal points regarding the nature of synechia have been above explained (pp. 56, 57, 99, 107).

Treatment.—*Synechia anterior* may be so partial, and the transparency of the cornea so unimpaired, except at the point of

[1] Hydrophthalmia anterior.

[2] Dropsy of the eye, independent of inflammation, or at least independent of evident inflammation, is treated of in the next chapter.

[3] In a case, however, related in the last edition of this work, under the name of *conical staphylomæ cornea,* but which would perhaps be more correctly designated *conical hydrophthalmia,* the prominent cornea was conical. The patient was the same scrofulous girl, whose right eye was the seat of the very large partial staphyloma, delineated in Figure 12.

In the left eye vision was quite gone. The cornea was enlarged at its circumference, and projected in the form of a pretty regular cone. The sclerotica was distended at its junction with the cornea, and partook of the conical transformation, so that the posterior half of the eyeball formed the base of the cone of which the apex occupied the middle of the cornea. The eyeball was hard to the touch. At their junction, the sclerotica and cornea were of a dark bluish color. At the apex of the cone the cornea was grayish-white, and in the intermediate part it was brownish-red, but still retaining some traces of its former transparency, though not sufficient to allow of the state of the interior of the eyeball being ascertained. The eye had a dirty appearance, and its front was pervaded by varicose vessels.

adhesion, that vision is not disturbed; nothing, therefore, is required to be done. If the cornea be opaque to some extent opposite the somewhat contracted and distorted pupil, dilatation of the latter by means of the habitual use of belladonna or atropia, will in many cases, be found of the same service as in simple central opacity of the cornea, as above mentioned (p. 191). When, from the smallness of the pupil, and extent of the opacity of the cornea, belladonna does not yield this service, or when the synechia is total, the only prospect of restoring vision is by an operation for artificial pupil. See *Artificial pupil.*

As the iritis in which *synechia posterior* has had its origin subsides, we see, under the use of belladonna, one band of adhesion after another give way, and the pupil become free, but very often, on close examination, small grayish or brownish specks are seen on the capsule of the lens, indicating the points where the adhesion of the iris to it had been. Vision, however, may not be much disturbed by these specks, even when some of the adhesions remain. But when the adhesion of the pupillary margin is extensive, there is also more or less contraction of the pupil, and extensive deposition of lymph on the capsule of the lens, the consequence of which is, that vision is impaired to a greater or less degree, even if the same inflammation which has given rise to the synechia has not also involved and injured the retina. This state of matters may be sometimes palliated by the habitual use of belladonna. And in course of time it may happen that detachment of some portion of the adhesion takes place, and greater dilatation of the pupil allowed, with corresponding improvement in vision.

Closure of the pupil.[1]

Closure of the pupil is generally the consequence of iritis (p. 99), but it may also result from prolapse of the iris, in consequence, for example, of central penetrating ulcer of the cornea. In the former case, closure of the pupil is complicated with total synechia posterior; in the latter, with total synechia anterior.

Treatment.—See *Artificial Pupil.*

Iridauxesis, or hypertrophy of the iris.[2]

This morbid state, is a consequence of chronic, neglected, or ill-treated parenchymatous inflammation of the iris; but in addition to the iritis there has usually been inflammation of the posterior tunics, as manifested by attenuation of the sclerotica, varicosity of the vessels of the white of the eye, and hardness of the eyeball. Hence vision

[1] Atresia iridis—Synizesis.

[2] Staphyloma iridis—Staphyloma uveæ—Iridoncosis—Lymphoncus iridis—Exudation of lymph into the tissue of the iris.

is very greatly impaired, if not wholly extinguished, even although the pupil may not be much obstructed.

The pupillary margin of the iris is generally retracted and adherent to the capsule of the lens all round (*total synechia posterior*), the body of the iris, which is bolstered forwards, presents black elevated spots on its surface, looking as if it were perforated here and there, or as if its proper substance were gone, and the uvea, appeared or even protruded through. The proper substance of the iris which remains evident is changed in color, and has a remarkable fibrous appearance. Fig. 16.

Fig. 16.

From Klemmer.

From the observations of Klemmer and others this change would appear to consist in a thickening of the iris from exudation of lymph into its substance. In this lymph new vessels are developed, and deposition of pigment subsequently takes place, producing the dark spots.

Sclerotic staphyloma.[1]

Sclerotic staphyloma consists, as above stated (pp. 94, 169), in a softening, attenuation, and bulging out of some part of the sclerotica, which is at the same time of a bluish-black tint.

The bulging out of the softened and attenuated sclerotica, is owing to a collection of fluid, either between the sclerotica and choroid (*subsclerotic dropsy*), or, the sclerotica and choroid being adherent, between them on the one hand, and the retina on the other (*subchoroid dropsy*), or within the retina in the seat of the vitreous humor (*dropsy of the vitreous humor*); whilst the bluish-black tint is owing partly to the deposition of pigment in the substance of the bulging sclerotica, and partly to the dark interior of the eye shining through.

Staphyloma of this sort may involve any part of the sclerotica, the posterior or lateral as well as the anterior; but it is of course only when the anterior part is affected that the disease is recognizable during life.

When sclerotic staphyloma affects the anterior part of the eye, the bluish-black prominence or prominences, of a greater or less size, are generally adjacent to one or other side of the cornea, in the region of the ciliary body—more commonly the upper and temporal side—or even all round. The white of the eye is at the same time pervaded by varicose vessels.

The same inflammation (viz., posterior internal ophthalmia, in

[1] Cirsophthalmia—Varicositas oculi.

which the choroid is especially affected), which has given origin to sclerotic staphyloma, has usually at the same time occasioned other morbid changes in the eye.

In sclerotic staphyloma, vision is generally nearly or altogether extinct.

By increasing accumulation of fluid, the staphylomatous projections may go on to increase in size so that the eyeball comes to protrude from between the eyelids, and there is at the same time great pain from distension. At last the eye may burst and evacuation of the fluid take place, in which case it may either remain shrunk, or the opening closing, it may become again distended.

Treatment.—The restoration of vision is out of the question. Treatment of the staphyloma, therefore, is only called for to relieve the pain arising from distension of the eyeball by the accumulation of fluid, and to reduce the size of the prominence if very great.

Evacuation of the fluid by puncture relieves the distension of the eyeball, and produces collapse of the staphylomatous projection for the time. The fluid, however, by-and-by, reaccumulates; but, by repeating the evacuation over and over again, reaccumulation may at last cease to take place, and the eyeball will shrink to a small size. An accident, apt to occur in this operation, is infiltration of the subconjunctival cellular tissue with the evacuated fluid, which causes great swelling and pain at the time. The fluid is, however, by-and-by, absorbed, and it would seem that its pressure on the empty eyeball may prevent reaccumulation.

In regard to evacuation of the fluid as a means of relieving the pain from distension, it is to be observed, that immediately on evacuation there may be great exacerbation of the pain, but this gradually subsides, and at last more or less perfect relief is obtained.

When the whole front of the eyeball is involved in the staphylomatous degeneration, and no progress in its diminution has been made by repeated puncture, excision of it, as in common staphyloma, may be had recourse to. After this, the eyeball shrinks to a stump, fit for supporting an artificial eye. In some cases, we may so place the operation as to succeed in preserving in some degree the natural form, size, and general appearance of the eyeball.

Synchysis.[1]

This name is given to a morbid state of the vitreous body, consisting in atrophy or solution of the hyaloid, in consequence of which the vitreous body is reduced from its natural gelatiniform to a diffluent state. This we are made acquainted with by dissection; but what are the symptoms of synchysis during life? As the quantity of vitreous fluid may be increased or diminished, there

[1] Dissolution of the vitreous body.

may be hardness or softness of the eyeball. Sometimes there is a tremulousness of the iris, sometimes none.

Synchysis, though often a consequence of internal inflammation, and an accompaniment of impaired sensibility of the retina, is a change to which, with the advance of life, the vitreous body appears to have a tendency, in the same manner that the lens has to opacity. The cataract of old people is indeed often combined with some degree of synchysis, and this is the cause of the principal danger attending the operation of extraction, viz., escape of the dissolved vitreous humor. See below.

The sparkling appearance produced by the presence of cholesterine crystals in the dissolved vitreous humor to which this name of *synchysis scintillans* has been given, is above noticed (p. 63).

Atrophy of the eyeball.[1]

Atrophy of the eyeball is the result of chronic inflammation, which has fixed itself primarily or secondarily in the internal structures of the eyeball, especially the posterior.

Scrofulous, purulent, syphilitic, arthritic, traumatic, and sympathetic ophthalmiæ, are the inflammations which, implicating all the internal structures of the eyeball, and becoming chronic, are most apt to leave the eyeball atrophic.

Morbid enlargement of the eyeball may precede atrophy.

Atrophy of the eyeball presents itself in various degrees, from that in which it has lost merely its natural plumpness and feels soft to the touch (p. 63), to that in which it has become so flaccid and shrunk, that it is indented at the places corresponding to the recti muscles, its prominence gone, and the eyelids fallen in.

The softness and diminution of the size of the eyeball as a whole is owing in a great measure to a reduction in the mass of the vitreous body, but besides this there are disease and wasting of other structures, and especially a more or less morbid condition of the retina. With the morbid condition of the retina, indeed, it is probable that the change in the state of the vitreous body is more particularly connected. The alterations in the other structures of the eye it is not necessary here to notice in detail, much less the changes in structure, which dissection discloses, in eyes which have been long atrophic.

In atrophy of the eye, the prognosis, as regards vision, is altogether unfavorable. Even at an early stage, and though the pupil is free, and the lens still transparent, vision is very much and irretrievably deteriorated; in a more advanced stage, it is reduced to a mere perception of light and shade, or even wholly lost.

The eyeball may, in the course of internal inflammation, become

[1] Atrophia bulbi.

somewhat soft, and yet recover its natural consistence. This, according to Dr. A. Anderson, sometimes happened in cases of the postfebrile ophthalmitis above described (p. 180, et seq.), after recovery from the attack, but such a degree of softness scarcely comes under the head of atrophy of the eyeball.

Shrunk state of the eyeball from evacuation of humors.[1]

In consequence of extensive ulceration or sloughing of the cornea, or bursting of the eye, as in ocular phlegmon, the humors of the eyeball may be partially or wholly evacuated; the effect of this is collapse of the tunics, and after cicatrization, the reduction of the eye to a mere stump.

This state of the eyeball is to be distinguished from *atrophy*.

APPENDIX TO THE PRECEDING SECTION.

Adaptation of an artificial eye.[2]

An artificial eye is a shell of enamel, representing the front of the eyeball, the loss of which it is intended to conceal. It should be of such a shape as to admit of being introduced behind the eyelids, and of fitting, by its hollow posterior surface, over, but without touching or at least pressing on, the stump-like remains of the eye, and by its margins, into the folds formed by the reflection of the palpebral and ocular portions of the conjunctiva into each other.

The cases best adapted for the wearing of an artificial eye are those in which the eye, at the same time that it has been destroyed as an organ of vision, has been reduced in size, viz.:

1st. Those cases in which the cornea is destroyed by purulent ophthalmia, whether in adults or new-born infants, by gonorrhœal ophthalmia, variolous ophthalmia, &c., and in which staphyloma has not resulted, but the cicatrice formed in the place of the cornea is flat (p. 198).

2d. Those cases in which the eye is intentionally reduced to the state just described by the operation for staphyloma, common (p. 198), or sclerotic (p. 204).

When the remains of the eye are of a very small size, as after the loss of much or all of the vitreous humor, as may happen from the bursting of the eye in purulent ophthalmia, or in ocular phlegmon, or during the operation for staphyloma, there is not a good support for an artificial eye. After extirpation of the eyeball, there is no support at all.

Cases of atrophy of the eyeball do not in general bear the wearing of an eyeball.

Of course before the use of an artificial eye is thought of, the remains of the eye must be perfectly cicatrized, and the conjunctiva free from inflammation and morbid sensibility.

[1] Phthisis bulbi. [2] Prothesis ocularis.

An artificial eye, besides resembling the opposite sound eye, in prominence and in the color and appearance of the iris, ought, if the stump be good, to move in concert with it; this it does by following the movements communicated to the conjunctival folds, into which its margins are fitted, by the movements of the stump. It ought, at the same time, to cause no pain or uneasiness.

For the accomplishment of all this, it is advisable for the patient to apply personally to the artificial eye maker.

Introduction of an artificial eye.—Raise the upper eyelid and slide the artificial eye, previously dipped in cold water, up behind it, by the end which is to correspond to the temporal angle. Then turning this end towards the temporal angle, and letting the upper eyelid fall, depress forcibly the lower, and make the lower edge of the artificial eye slip into the lower palpebral sinus. This being done, and the lower eyelid allowed to rise, the introduction of the artificial eye is accomplished.

Removal of an artificial eye.—The artificial eye is withdrawn by an opposite procedure, viz., by depressing the lower eyelid, and with a large pin, or a bit of wire bent like a hook, or even the thumb-nail, hooking the lower edge of the eye out from the lower palpebral sinus, whereupon the eye will glide down from behind the upper eyelid, and fall into the hand ready to receive it. In doing this himself, the patient should lean his face over a soft cushion, or the like, in order that if the eye should slip out of his fingers, it may not be broken in the fall.

The artificial eye is withdrawn on going to bed. Immediately on being withdrawn, it is to be put into water in order to cleanse it from the mucus which may be adherent to it.

Both before putting in the artificial eye, and after withdrawing it the person should bathe his eye with water, tepid or cold.

From the irritation excited by the artificial eye, the palpebral conjunctiva is apt to become much congested and beset with sarcomatous or polypus-like excrescences. In this case the use of the artificial eye requires to be discontinued for some time, the excrescences are to be snipped off with scissors, and the conjunctiva freely scarified. The bleeding, which is considerable, having ceased, the strong red precipitate ointment is to be applied to the surface. This may require to be repeated oftener than once, at intervals of a few days, the patient in the meantime bathing the eye twice or thrice a day with the bichloride of mercury lotion.

The artificial eye in the course of a few months becomes rough, from the slow corrosive action of the humors which come into contact with it, and requires to be exchanged for a new one. As it is also liable to be broken by accident, a person using an artificial eye should always have several ready by him.

CHAPTER III.

SECTION I.—DROPSIES, TUMORS, CANCER, ETC., OF THE EYEBALL.

Conical cornea.[1]

Objective characters.—Viewed in front, the eye affected with conical cornea has a peculiarly brilliant and sparkling appearance, in consequence of the mode in which it reflects the light. Viewed in profile, the conical prominence is evident, and the cornea appears dark between the apex and base of the cone. When the prominence of the cornea is very considerable, the eye cannot be kept long and steadily directed forward, but is, by the action of the eyelids, always turned either to the one angle or the other. From the irritation to which it is exposed, the apex of the cone is apt to become more or less opaque, and even ulcerated.

Fig. 17.



Subjective symptoms.—Short-sightedness first attracts attention, by-and-by vision becomes very indistinct at any distance. The patient can then recognize objects only when held close to the eye to one or other side, so that the rays of light may pass through the cornea as near its circumference as is compatible with their entrance into the pupil. In this state, half closing the eyelids or looking through a small aperture, assists vision.

Conical cornea is rather a rare affection. Females have been found more frequently the subjects of it than males. Though it occurs most commonly after puberty, Mr. Wardrop has met with conical cornea in a boy of eight, and Dr. Ammon once saw it congenital in three sisters. Both eyes usually become affected either at the same time or one after the other. Less commonly is the disease limited to one eye. For the most part, the cornea slowly undergoes the change to the conical form.

Morbid anatomy.—Opinion has been divided on this point; some asserting that the centre of the cornea is thickened, others maintaining the contrary to be the fact. The late Dr. Jaeger, of Erlangen, examined the eyes of a person affected with conical cornea, who died of phthisis. The middle of the cornea forming the apex of the cone was in the right eye one-third, and in the left

[1] Hyperkeratosis—Staphyloma pellucidum—Conical hydrophthalmia.

eye one-half thinner than natural. In both eyes the circumferential portion of the cornea was thickened. Mr. Middlemore[1] has also had an opportunity of examining, after death, the state of the cornea in a person affected with the disease in an extreme degree. He found the circumference of the cornea of the ordinary and natural thickness, but its apex much thinner than usual. The same has been since observed by others.

The *causes* of conical transformation of the cornea are unknown. It is not necessarily connected with preceding inflammation, though in some cases this has been observed. In the cases which have come under my notice, the patients have been of a scrofulous constitution with coarse dark skin.

Diagnosis.—The morbid affections of the cornea, which might be confounded with conical cornea, are:

1st. The prominent cornea, occurring as a consequence of corneitis (p. 201, et seq.)

2d. Hernia of the cornea (p. 192).

3d. Partial staphyloma of the cornea and iris (p. 192).

The characteristics of these, and their differences from conical cornea, are pointed out in the proper place; here it is necessary only to remark that, as in the early stage, the vivid reflection of the light is not very striking; the nature of the case may be altogether overlooked, if the practitioner does not take care to examine the eye from the side.

In respect to its subjective symptoms alone, viz., the increasing short-sightedness, and at last indistinctness of vision at any distance, a case of conical cornea might be confounded with amblyopia (p. 168), or incipient cataract (p. 168).

In illustration of the characters of conical cornea, the following two cases are given:

A young man, æt. 21.—The cornea of the left eye is conical in an extreme degree—running almost into a point at the middle. Here it is slightly opaque, with streaks radiating towards the circumference. The cornea of the right eye much less affected. The sight of the left eye is so imperfect that the patient cannot make out pretty large type, except with great difficulty, and only when he holds the book in the closest proximity to the eye. Concave glasses do not help the sight. The sight of the right eye is as yet only myopic, and is somewhat improved by a concave glass.

The skin dark, with the sebaceous follicles of the face considerably developed. The urinary secretion deranged.

A young woman, æt. 21.—Skin dark and coarse. Three years ago, or more, she discovered the sight of the left eye to be dim. Since then the dimness has gone on to increase. Lately the vision

[1] Treatise, vol. i. p. 533.

of the right eye has become dim; she requires to hold the book as near the left eye as two inches to be enabled to read it. With the right eye can still read distinctly at the distance of six or eight inches. On examination, the cornea of the left is seen to be conical. Reflection of the light by the cornea is very striking. A little below the middle of the same cornea there are two very minute spots of opacity. The cornea of the right eye is slightly prominent, and reflects the light like the left cornea but in a less degree. She has such a feeling of uneasiness of the eyes, that it prompts her to close them in order to obtain relief. Sometimes she had a shooting pain in the temple, sometimes a throbbing in the eyeball. Some months ago used to see sparks of fire before the eyes; this, although not quite gone, is much diminished.

The *prognosis* of conical cornea is unfavorable. Sometimes the disease, after a slight degree of development, has its further progress arrested. In general, however, the sight goes on to become dimmer and dimmer.

Treatment.—In entering upon this part of the subject, it is well to premise, that restoration of the cornea to its natural form is not to be calculated on. The only indications, therefore, are to arrest the deforming process, and to provide some kind of glass calculated to compensate the malformation of the cornea; or to try by an operation to rectify somewhat the disordered optical condition of the eye.

As a means of arresting the deforming process, counter-irritation, astringents locally, and tonics, or iodine internally, have had some equivocal testimony in their favor. So, likewise, repeated evacuation of the aqueous humor.

As to glasses, deep concaves afford assistance to vision in the slighter degrees of the complaint.

In a woman, about seventy years of age, affected at the same time with conical cornea and cataracts, Sir William Adams successfully removed the latter, and found that the patient could afterwards see much more distinctly without convex glasses, than is usual for those who have undergone the operation of cataract. Encouraged by this, he removed the transparent crystalline lens, by the operation of division, from one of the eyes of a young woman affected with conical cornea in both. The ultimate result, he says, was beneficial. Others, however, assert, that the operation does no good, which theoretically was to have been expected, as a concave glass was likely to afford all the assistance which removal of the lens could by possibility do.

Dilatation of the pupil by belladonna has been said to assist vision. This it may do by allowing the rays to enter the eye through the less deformed circumference of the cornea. In the

second of the above cases, however, the sight became dimmer after the use of belladonna. On the same principle, Adams' operation of dislocating the pupil has been proposed by Mr. Middlemore; and Mr. Tyrrell[1] informs us that he has put it in practice seven or eight times, and in each case with benefit, which in two especially was very considerable. In no instance did any evil follow. The operation consists simply in making a puncture, with an iris-knife or the point of a cataract-knife, through the cornea close to the sclerotica, and *prolapsing* a portion of the iris, so as to bring the pupil from behind the apex of the cone.

Hydrophthalmia.

The morbid accumulation of watery fluid which constitutes hydrophthalmia, may have its seat in the aqueous chambers (*anterior hydrophthalmia*), or in the vitreous body (*posterior hydrophthalmia*), or in both at the same time (*general hydrophthalmia*), or it may have its seat between the sclerotic and choroid (*sub-sclerotic dropsy*), or between the choroid and retina (*sub-choroid dropsy*).

Anterior hydrophthalmia, or dropsy of the aqueous chambers.—This, as it occurs in consequence of corneitis, has been above described (p. 201), and it was stated that the cornea is increased in prominence, but not much in diameter. In cases, apparently not depending on inflammation, the cornea is more increased in diameter than in prominence, and may be either still transparent, or cloudy, or opaque.

The sclerotica where it joins the cornea is distended, thin, and of bluish color. The conjunctiva is pervaded by enlarged and tortuous vessels.

The iris is more or less affected. It has a dark, dead, dull appearance, and is perhaps found to be tremulous. The pupil is usually in a middle state between contraction and dilatation, is motionless, and has its margin directed backwards. In the course of the disease, it contracts adhesions to the crystalline body, which will probably be found opaque.

The eyeball is hard to the touch, except in an advanced stage, when it is often soft from commencing atrophy.

The patient experiences an uneasy feeling of distension in the eyeball, which he moves about in the orbit with difficulty in proportion to its enlargement. Muscæ float before the eyes, and amaurotic dimness of vision succeeds to short-sightedness. Total blindness may at last result.

Causes.—A cachectic state of constitution is a predisposing cause

[1] A Practical Work on the Diseases of the Eye, &c.; vol. i. p. 277. London, 1840.

of the anterior hydrophthalmia under notice. Its exciting cause is sometimes an injury, but in general its etiology is obscure.

Prognosis.—This is in general unfavorable. The disease may remain stationary, with vision much impaired, or the eye may become partially atrophied, or general hydrophthalmia may supervene —in either case with total blindness.

Treatment.—The treatment above indicated for dropsy of the aqueous chambers, consequent to corneitis or aquo-capsulitis, viz., repeated evacuation of the aqueous humor, friction with mercurial or iodine ointment, round the eye, blisters behind the ears, change of air, tonics, &c., may be tried.

Dropsy of the aqueous chambers sometimes occurs congenitally. The cornea is more increased in diameter than in prominence, and is at the same time opaque or cloudy.

Congenital dropsy of the aqueous chambers with opacity of the cornea, appears to be a sort of imperfect development as regards the opacity, at least a retention of the fœtal character of the cornea; for in the fœtus the cornea is opaque, and becomes clear only towards the period of birth.

Congenital anterior hydrophthalmia may persist or pass into general hydrophthalmia. In a few instances, however, the cornea has, with the growth of the child, been found gradually to clear, and vision, though myopic, to be acquired. Mr. Ware[1] relates several such cases, three of which occurred in one family. In two of the children the opacity was quite removed in less than a year; in the third the transparency was not complete until the end of the second year. The corneæ remained very prominent, and the vision myopic. In another case both corneæ were large, prominent, and completely opaque at birth. At the end of nearly three years, the left cornea had become clear enough to allow the perception of large objects; the opacity of the right cornea, though diminished round the circumference, remained at the centre so as to obscure the greater part of the pupil. In a fifth case, similar to the preceding, improvement had, at the end of a year, proceeded so far in one eye that the circumference of the cornea was quite transparent, and the opacity so far diminished in the centre that the pupil could be seen. Improvement was less advanced in the other eye. It is worthy of remark, that in these cases, the clearing of the cornea proceeded from the circumference towards the centre, a course similar to what is observed in acquired opacity of the cornea.

Posterior hydrophthalmia, or dropsy of the vitreous body.—The anterior segment may be unchanged, except that the iris is pressed towards the cornea, and the pupil wide and motionless.

[1] Observations on the Treatment of the Epiphora, &c., p. 285, London, 1813.

The sclerotica is distended and bluish. The eyeball is very hard, and is with difficulty moved in its socket. The vitreous humor is generally in a dissolved state.

In the stage of development of the disease, there is very severe pain in the eye, extending all over the side of the head. Photopsy; vision, at the same time, goes on diminishing until all sensibility to light is gone.

Causes.—Little is known of the process leading to the disease, farther than that it is in general dependent on a cachectic state of constitution.

The *prognosis* is altogether unfavorable.

Treatment.—The eye is to be tapped through the sclerotica and choroid where they bulge most, with an iris-knife, directed as if towards the centre of the eye; or if there is not much bulging in view, about one-fifth of an inch behind the margin of the cornea. Repeated tapping may be necessary, and if this fail, the cornea is to be opened, and the lens extracted, along with a portion of the vitreous humor—in order, should the opposite eye be sound, that the eyeball may shrink to a small size, fit for the adaptation of an artificial eye.

When the puncture is made through the sclerotica and choroid, the vitreous humor is apt, as above mentioned in choroid staphyloma, to infiltrate the sub-conjunctival cellular membrane to an enormous extent, sometimes to such a degree, that the cornea is hid by the swelling. In one case in which this event happened in the hands of Dr. Mackenzie, the pain which ensued was severe; but the dropsy was cured by the continued pressure, exercised for ten or twelve days on the empty eyeball, by the fluid lying under the conjunctiva.

General hydrophthalmia.—From the great size the eyeball attains, this has been also named *Ox-eye* or *Buphthalmos.* General hydrophthalmia is a combination of anterior and posterior hydrophthalmia. The eyeball is protruded from the socket, stretching the eyelids, and is usually more or less disorganized. Vision is extinct. There is no remedy except evacuation of some of the contents of the eyeball, to relieve pain, and to effect the reduction of the eyeball to a small size by the means above mentioned.

Sub-sclerotic and *sub-choroid* dropsy have been referred to in connection with sclerotic staphyloma (p. 203, et seq.) The form of hydrophthalmia here to be noticed is that in which the sclerotica is unaffected, but in which there is accumulation of fluid between the choroid and retina, causing the latter to bulge forward in the vitreous humor now in a discolored state.

By means of the ophthalmoscope, this bulging forward, as also

a tremulous fluctuating movement of the retina, is distinctly seen in the dissolved vitreous body, as represented in the annexed figure, from Jaeger, Junr.

Fig. 18.

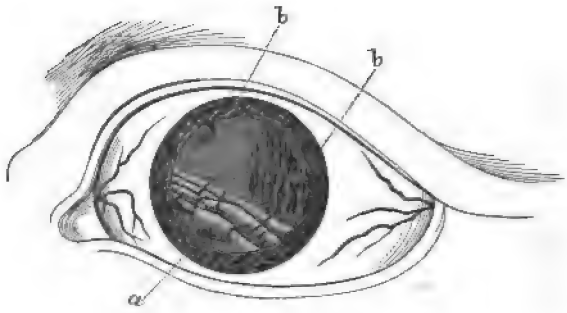

a. The bulging retina. *b b*. Deposits of pigment.

By the pressure of the accumulated fluid between the choroid and retina, absorption of the vitreous humor is apt to take place altogether. The result is coarctation of the retina into the form of a cone, having its base at the lens, and its apex at the entrance of the optic nerve. The retina thus crumpled together appears as an opaque body behind the dilated pupil, and has been mistaken sometimes for cataract, sometimes for fungous disease of the eye.

Hæmophthalmus.

Extravasation of blood under the conjunctiva has been named *Hæmophthalmus externus*, in contradistinction to effusion of blood within the eye, which has been named *Hæmophthalmus internus*.

Hæmophthalmus externus, called also *conjunctival ecchymosis*, may be occasioned by various causes, such as blows on the eye or its neighborhood, efforts, purpura. Its occurrence in connection with inflammation, has been above noticed (p. 88). Sometimes it occurs without any evident cause.

Treatment.—Left to itself, the blood is gradually absorbed; but the absorption appears to be hastened by the application of the nitrate of silver drops, the red precipitate salve, or the like.

Hæmophthalmus internus, when not the immediate result of injury, most generally occurs in eyes already in an unhealthy state from previous injury or inflammation. It sometimes supervenes in the course of internal ophthalmia (p. 101); and in cases of females affected at the same time with amenorrhœa, it has been observed

to recur about the menstrual period.[1] Hæmophthalmus internus may take place in consequence of unusual bodily exertion[2]—no evident cause operating directly on the eye—and afterwards recur repeatedly and even periodically.[3] In purpura hæmorrhagica, an effusion of blood has occurred within both eyes.[4]

The appearance presented in hæmophthalmus internus is the blood, in greater or less quantity, in the anterior chamber.

Treatment.—Blood effused into the eye is in general readily absorbed, and considered by itself alone, requires no interference, unless the chambers of the eye be very much distended, when a puncture of the cornea may be required to give it issue.

In the forms of hæmophthalmus just described, the effused blood is seen at a glance. Besides these, however, extravasations occur at the bottom of the eye implicating the retina, which are visible only by means of the ophthalmoscope (pp. 62, 101, et seq.)

As the conjunctival ecchymosis sometimes presents itself in connection with inflammation, sometimes without any evident cause (p. 214), so the extravasations just referred to come on, some in the course of posterior internal inflammation—some, suddenly without any apparent cause. The existence of the latter is first indicated by the amaurotic symptoms occasioned by the pressure on the retina.

The *treatment* must be the general antiphlogistic above described (p. 110, et seq.) See further on the subject the article *Amaurosis*.

Hydatid (cysticercus cellulosæ) in the anterior chamber.[5]

Five cases at least are on record in which a living hydatid, floating free in the aqueous humor, was observed. In a sixth case, a hydatid was discharged through an incision in the cornea, made for the purpose of evacuating the aqueous humor; but its existence, while actually within the eye, was not recognized, in consequence of opacity of the cornea, from chronic inflammation.

In the first case, which is recorded by Dr. W. Soemmering (Isis von Oken, 1830), and the subject of which was a healthy girl of eighteen, the hydatid was discovered soon after an ophthalmia.

[1] A very interesting case of internal ophthalmia, attended with aggravation of the symptoms, and effusion of blood into the anterior chamber at monthly periods, in a young female in whom the menses had not yet regularly appeared, has been recorded by Mr. Tyrrell in his "Practical Work," vol. ii. p. 40.

[2] See Mackenzie's Practical Treatise, Hewson's Am. Ed. p. 668.

[3] A remarkable case of this is related by Mr. John Bell ("Principles of Surgery," vol. iii. p. 270, London, 1808), and a somewhat similar one by Professor Von Walther (Merkwueridge Heilung, eines Eiterauges, p. 61. Landshut, 1810).

[4] See a case communicated to Dr. Graves by Dr. Boxwell, of Abbeyleix (Dublin Journal of Medical Science, vol. xi. p. 395. Dublin, 1837).

[5] Hydatids in the cellular substance of the eyelids, and under the conjunctiva, are spoken of below.

The subject of the second case, which occurred in 1833, and which was first described by Mr. Logan, subsequently by Dr. Mackenzie (Med. Gaz. vol. xii, and Treatise, &c.), was a healthy-looking girl, seven years of age. In this, as in Soemmering's case, the hydatid appeared after ophthalmia, in consequence of which there was slight opacity of the cornea.

This latter case I had the opportunity of examining and attending after the operation. The tail-vesicle of the animal was about one-sixth of an inch in diameter, semi-transparent, and might be seen sometimes contracting, sometimes expanding, and at the same time undergoing slight changes of form. The body and head were sometimes retracted within, sometimes protruded from the tail-vesicle, the part of which connected with the body and head, was always the most depending. When the body and head were protruded, and hanging downwards, the animal resembled a miniature balloon.

The third case is thus described by Dr. Mackenzie[1] in whose practice it occurred:

Elizabeth Gordon, aged sixteen years, applied at the Glasgow Eye Infirmary, on the 26th September, on account of obscurity of vision in her left eye. In the anterior chamber, close in front of the pupil, which, in a bright light, it completely covered, lay a spherical body, about one-eighth of an inch in diameter, semi-transparent, and having a good deal the appearance, at first view, of the nucleus of the crystalline lens. On observing it for some little time it was evident that it was a vesicle, changing occasionally its form and position, and protruding by times from its lower edge an opaque white filament. The part first mentioned was, in fact, the tail-vesicle of a cysticercus cellulosa, and the latter its body and head. The head was seen to be occasionally thrown down nearly to the bottom of the anterior chamber, and then drawn up completely into the tail-vesicle.

The patient stated, that about the middle of June the left eye had been affected with inflammation, which continued for about three weeks, and was removed after the application of a poultice of rotten apples, immediately after which the hydatid was noticed.

She seemed in good health, but stated that she never had been robust, and when a child, had been troubled with ascarides and lumbrici.

In general the patient made no complaint of pain. Of the motions of the hydatid she was quite unconscious.

The fourth case also occurred to Dr. Mackenzie shortly after the preceding. The subject was a man from the north of England.

[1] Case of cysticercus cellulosæ in the anterior chamber of the human eye. In Med.-Chir. Trans. vol. xxxii, 1849. [See Treatise on the eye. Hewson's Am. ed. p. 1010.)

The fifth case occurred about ten years ago, at the Westminster Ophthalmic Hospital, and the hydatid, after extraction, was brought to me by Mr. Canton for examination, to whose kindness I am indebted also for having subsequently had an opportunity of seeing the patient, who was a boy about ten years of age. I found the cornea semi-opaque and vascular, and increased both in diameter and prominence.

The hydatid in this case was more than double the size of that in the preceding, and its appearance at first sight suggested the idea, that it was the lens and vitreous body—the former opaque and contracted, the latter shrivelled, by the draining away of the contained humor; but a slight examination of the body was sufficient to point to its true nature which a microscopical dissection confirmed.

Treatment.—In Soemmering's case, uneasiness was experienced from the presence of the animal in the eye only when it moved. Increasing in size, however, it was removed by Dr. Schott, who after having made a small section of the cornea, introduced a pair of hooked forceps into the anterior chamber, seized the hydatid and extracted it alive.

In Mr. Logan's case, no uneasiness was at first experienced, but subsequently pain and redness of the eye setting in, an attempt was made by Dr. Robertson, of Edinburgh, to extract the animal. In consequence, however, of the unsteadiness of the child, the operation did not turn out well; the lens escaped, the iris protruded, and the hydatid was ruptured, but the shreds of it were eventually removed. After the operation, I attended the case in Dr. Robertson's absence. The eye healed, with a broad cicatrice of the cornea, and the pupil remained contracted, distorted, and obstructed with opaque capsule.

In operating on Elizabeth Gordon, Dr. Mackenzie imitated the plan followed by Dr. Schott in Soemmering's case, except that he used Schlagintweit's hook instead of forceps for seizing the hydatid.

"I made," says Dr. M., "a puncture with Beer's pyramidal knife, at the temporal edge of the cornea, to the extent of $\frac{3}{20}$ of an inch. A little of the aqueous humor escaping as I withdrew the knife, the tail-vesicle of the hydatid became flattened and much expanded between the iris and cornea. I immediately passed Schlagintweit's hook through the wound, seized the body of the hydatid with it, and easily withdrew the animal entire. The iris protruded somewhat through the wound, but was readily reduced by friction through the medium of the upper eyelid, so that the pupil resumed its natural form and place. The patient was sent to bed, and ordered to keep her eyes shut, and the left eye covered with a wet rag.

"Next day the patient felt quite well; the eye appeared natural, and she said she saw as well with it as the other. No reaction followed, and she was dismissed on the 21st October."

In the treatment of his second case, Dr. Mackenzie followed the same plan, and was equally successful.

The sixth case is recorded by Dr. A. von Graefe, of Berlin, who has also related four cases in which, by means of the ophthalmoscope, he detected a cysticercus deep in the eye. In one of these the hydatid was in the vitreous humor behind the lens; in the other three it lay on the retina, and destroyed vision.

Among the cases mentioned in the last edition of this treatise was one recorded by Neumann in Rust's Magazine, vol. xxxiii. Dr. Mackenzie, however, has shown that the supposed hydatid was merely the lens dislocated into the anterior chamber. The patient was a scrofulous boy, fourteen years of age. The lens slipped back into the pupil while this was dilated by belladonna, and was retained there; the pupil appearing to have contracted around it. Severe pain came on. A needle was passed through the cornea, the body disengaged from the pupil, and couched, but on the third day after this, violent inflammation of the eyeball took place which ended in suppuration.

Appia has published a case of cysticercus in the cornea.

In horses in India, during the cold season, a species of filaria, or thread-worm, about an inch long and whitish, moving freely about in the anterior chamber, is not unfrequently observed. In horses in Europe, instances of the same thing, though not unknown, are rare. The worm, unless extracted, excites inflammation of the eye with dimness of the cornea. Extraction is effected through a small incision of the cornea, the aqueous humor, as it escapes, carrying the animal along with it.

No instance is known of a filaria in the anterior chamber of the human eye, but filariæ have been met with in cataractous lenses, after excavations, as also monostomata and distomata. These, however, were not recognizable while within the eye, having been discovered only on minute examination of the extracted lens with magnifying glasses. They do not appear to be of any practical consequence.

Non-malignant tumors of the eyeball.

Various kinds of growths, cysts, &c., are met with, sometimes connected with the sclerotica, and cornea,[2] sometimes with the iris

[1] As will be mentioned below, a species of filaria has also been found under the conjunctiva of the human eye.

[2] The sclerotica and cornea are more or less involved in the growths and tumors of the ocular conjunctiva. See below.

sometimes with the ciliary body and choroid, sometimes with the retina and the vitreous body.

In regard to non-malignant growths connected with the retina and the vitreous body, it is to be observed, that they give rise to a yellow shining metallic appearance, sometimes traversed by blood-vessels, at the bottom of the eye. A similar appearance is presented in incipient cases of medullary fungus of the retina, and is not uncommon after injury of the eyeball.

These different cases have, therefore, often been confounded together. Indeed, the appearance in question used to be considered so certainly pathognomonic of medullary fungus of the retina, that every case in which it presented itself was pronounced to be one of this formidable disease. It having been observed, however, that many such cases, being left alone, eventually so far did well, that the disease did not go on to the destruction of the patient, but ended merely in atrophy of the eyeball, surgeons are now agreed that, though suspicious, the yellow appearance at the bottom of the eye does not always indicate medullary fungus.

It must be confessed, however, that there is in general no certain means of determining the nature of the case *à priori*. It is rather by its result that we pronounce on the point. It may be observed, however, that, in some cases, the termination of which in atrophy of the eyeball proved their non-malignant nature, the diseased appearances presented themselves after injury of the eyeball, and were from the first attended by inflammation. In such cases the pupil was of medium size, and as atrophy of the eyeball proceeded, the iris became wrinkled, its middle part sunk in, and its pupillary margin projecting forwards.

Treatment.—For the treatment of the various kinds of growths under consideration, no general rule can be laid down. Often the best practice is not to intefere with them except when external. Atrophy of the eyeball is in general the common and most desirable result of internal growths.

In illustration of the treatment of cysts in connection with the iris, the following cases are given:

In one case, a cyst, of the size of a small pea, and glistening like tendon, formed in connection with the iris of a boy, an apprentice to a blacksmith, some months after severe inflammation, produced by a small particle of hot iron, which penetrated the cornea and lodged in the iris. In another case, the subject of which was a girl, about nine years of age, a similar disease occurred a few months after inflammation brought on by the eye being struck with some bearded corn. *In both cases the cyst was removed by operation.* In the first case the patient did not retain useful vision afterwards. In the second, iritis came on, to which was soon joined

sympathetic iritis in the other eye. The inflammation was eventually stopped, and the eye secondarily affected recovered; but that on which the operation had been performed retained the power to perceive large objects only.[1]

In a third case, a lady was affected with considerable pain in one of her eyes, which, on examination, presented a small vesicle protruding from the posterior into the bottom of the anterior chamber, under the ciliary margin of the iris. The vesicle gradually increased, separating the iris more and more from the choroid, and the pain became severe. *The vesicle or encysted tumor was punctured with the iris-knife through the cornea.* A minute quantity of fluid was discharged from the cyst, which immediately contracted so much that it was no longer visible. The pain was removed. The cyst, however, filled again with fluid, and again appeared in its former situation, but larger than before. *It was punctured a second and a third time at intervals of six and eight weeks.* After the third puncture it did not fill again. The iris returned to its natural place; the pain ceased entirely; and vision was preserved.[2]

A boy, about five years old, was received into University College Hospital, with a cyst in the left eye, similar to the preceding. It protruded from the posterior into the anterior chamber, the lower part of the iris having become detached from its ciliary connection, and pushed upwards.

About a year and a half before, the child had accidentally thrust the point of a fork into the left eye. From the immediate effects of this injury recovery took place in about three weeks. A small opacity at the lower margin of the cornea, close to its junction with the sclerotica, indicated where the wound had been inflicted. From that time the eye continued well until about two months before his admission into the hospital, when an attack of inflammation came on, attended by intolerance of light and lacrymation.

The cyst was punctured through the cornea, and a considerable quantity of fluid evacuated, whereupon the delicate wall fell collapsed to the bottom of the anterior chamber, while from day to day the detached portion of the iris regained its natural position, and the pupil its form and size.

Some time after, however, about six weeks from the time the first puncture was made, the cyst had again filled, so that it was considered advisable to repeat the operation. Three or four days after this inflammation came on, and a small quantity of yellow matter appeared at the bottom of the collapsed cyst. The inflammation and deposit of matter having increased, leeches and warm fomentations to the eye, and small doses of calomel three times a

[1] Tyrrell's Practical Work on the Eye, vol. i. p. 368, et seq.
[2] Mackenzie's Practical Treatise on the Diseases of the Eye, Am. ed. p. 673.

day, were ordered. The inflammation now subsided, and the matter of the cyst worked its way outwards, and some of it was evacuated at the junction of the cornea and sclerotica by a narrow outlet, a mode of evacuation of matter from the anterior chamber, such as I have seen before in cases of iritis, with abscess of the ciliary margin of the iris. After this, the cyst collapsed, and together with the rest of the matter, gradually disappeared to a mere trace at the bottom of the anterior chamber. The pupil regained its natural size and form, and sight was perfectly retained.

Scirrhus of the eyeball.[1]

Under the name of *scirrhus* of the eyeball, some authors describe a disorganized state of it, characterized by its being misshapen and indurated, shrunk in size, or if enlarged, but little so, whilst its natural structure is replaced by one having the characters of scirrhus—by it being the seat of burning heat and lancinating pain, and attended by hemicrania in nocturnal paroxysms—by its being slow in its progress, occurring in advanced life, in women rather than in men—continuing long without ulceration, and without any implication of the eyelids and neighboring parts, though eventually ulceration of the eyeball, and implication of the neighboring parts, may take place, and the whole eye thus become the seat of open cancer, the neighboring lymphatic glands of the head and neck being at the same time enlarged, hard, and painful. But such a disease of the eyeball occurring primarily, does not appear to be common. *See Cancer of the Eyelids.*

Medullary or encephaloid fungus of the eyeball.[2]

Encephaloid fungus of the eyeball occurs principally in early childhood, though not exclusively confined to that period of life, and has its origin generally in the optic nerve, and within the eye, though sometimes outside the eyeball, springing, perhaps, from the sclerotica, and implicating the cornea.

In encephaloid, originating in the retina, three principal stages are recognized. In the *first stage* the eyeball is still of its natural size and general appearance, except that the pupil is more or less dilated, and through it a brilliant reflection from the bottom of the eye is seen. In the *second stage*, the diseased growth, though still confined within the tunics, has advanced towards the anterior part of the eyeball, which has become bloodshot, and more or less enlarged and misshapen from distension. In the *third stage* the tu-

[1] Hard cancer of the eyeball.

[2] Soft cancer—Fungus hæmatodes.

nics have given way, and the tumor protrudes in the form of a fungus.

First stage.—Through the pupil, which is more or less dilated, irregular, and either sluggish or altogether immovable, or movable only in concert with the pupil of the sound eye, there is seen, under certain lights, a whitish-yellow or reddish-yellow reflection from the bottom of the eye, somewhat resembling that in the eye of the cat. This, on close examination, is perhaps discovered to be owing to the presence of an adventitious substance in the form of a small lobulated tumor, apparently arising from some part of the retina. Red vessels are sometimes seen ramifying on it.

The vision of the eye may be lost from the first, or it may be still partially retained, objects being seen in certain directions. There is in general no pain, unless there be, as is sometimes, though not generally, the case, attendant inflammation, when, as accompaniments of this, there are epiphora, intolerance of light, and headache.

Second stage.—The disease may remain in this state for months, or even two or three years; but sooner or later, the morbid growth begins to increase, and continues to do so sometimes with such rapidity, that in the course of a few weeks perhaps it will, at the expense of the vitreous humor, have advanced to the front of the eye, pressing the lens and discolored iris against the cornea. The eye is now more or less inflamed.

The advancing growth is seen through the now much dilated pupil to be more or less distinctly lobulated, and to have bloodvessels ramifying on its surface.

By-and-by the lens becomes opaque and amber-colored. The growth being thus concealed, and the general appearance of the eyeball not being as yet very much changed, cases in this part of their progress have been mistaken for cataract, and attempts made to operate.

The eyeball gradually becomes more enlarged and misshapen from distension, by the increasing growth of the tumor, and pervaded by varicose vessels. The cornea is much increased in diameter, vascular, and more or less opaque, and ulcerates; whilst the sclerotica, the boundary between which and the cornea is no longer visible, attenuated and discolored, bulges out here and there. In this state the eyeball protrudes from the orbit, and is ready to burst; perhaps the attenuated sclerotica has at some part actually given way, and the tumor, retained by the conjunctiva alone, appears both to the sight and the touch something like an abscess.

The eyelids are distended, swollen, and pervaded by enlarged veins.

Besides pain in the eye, and perhaps intolerance of light, with

epiphora, there is pain chiefly in the forehead, vertex, and nape, occurring in paroxysms, which are more severe during the night than during the day.

There is general constitutional disturbance, costiveness, nausea, thirst, loss of appetite, restlessness, fever, delirium.

Third stage.—The cornea giving way, a fetid, bloody, yellowish fluid, together with the lens, if this has not been already absorbed, is discharged, with some alleviation to the sufferings of the patient. The tumor now protrudes in its well-known form of bleeding brain-like fungus. When it bursts through the sclerotica, it may be retained, as above said, for some time, by the conjunctiva; but this at last giving way, it protrudes; severe pain attends this process.

The eyelids are now greatly distended, everted, livid, and pervaded by large tortuous veins.

The lymphatic glands of the cheek and neck enlarge.

The other eye frequently becomes affected, and that even at an early period. Both eyes may be nearly equally affected in the first stage of the disease.

Under the bleeding, sloughing, ulceration, and discharge, of which the fungus is the seat, and the pain and constitutional disturbance, the patient sinks comatose or convulsed.

Though medullary fungus has been found by Mr. Travers to arise in every structure of the eyeball except the lens and cornea, it nevertheless generally has its origin in the optic nervous apparatus; the other structures of the eyeball subsequently becoming infiltrated with the morbid matter. The optic nerve has been found frequently on dissection to be, in addition to the retina, affected to a greater or less extent, even its cerebral portion, as in some cases the brain is itself implicated. As a consequence of the intra-cranial disease, death by coma may occur before the disease of the eyeball has reached the fungous stage.

In some cases, the morbid growth, instead of arising from the optic nerve within the eye, and giving rise to the symptoms above detailed, arises from the optic nerve before its entrance into the eye. In this case the tumor pushes the eyeball before it, expanding and enlarging the eyelids, and at last protruding from between them, but, being covered by the conjunctiva, it does not show itself in the form of a fungus until ulceration of that membrane.

In the dissection of the bodies of those who have sunk under encephaloid disease of the eye, the same morbid degeneration has, in many cases, been found implicating other organs, such as the testicle, the viscera of the thorax, or abdomen.

Causes.—The scrofulous diathesis, being often presented by those who are the subjects of encephaloid cancer, has been viewed

in the light of a predisposing cause, but scrofula is common, and the disease in question rare. It occurs principally in early age, as above said. Mr. Travers has even seen it congenital. Males have been found more frequently the subjects of it than females. As to exciting causes, none has with certainty been detected.

Diagnosis.—The characters above given of encephaloid disease of the eyeball in the early stage, are not perfectly diagnostical of it, for, as already stated, very similar characters, viz., the yellow shining metallic appearance at the bottom of the eye, traversed sometimes by red vessels, may be presented by cases which, as is now known by multiplied experience, are not malignant. The characters even of the second stage have been seen by Dr. Mackenzie, presented in a more or less well-marked manner by non-malignant disease of the eye. In the third stage, the nature of the disease can scarcely be mistaken; but even in the earlier stages, the diagnosis is of no great practical importance, as nothing more in the way of treatment ought to be done than in the non-malignant cases.

Prognosis.—This is in the last degree unfavorable. Neither medicine nor the knife is of any avail in true encephaloid disease.

Treatment.—Cases in which the appearance belonging to the early stage of encephaloid tumor existed, have sometimes turned out so far well, that the eyeball has become atrophic. Long alterative courses of mercury having been used in such cases, it might be said, as Mr. Travers remarks, that they were examples of malignant disease, arrested by this treatment, and not mere examples of non-malignant disease, which would have had the same termination without such treatment.

However this may be, alteratives, the occasional application of leeches, with careful regulation of the bowels, diet, and regimen, constitute the only treatment which experience shows is admissible. Extirpation of the eyeball has been too generally unsuccessful to allow us to hope anything from such a resource. The few cases recorded as recoveries after extirpation, there is every reason to believe were not cases of true encephaloid, but merely of non-malignant disease above noticed (pp. 202, 203), and which would have undergone a spontaneous cure by atrophy whether they had been left to themselves, or subjected to the treatment above mentioned as the only one admissible.

In the advanced stages of the disease, anodynes are required, both internally and externally.

The following case affords a good illustration of the progress of encephaloid disease of the eyeball:

The patient was a girl about six years old, but very little for her

age. When I first examined the eye, I perceived a whitish-yellow lobulated tumor growing forward from the lower and outer part of the bottom of the eye. (Fig. 19.) Towards the lower part of the prominent surface there was a vascular spot. Pupillary margin of the iris bordered with uvea. The pupil was natural—contracted under the influence of light, and was dilatable by belladonna. The lens unaffected. The diameter of the cornea was somewhat enlarged, and the adjacent sclerotica appeared slighly distended, besides being dark and dirty-looking.

Fig. 19.

Objects below and to the temporal side could be seen, showing that the upper and inner part of the retina was as yet unaffected. No pain.

Otherwise healthy—mother's family consumptive.

Had several falls down stairs, before the disease of the eye was discovered.

Three months after this, my report states :—Of late the eye has become vascular.

Sight appears to be quite extinguished.

About a week ago the general health became suddenly disordered —costiveness, sickness at stomach, and tendency to vomit took place, with thirst and loss of appetite.

The child complains of pain in the orbit and head. Is drowsy —apt to stumble. Strength diminished.

On examination, I found the eyelids red, and somewhat swollen —upper cannot be readily raised. Eyeball rather larger, and more prominent. The pupil somewhat dilated, and immovable by the stimulus of light. The iris of a greenish color, and its pupillary margin bordered with uvea. The tumor in the interior not much changed, so far as I could determine, the child not permitting a sufficient examination.

Although sight appeared to be extinguished, there was some intolerance of light.

About nine months after the last report, that is, about a year after I first saw the child, a fungus protruded at the junction of the sclerotica and cornea, which gradually increased in size. Some bleeding and sloughing from the fungus took place, but not much.

Eight months afterwards the child died convulsed and exhausted.

On dissection, the fungus was found springing from the bottom of the eyeball. The optic nerve was increased in thickness, and the seat of the same degeneration, and continuous with a large tumor of the same kind at the base of the brain.

The external tumor was half the size of my fist, and black.

Melanosis of the eyeball.

Melanosis of the eyeball occurs in the middle period of life, more frequently in females than males, and is in general slow in its progress.

According to the part of the eyeball in which it arises, so do the appearances differ which present themselves at the commencement, and the degree in which vision is impaired. If the morbid growth has its origin in the coats of the eyeball, in the region of the ciliary body for example, it first makes its appearance shining through the sclerotica, in the form of one large or several small blackish elevations near the margin of the cornea, the white of the eye presenting there enlarged and varicose vessels. The presence of the tumor behind the iris is perhaps indicated by that membrane being, at the corresponding place, pressed forward.

Perhaps there is actual detachment of the circumference of the iris at the place, and the dark mass seen making its appearance from behind. In one such case, the lens had become cataractous; in another, it had remained transparent, and vision was still in some degree retained. If the morbid growth arise from the bottom of the eye, there is first seen through the dilated pupil, a slate-colored brownish tumor, deep in the interior of the eyeball, unless the lens have become opaque. This state is attended with loss of vision. The disease proceeding, the eyeball becomes enlarged, and the black tumor at last presents itself at some part of its surface.

There are now, in consequence of the distension, inflammation and pain in and around the eye; and at last the coats of the eyeball, where the tumor presents, generally the sclerotica near the cornea, gives way, and a black fluid is first discharged, followed by the protrusion of a black or brown fungous tumor. This tumor does not in general attain any great size. It seldom bleeds much, though the contrary is sometimes the case; but it may throw off considerable quantities of black matter by sloughing. The proper structure of the eyeball becomes atrophic, being in a great measure replaced by the morbid growth, which may at the same time implicate other structures in the orbit.

Impairment of the general health attends this disease.

Simple sclerotic staphyloma has been sometimes mistaken for melanosis of the eyeball. And, indeed, there is a great resemblance between the two diseases, in the stage of the latter proceding the giving way of the sclerotica and the protrusion of the melanotic substance.

In the following case, there were first presented the symptoms of chronic arthritic ophthalmia, with glaucoma, amaurosis, and cata-

ract—then those of supervening sclerotic staphyloma, and lastly, the protrusion of the melanotic growth.

A cachectic-looking woman, æt. 63, laboring under prolapsus uteri ten months before she applied to me, found on rising one morning that she had lost the sight of the right eye, having had a severe attack of pain in it during the night. She believed that she saw well with it the day before.

On examination, the white of the eye was seen pervaded by enlarged and tortuous recto-muscular vessels, and of a dark, dirty appearance, especially next the inner corner. The pupil was dilated and fixed; the lens glaucomato-cataractous—sight completely gone—not even a perception of light.

A fortnight or three weeks before applying to me, discovered the sight of the left eye to be dim. Since that time she has noticed all manner of colored light in the dark. She has also suffered very severely from circumorbital pain on this left side as well as on the right.

The recto-muscular vessels of the left eye were seen on examination to be slightly enlarged and tortuous; the pupil natural, and the lens glaucomatous and slightly cataractous.

By treatment the sight of the left eye became somewhat more distinct, and the pain around it relieved. But the pain around the right eye continued very severe, preventing sleep, so that it was necessary to give anodynes.

The patient went on in this manner for some months, when a dark-colored projection, like a common sclerotic staphyloma, presented itself at the inner and upper part of the eyeball, along with an aggravation of the pain. After this, the pain, however, appears to have subsided: I saw nothing more of the patient for about nine months, when she applied again to me on account of the very excruciating pain she had been suffering for some days. On examination, I found the eyeball much larger than when I saw it last, and that in the situation of the staphylomatous-like projection, before mentioned, the sclerotic had just given way and melanotic matter was protruding through the opening, The cornea, through which could still be seen the dilated pupil and glaucomato-cataractous lens, was turned downwards and outwards by the projection of the upper and inner part of the eyeball.

Prognosis and treatment.—The prognosis in melanosis of the eyeball is but little more favorable than in encephaloid disease. After extirpation of the eyeball, patients have survived longer, though in most cases they have eventually sunk under melanotic affections of the viscera.[1]

[1] Melanosis in the orbit, and of the conjunctiva and eyelids, is considered under these headings.

Operation of extirpation of the eyeball.

Preparation of the patient.—This consists in rest, regulation of diet, and attention to the bowels, some time before the operation, together with the fulfilment of any other indication which the particular case may present.

Instruments, dressing, &c.—Bistoury and scalpels,—a pair of large scissors curved on the flat,—two pairs of large forceps, one a common dissecting forceps, the other a hooked forceps,—a large curved needle and strong ligature,—small suture needles and thread —water, sponges, and syringe, charpie, spread linen, lint, and roller.

Position of the patient, assistants, and operator.—The patient is to be extended on his back on a table, with his head raised by a pillow. He is then to be brought fairly under the influence of chloroform. One assistant steadies the head and takes charge of the upper eyelid; the other assistant, standing on one side of the table, takes charge of the lower eyelid, whilst the operator stands on the other side of the table—the side namely, corresponding to that side of the patient on which the operation is to be performed.

The following directions for extirpating the eye must be understood to be of a general character, such merely as are principally indicated by the anatomy of the parts. The disease for which the operation is undertaken may have occasioned such a condition of parts as to require some considerable modification in the procedure; but this must be determined by the judgment of the operator at the time. The operation comprehends the following steps:

First, or preparatory steps.—For the purpose of holding and moving about the eyeball during the operation, it is thrust through with a tenaculum, or a strong ligature is passed through it from the one side to the other, by means of a large curved needle, the ends of the string being then tied together, so as to form a loop to hold by. If the eyeball is much enlarged and protruding, it may be simply grasped with the hand, having been first wrapped round with a bit of lint.

Division of the external commissure of the eyelids.—This facilitates the operation, and obviates the risk of cutting the edges of the eyelids. Whilst the eyelids are held much asunder, and the external commissure is well drawn towards the temple, the operator pushes the sharp-pointed bistoury, its back next the eye, between the commissure and the margin of the orbit, and onwards under the skin for the extent of half an inch or more towards the temple, when the point is made to transfix the skin. By now pushing the knife on, it cuts itself out, and the division of the commissure is accomplished.

Second steps, comprising the extirpation.—Whilst the assistants keep the eyelids much drawn asunder, the surgeon, holding the scalpel in one hand, with the other rolls the eyeball upwards without drawing it forth of the orbit, in order to expose fully the lower conjunctival fold. This he freely divides from one angle to the other by plunging the scalpel into the orbit at one angle, and carrying it along the margin of the orbit with a sawing motion to the other angle. In this step the origin of the inferior oblique muscle should be cut.

Having withdrawn the scalpel, the surgeon next rolls the eyeball downwards, and cuts in the same way through the upper conjunctival fold, carrying the knife along the upper margin of the orbit from one angle to the other. In this step the superior oblique muscle should be cut.

The incisions are now made to join each other at the angles, and by rolling the eyeball first to the one side, then to the other, what tags still exist are to be divided.

The optic nerve, with the recti muscles, is next to be divided. For this purpose the curved scissors are introduced into the orbit, along, and with their convexity towards the upper and inner wall, whilst the eyeball is kept rolled downwards and outwards. Being now opened, they are pushed deeper until they include between their blades the optic nerve, surrounded by the muscles close to the optic foramen, when they are to be closed, and these parts cut through. After this the eyeball is readily drawn forth of the orbit, the scissors being used to divide any remaining tags.

The orbit is now to be explored with the finger, and if any suspicious structure be discovered, it is to be removed. If the lacrymal gland be at all indurated and enlarged, it ought to be seized with a hook, dragged from its fossa, and, along with its surrounding cellular tissue, removed with the scissors. If not diseased, it may be left.

Dressing.—The bleeding usually abates of itself, or on the application of cold water; if not, pressure with a plug of lint is to be made. The orbit is now to be lightly filled with charpie, the divided external commissure united by a stitch or two, and the whole covered with a piece of spread linen with holes cut in it, and a light compress and roller. [The charpie dressing is better omitted, as it is not needed, and may prove a source of irritation.]

If the eyelids are so involved in the disease of the eyeball as to require to be extirpated also, an incision is to be made through the sound skin all round the margin of the orbit, and the eyelid detached from the margin of the orbit and reflected towards the eyeball. The eyeball, including the eyelids, is then to be secured

with either the tenaculum or ligature, and the extirpation proceeded with as above. In this case it will be observed that there is no cutting of the conjunctival folds, all the conjunctiva being removed along with the eyelids and the eyeball.

After-treatment and healing of the wound.—Although extirpation of the eyeball is a severe, and without chloroform a very painful operation, it is in general not attended by any considerable accident, even in weakly patients; and recovery in general readily takes place under the treatment usual after great operations. But unfortunately the disease, on account of which the operation is most commonly undertaken, is very apt to break out again in the adjoining or some other parts. In this point of view, extirpation of the eyeball is very far from being a successful operation. Indeed, in many of the cases in which it used to be had recourse to, viz., medullary fungus and cancer, it is now generally refrained from. And as to the other cases, it is rare that there is any pressing necessity for it.

Inflammation must be met actively, as it is apt to extend to the membranes of the brain and prove fatal. When the charpie has become loosened by the occurrence of suppuration, it is to be removed, and the orbit washed gently out with tepid water and again lightly filled with charpie. As granulation goes on, less and less charpie is to be introduced at the subsequent dressings [p. 229].

Section II.—Cataract.

GENERA AND SPECIES OF CATARACT.

Cataract consists in a greater or less opacity of the crystalline body, whereby the rays of light are, in a proportionate degree, intercepted on their way to the retina, and vision is thus impaired or reduced to a mere perception of light and shade.

The opacity may be seated in the lens itself, or in its capsule, or in both lens and capsule at the same time. Different kinds of cataract are accordingly recognized, viz., *lenticular, capsular,* and *capsulo-lenticular.*

The distinctions of these different kinds of cataract is a point of no small importance, for on it depends a correct conception of the rise and progress of the disease, and, especially, the discrimination of the operative procedure best adapted to effect a restoration of vision in a given case.

Cataract, as above defined, is sometimes distinguished by the

epithet *true*, in contradistinction to what has been called *false cataract*, which consists in opaque deposits of lymph, pus, blood, &c., on the anterior capsule, and obstructing the pupil—the consequence commonly of anterior internal inflammation of the eye. False, however, may be combined with certain kinds of true cataract—anterior capsular or capsulo-lenticular. As examples of such a combination may be mentioned, *trabecular*, some forms of *pyramidal*, and *pigmentous cataract;* the first two so named from the deposit of lymph being, in the one, of the form of a bar crossing the front of the capsule, and in the other, of that of a pyramid; the last from fragments of uvea adhering to the anterior capsule.

LENTICULAR CATARACT.

This constitutes the typical example of cataract; and whilst it is the most common kind, it is fortunately that which admits of the most ready and perfect cure.

There are certain appearances which lenticular cataract may present, dependent simply on the natural structure of the lens, rendered visible by its having become opaque, and which may therefore be studied in a healthy lens, removed from the eye after death, and rendered opaque by reagents. These appearances deserve to be noted before proceeding to inquire into the objective characters of the different species of lenticular cataract.

1st. *The glistening appearance like tendon, or mother-of-pearl.*—This is owing, as in the case of tendon, or mother-of-pearl, to the mode in which the light is reflected by the peculiar surface of the opaque fibrous structure.

2d. The appearance of a star with three radii, extending from the centre towards the circumference of the lens, one upwards and a little outwards, one downwards and inwards, the third downwards and outwards, less opaque than the rest of the lens, and without the glistering appearance. This is owing to a substance, different from that of the rest of the lens, intervening between the anterior ends of the fibres, thus:

Fig. 20.

This substance becoming distended, by the imbibition of fluid apparently, the stellate appearance is rendered more evident, thus:

The character by which it is of most importance to distinguish species of lenticular cataract, is consistence; for this has reference to the kind of operation to be undertaken for their cure. According to their consistence, lenticular cataracts are divided into *hard*, *soft*, and *fluid*.

Fig. 21.

But seeing that their consistence cannot be ascertained in a direct

manner before operation, the period of life of the patient, the color and general aspect of the opacity, and the size of the cataractous lens, inasmuch as they stand in pretty close relation with the consistence, and are ascertainable, constitute points to which the surgeon's attention should be particularly directed, with a view to the diagnosis of consistence.

The size of the cataractous lens is judged of by the distance of its anterior surface behind the iris. When the distance is considerable, the cataract is inferred to be small; when, on the contrary, the anterior surface of the cataract is in contact with the iris, and still more if it appears to press the iris forward, the cataract is inferred to be large. The distance behind the iris of the anterior surface of the cataractous lens is judged of by the breadth of the shadow thrown upon that part of it seen through the pupil by the pupillary margin of the iris, on the side next the light, thus. The distance is in proportion to the breadth of the shadow. When the anterior surface of the cataract is in contact with the posterior surface of the iris, there is of course no shadow.

Fig. 22.

Diagnosis of consistence.—Generally speaking, hard cataracts are met with in persons advanced in life, have a color which is a mixture of gray and amber, and are of a size not exceeding that of the healthy lens. Soft cataracts, on the contrary, occur in young persons, have a gray or milk-and-water color, and are of a size at least equal to, but often exceeding, the natural size of the healthy lens. Fluid cataracts are characterized by their whiteness, especially at the most depending part, and are usually moreover complicated with capsular opacity; the case thus being one of capsulo-lenticular cataract. [Unfortunately these tests cannot be much relied upon. We have repeatedly known experienced operators to be mistaken. See Lawrence, Am. ed. and Haynes Walton, Am. ed.]

Diagnosis between lenticular and capsular cataract, and between lenticular and capsulo-lenticular cataract.—The opacity of lenticular cataract is some tint of gray, and if streaked, uniformly so, from centre to circumference; in capsular cataract, on the contrary, the opacity is white and irregularly streaked or speckled; whilst in capsulo-lenticular cataract the opacity is a variable combination of lenticular and capsular opacity, as will be more particularly detailed under the head of capsulo-lenticular cataract.

Hard or common lenticular cataract of old people.

Between fifty and seventy is the age of the majority of persons who present themselves with this form of cataract. There are a few younger than fifty, because the complaint is of rare occurrence below

that age. There are also comparatively few older than seventy, not, however, because the disease is of less frequency above that age, for the contrary is the case, but because there are then fewer people living.

The *consistence* of the lens is greater than natural, especially as regards the nucleus. The *size*, not greater. The *color*, a mixture of gray and amber—the amber color predominating in the middle, where the opacity appears greatest. The cause of this peculiarity of coloring is, that the central nucleus of the lens is the seat of the amber color, and this sometimes without actual opacity, whilst the superficial part of the lens is the seat of the gray opacity. Sometimes there is nuclear, with little superficial opacity; sometimes superficial, with little nuclear. Generally the nuclear appears first, and the superficial is gradually superadded.

The superficial gray opacity, which may have more or less of the glistening appearance on the surface above described (p. 231), sometimes presents itself in the form of streaks, *converging* from the circumference of the lens, where they are broad, toward the centre, where they become narrow. These streaks are fasciculi of fibres, more opaque than the rest. When the posterior superficial strata are thus affected, the opacity appears deep-seated and concave.

In some cases we can observe this opacity of the superficial strata, both anterior and posterior, together with nuclear opacity, whilst the intermediate part of the lens is still pretty clear.

Lenticular cataracts occur, in which, while the central nucleus is as hard as in hard cataracts, just described, the peripheral strata are softer—softer even than in the healthy state of the lens. They also belong to advanced life, and indeed appear to be an advanced stage of the preceding form. The peripheral strata of the lens, at the same time that they are softer, are more opaque. In consequence of this, the brown-yellow, or amber color of the hard central part of the lens is not seen, or but indistinctly, the general color of the cataract being that of the more opaque superficial strata, viz., whitish-gray.

Sometimes hard cataracts are of a dark brown color, like mahogany; such are called *black cataracts.*

Subjective symptoms.—When the cataract is pretty fully formed everything right before the patient generally appears to him as if obscured by a thick cloud or gauze, but objects placed to one side, or above or below, he may still perceive less indistinctly. In bright light, vision is still more indistinct; in moderate dull light it is less so. The opposite of all this, however, sometimes occurs, viz., that the patient sees right before him better than to one side, and in a strong as well as in a dull light—sometimes better. Lastly, objects may not be seen at all, but vision may be reduced to a mere perception of light and shade.

The peculiarities in the state of vision now enumerated present themselves according as the opacity is greater or less in the centre than at the circumference of the lens, or as it is equally great in the centre and at the circumference.

In the first and more common case, *i. e.* when the opacity is greater in the centre than at the circumference of the lens, the rays of light from objects right in front of the eye are less freely admitted or are altogether intercepted by the more opaque central part of the lens; whilst the rays of light from objects situated to one side are more freely admitted through its less opaque circumferential part. In bright light, the pupil being contracted, the less opaque circumferential part of the lens is covered, and only the more opaque central part of the lens presented to the rays of light, so that even the vision of objects placed sideways is interrupted; whereas in dull light, the pupil being dilated, the less opaque circumferential part of the lens is, to a considerable degree, uncovered, and more free entrance of light thus permitted. When the pupil is under the influence of belladonna, vision is still more decidedly improved, as the dilatation produced by belladonna is greater than that which takes place in dull light.

In the second and rarer case, *i. e.* when the opacity is less in the centre than at the circumference, the rays of light from objects right in front of the eye are more freely admitted by the less opaque central part; whilst the rays of light from objects to one side are less freely admitted, or are altogether intercepted by the more opaque circumferential part of the lens. In bright light, though the pupil is contracted, the less opaque central part of the lens is still uncovered for the passage of the rays of light, and hence vision is uninfluenced.

When the opacity involves equally the central and circumferential part of the lens, vision is nearly equally defective, whether during a dilated or a contracted state of the pupil.

Objects, when they are still to be perceived, sometimes appear to the cataractous patient distorted and multiplied.

Objective symptoms.—The general bearing of the cataractous patient, the expression of his features, and the movements of the eyeball, have been above noticed (p. 38). By keeping his head bent forwards, his eyebrow knit and depressed, his eyelids half closed, and by looking at objects sideways, he appears as if intolerant of light. He does, indeed, by these means, seek to shade the eyes, but not because he cannot bear the light, but because he in general finds that when his eyes are shaded he sees better (p. 233).

As regards the appearance of the eye:—The clear black of the pupil is wanting, and in its stead there is an opaque appearance, presenting, in various degrees of intensity, combination, and extent the characters above described (pp. 232, 233). On examining

carefully the opaque appearance, especially by looking into the eye sideways, it is seen in the situation of the crystalline body. On making a catoptrical examination of the eye (p. 60), it is found that the inverted image is no longer seen, and that the deep erect one, if still seen, is very indistinct.

That the opacity is seated in the lens, may generally be determined by a practised surgeon without dilating the pupil by belladonna, but of course no formal opinion should be pronounced by beginners of the exact nature of the case until an examination has been made whilst the pupil is under the influence of belladonna.

The pupillary margin of the iris, which is naturally darker than the rest of that membrane, is in cataract brought by contrast more distinctly into view than usual, and looks like a dark ring encircling the pupil.

The form and motions of the pupil are natural, unless the cataract be so large as to press upon the iris, which, however, is not usually the case in hard cataract, or unless the case be complicated with morbid adhesions, amaurosis, &c.

Rise and progress.—The dimness of vision, and objective opacity, in general, begin in a very marked manner, and increase slowly for perhaps months or years, until they have attained the degree above described. Usually one eye is affected first, and by-and-by the other. In rarer cases both eyes become affected at the same time.

Nature and causes.—Lenticular cataract consists in a marasmus and opacity of the proper substance of the lens; the fibres are shrivelled and dry-looking when examined under the microscope, and instead of a homogeneous interfibrous substance there is a granular deposit. It may be looked upon in some degree as a natural change with the advance of life; but there are circumstances which especially predispose to the complaint, such as hereditary tendency, habitual exposure to strong fires, &c.[1]

Diagnosis.—Glaucoma with amaurosis is the disease with which the lenticular cataract of old people is most likely to be confounded. It is, however, to be observed, that a case of this form of cataract, even in its incipient stage, is less likely to be mistaken for a case of glaucoma with amaurosis than a case of glaucoma with amaurosis is for one of cataract. The following diagnostical table displays the principal points of difference between cataract on the one hand, and glaucoma with amaurosis on the other.

Objective symptoms.

CATARACT.	GLAUCOMA WITH AMAUROSIS.
The eyeball presents to the touch the natural degree of firmness.	The eyeball is preternaturally hard to the touch.
The opacity is readily recognized	The opacity appears deep-seated,

[1] [See Lawrence, on the Diseases of the Eye, Am. ed., 1854, p. 686, for a full and instructive account of the pathology of lenticular cataract, by Dr. Hays.]

CATARACT.

to be well-defined, and distinctly seated in the lens, and not to change its place with the direction of the light. When the pupil is dilated by belladonna, the cataract is still more distinctly and extensively seen.

The pupil in its movements always quite natural. Readily and quickly dilates under the influence of belladonna.

Even in an early stage, the inverted image is obscure, or obliterated, and the deep erect one very indistinct.

The inverted image, long before the cataract is fully formed, is not produced, or but indistinctly, whether the candle be held opposite the central or the circumferential part of the lens, owing to the circumstance, that it is the superficial strata of the lens which are first affected, and which of course prevent the distinct formation of the inverted image, as well by the middle as by the circumferential part of the lens.

Subjective symptoms.

CATARACT.

Vision in general diminishes slowly; in rare cases, however, quickly. No photopsy, but muscæ volitantes sometimes very evident for the reason above indicated (p. 65).

In general quite unattended by any constitutional disturbance. No internal inflammation nor pain.

Objects situated sideways more distinctly seen in general; inwards, outwards, upwards, downwards, indifferently.

GLAUCOMA WITH AMAUROSIS.

but where it is seated one cannot, by merely looking into the eye, say exactly, especially as it changes place according to the direction in which light is admitted to the eye, appearing always on the opposite side. It is not seen more distinctly when the pupil is dilated.

The pupil is more or less dilated, and if not quite immovable, its movements are limited and slow. Yields slowly and imperfectly to the influence of belladonna, if not already quite dilated.

Glaucoma only when much advanced, obliterates the inverted image, while in all its stages, it renders the deep erect one more evident than it is in the healthy eye.

In glaucoma at a middle stage, the inverted image is pretty distinct when formed near the edge of the crystalline; but if the candle be brought in front of the eye, the inverted image is less distinct, and in some cases is altogether extinguished. This extinction of the inverted image, when the candle is brought in front of the eye, and not otherwise, is owing to a loss of transparency in the kernel of the lens, while the superficial strata are still transparent.

GLAUCOMA WITH AMAUROSIS.

Diminution of vision often sudden; sometimes, however, slow and gradual, fiery and colored spectra before the eyes, are of common occurrence.

Generally accompanied by constitutional derangement. Often symptoms of internal congestion, or actual posterior internal inflammation with supra-orbital or temporal pain.

Objects situated to some *one* side, not any side indifferently, often more distinctly seen, as some *one* part of the retina may be less affected than the rest—inside or outside only, above only, or below only.

CATARACT.	GLAUCOMA WITH AMAUROSIS.
Vision better in dull light. The opposite of this occurs, but rarely, when the circumference of the lens is more opaque.	Vision worse in dull light. The opposite of this, however, sometimes occurs in the erethitic form.
The flame of a candle or lamp appears expanded and diffused, as it is seen when we look at it through obscured glass.	The flame of a candle or lamp appears lost, but its place surrounded by spreading rays.
In general, the vision is not liable to be better some days, worse others.	Often vision is better one day, worse another.
Diminution of vision is in proportion to the opacity of the lens.	Diminution of vision much greater than the *appearance* of opacity of the lens would account for.
Perception of light at least never lost, even when the opacity is very dense.	All perception of light may be lost, and yet the appearance of opacity may not be much greater. Complete cataractous opacity may, however, supervene.

Prognosis and treatment.—When once begun to form, it may be prognosticated that the opacity will go on to increase until all useful vision is prevented in the eye. And it may also be prognosticated, that the other eye, if not already, will likewise become affected. How quick or how slow the progress to loss of useful vision may be, cannot be prognosticated—it may be months, or it may be years.

Restoration of vision can be effected only by an operation, by which the opaque lens shall be removed from its situation to below the level of the pupil (*the operation of displacement*), or extracted from the eye altogether (*the operation of extraction*). [In many cases the lens may be divided and removed by absorption, p. 238.]

Soft or common lenticular cataract of young people.

The cataract is of the same consistence as that which is natural to the lens, or softer, and of a grayish-white, or milk and water opacity. The superficial strata of the lens are commonly the first affected. It presents, in the earlier stages of its opacity, the glistening tendinous aspect and stellate appearance above described; in short, the soft cataractous lens at first very closely resembles a healthy lens, rendered opaque and swollen by the action of reagents. But by-and-by it may come to have less of the appearance of the original structure. The lens is generally of the natural size, but is sometimes larger.

Subjective symptoms.—Vision is diminished in proportion to the opacity, in a manner analogous to what is above described to be the case in hard cataract.

Objective symptoms.—These are, on the whole, much the same as those of hard cataract above described, with the exception of such

differences as are produced by the differences in color, general aspect of the opacity, and size of the cataractous lens.

The iris and pupil may be natural, but according to the size of the lens, so will be its closeness to the iris and the breadth of the shadow. If, as is often the case, it is so large as to press on the iris, the motions of the pupil are impeded, and the shadow is altogether wanting.

Causes.—The occurrence of opacity of the lens in young persons, is very much rarer than in old persons. It is often met with as the result of injury. In children affected with lenticular cataract, we are sometimes told that the opacity made its appearance after convulsions. In other cases it cannot be traced to any cause.

Diagnosis.—There is no likelihood of this form of lenticular cataract being confounded with glaucoma, as the latter disease does not occur except in old persons. It is to be remembered, however, that this form of cataract is not unfrequently complicated with amaurosis. Soft lenticular cataract being whiter than hard, is less readily distinguished from capsular cataract.

Prognosis and treatment.—What is above said on these heads (p. 237), in regard to hard cataract, is in general applicable here, except that the kind of operation best adapted for the removal of the opaque lens, is that by *division*, in order to its solution and absorption. [This operation is no less efficient in many hard cataracts.]

II.—CAPSULAR CATARACT.

The anterior and posterior walls of the capsule may be separately affected with opacity. Hence are recognized anterior capsular cataract, and posterior capsular cataract. Opacity of the lens is apt to supervene, so that the case merges into capsulo-lenticular cataract.

Anterior capsular cataract.

The opacity in anterior capsular cataract has more analogy with opacity of the cornea than opacity of the lens, being owing to opaque exudation on the outer or inner surface of the capsule. It is usually dead white, and either implicates the whole anterior wall of the capsule, or perhaps, one half, or occurs in abruptly defined patches, spots, or streaks, quite irregular both in form and disposition, except in the case of *central capsular cataract*, in which the opacity occurs in the form of a single elevated opaque spot, seated in the centre of the capsule. This elevated opaque spot is sometimes of a pyramidal shape, its apex projecting towards the pupil.

According to the differences in the general aspect of the anterior capsular cataract, produced by the differences in the disposition of the opacities, such names as the following have been given to the cataract:—*cataracta capsularis, anterior totalis, dimidiata, centralis, punctata, marmoracea, striata, &c.*

Motions of the pupil.—The motions of the pupil may be natural, but very often they are impeded by adhesions between the pupillary margin of the iris and the capsule of the lens.

Subjective symptoms.—According to the situation and extent of the specks, so the loss of sight may be greater or less than in lenticular cataract. Complications often exist which may disturb the vision more than the mere capsular opacity.

Causes.—Anterior capsular cataract appears generally to be the result of inflammation of the eye, of ophthalmia neonatorum, or scrofulous ophthalmia, for example, more frequently than of iritis. Often it is congenital.

The *diagnosis* of anterior capsular cataract is founded principally on the superficial seat and whiteness of the opacity, and its speckled disposition.

Prognosis and treatment.—Anterior capsular cataract is, like opacity of the cornea, not prone to extend, the inflammation which orginally gave rise to it having ceased, and it may continue for many years, or for life, without the supervention of lenticular opacity. Not unfrequently so much vision is still preserved that no interference in the way of operation is required. Any operation that may be undertaken, must be the same as for capsulo-lenticular cataract, for the capsule cannot be removed without sacrificing the lens.

Posterior capsular cataract.

Of simple uncombined opacity of the posterior wall of the capsule little is known. Opacity of the posterior strata of the lens (p. 232), has been sometimes mistaken for it.

III.—CAPSULO-LENTICULAR CATARACT.

In capsulo-lenticular cataract, the opacity may be partial or complete. It may be confined to a small spot on the middle of the anterior capsule, and of the lens, the rest of the body being healthy; or the opacity may be to a greater extent, and the lens hard, soft, or in a more or less fluid state. The opacity of the anterior capsule, which varies in degree as in simple anterior capsular cataract, may be combined with thickening of it.

Sensibility to light is occasionally very feeble in capsulo-lenticular cataract, owing in some cases to the density of the opacity, in others to the presence of amaurosis. Cataract supervening to amaurosis, and especially to traumatic amaurosis, is frequently cap-

sulo-lenticular. The cataract is slow in its progress under such circumstances. At length the vitreous humor dissolves, and the iris and cataract become tremulous.

According to the differences above enumerated, different species of capsulo-lenticular cataract are recognized.

Central capsulo-lenticular cataract.

This seems to belong to the same head as central capsular cataract, from which it differs merely in presenting a circumscribed opacity of the lens at the place corresponding to the opacity of the capsule. Both species occur congenitally, or make their appearance shortly after birth—often after ophthalmia neonatorum. The lenticular opacity may be broader, but is not in general so dense as the capsular. Central cataract is rarely capsular merely, it is in general capsulo-lenticular. It often coexists with congenital defects. I have met with it along with night-blindness.

The effect of central capsulo-lenticular cataract on vision is short-sightedness.

Prognosis and treatment.—No operation is called for. If the pupil is not habitually dilated so as to expose the clear part of the crystalline for the passage of light, the drops of belladonna or atropia are to be used for that purpose (p. 71). The lenticular opacity is apt eventually to extend, and to render an operation necessary.

General capsulo-lenticular cataract.

The appearances are those principally of anterior capsular cataract, when the opacity of the anterior capsule is complete. When the opacity is incomplete, the opacity of the lens is seen through the transparent places. The lens may be hard, soft, or fluid.

When dissolved, the lens forms an opaque white or yellowish fluid, which distends the cataractous capsule. In some cases, the opacity and fluidity of the lens precede the opacity of the capsule; while in other cases the diseased state of the capsule appears to lead to the disorganization and dissolution of the lens.

What has been called Morgagnian cataract appears to be an early stage of fluid cataract, and to consist in softening and opacity of the exterior part of the lens, with perhaps absorption by endosmose of aqueous humor into the capsule, determined by the diseased state of the lens, similar to what takes place after death, and which is the true source of what is called the Morgagnian fluid. When the vitreous body is at the same time dissolved, the cataract presents tremulous movements with every turn of the eye or head (*cataracta tremulans vel natatalis*). Being no longer fixed, it falls down below the pupil, and is apt to pass through it into the anterior chamber. Tremulous cataract is almost always complicated

with amaurosis, and is generally the result of a blow on the eye or its neighborhood.

Siliquose cataract.

This results from the more or less complete absorption of the lens, and collapse and thickening of the opaque capsule. It is of a grayish-yellow color, and softish, easily broken up, in young persons; whiter, firmer, and tougher in grown-up persons. It is sometimes so much shrunk in diameter, that when the pupil is dilated, the *zonula lucida* appears around it, and radiating white bands are seen extending from it to the ciliary body (*cataracta cum zonula*). It is also so much shrunk in thickness, that it is evidently at a considerable distance behind the iris, which may in consequence be inclined backwards.

Of course the movements of the pupil cannot be influenced by the cataract, but they may be so by concomitant complications.

THE OPERATIONS FOR CATARACT.

The restoration of vision in cataract cannot be effected by any means short of operation. The different operations for this purpose have for their common object the removal of the opaque body from behind the pupil, so that the rays of light may be again allowed to pass on to the retina. This object is sought to be effected in one or other of three different ways, according to the circumstances of the case, viz.—1st. By at once extracting the cataract from the eye. 2d. By simply displacing it to below the level of the pupil. 3d. By lacerating the capsule and dividing the lens, in order that the latter, being exposed to the action of the aqueous humor, may be gradually dissolved and absorbed, and thus eventually removed from the eye. Of these three different ways, again, there are different modifications.

General observations and questions regarding the operations for cataract.

Prognosis of the operations for cataract in general.—The success of operations for cataract depends very much on the kind of cataract, the age of the patient, and the local and constitutional complications; but, as a general estimate, it may be admitted with Dr. Mackenzie, that three-fourths of patients operated on recover useful vision, and two-thirds excellent vision, when such cases only as are fitted for operation are operated on; when the mode of operating is adapted to the particular case; when the operation is well performed, and the after treatment skilfully conducted. [The experience of Wills Hospital is that at least four-fifths recover good vision. See note by Dr. Littell to p. 459 of Haynes Walton's Operat. Ophthalm. Surgery, Am. Ed.]

Kind of cataract.—The prognosis in lenticular cataract is much more favorable than in capsular. As to hard and soft lenticular cataract, the prognosis in them merges into that of extraction and division.

Age of the patient.—The prognosis is better in young children and old persons than in persons in the prime of life; but this is mainly because it is in early life and old age that the cataracts most favorable for operation occur. [It is, probably, the most discouraging in extreme old age. This, however, is in these cases as in many others, a relative condition, not dependent on years alone; since patients over eighty have done perfectly well.] The general complications connected with age which are unfavorable to the success of operations for cataract, are, in early life, scrofula, and in advanced life, gout.

Complications of cataract.—Before an operation for cataract is determined on, it is necessary to examine not only the state of the eye in other respects, but the state of the system in general, lest complications should exist which might interfere with the success of the operation. This they might do in two ways, viz., either by interfering with its success as an operation simply, or the operation as an operation being successful, by interfering with the accomplishment of its ultimate object of restoring vision.

The complications which might interfere with the success of the operation as an operation, *i. e.* the successful removal of the cataract, without subsequent injury to the eye from undue inflammation or the like, may be either local, such as entropium, ectropium, trichiasis, ophthalmia tarsi, chronic ophthalmia, or the like, or constitutional, such as disposition to erysipelatous and catarrhal inflammations, scrofula, syphilis, gout, scurvy, chronic diseases of the skin, habitual ulcers of the legs, nervous complaints.

In regard to local complications it is to be observed, that there are certain morbid states of the eye, which, though they might seriously interfere with the success of an operation as an operation, performed in one way, would be little or no impediment to the success of an operation performed in another way; thus, whilst synechia anterior, contracted pupil, or dissolution of the vitreous body, would be incompatible with the success of the operation of extraction, they would offer little or no impediment to the success of displacement or division.

The operation as an operation being successful, the complications which might interfere with the accomplishment of its ultimate object of restoring vision, are local, such as defective sensibility of the retina, extensive opacity of the cornea.

Of the different kinds of complications of cataract above enumerated, most admit of cure, or of such palliation as is calculated

to remove or diminish the risk of their interfering to prevent the success of an operation. Defective sensibility, or total insensibility of the retina, however, in general, admits of no cure, and is therefore of course a complication rendering all operative interference fruitless.

The *diagnosis* of the various complications of cataract above referred to, is either quite evident, or not obscured by the presence of the cataract; but it is different in the case of complication of cataract with defective sensibility of the retina; for without a careful consideration of all the circumstances of the case, including an inquiry whether, at the commencement, the loss of vision was accompanied by any symptoms of posterior internal ophthalmia (p. 167), and an examination of the eye, with the pupil under the influence of belladonna, the defect of vision might be attributed solely to cataract, especially as ready perception of light and shade still remains. In the case of total insensibility of the retina, the diagnosis is in general easy, seeing that cataract never produces complete blindness (p. 234).

When one eye only is affected with cataract, and the vision of the other good, should an operation be performed?—Under such circumstances, the practitioner will not recommend recourse to an operation, and indeed the patient is not likely to desire it, except, as is sometimes the case with young persons, generally females, when the cataract is white and very evident, for the sake of getting rid of the deformity.

When in one eye useful vision is lost, and in the other, vision has become misty from cataract should an operation be performed on the former?—The usual advice is to wait until useful vision is lost in the latter also; but it is better to operate at once on the blind eye, though the determination of the point may be left to the convenience of the patient.

When in an elderly person double lenticular cataract has become so far developed as to interfere with useful vision, when should an operation be had recourse to?—If extraction is to be performed, operate as soon as possible, for there is more chance of the vitreous body being sound than at a later period; if, on the contrary, displacement is to be performed, the operation may be deferred until the cataracts be more developed.

When cataract is fully formed in both eyes, may both be operated on at the same time?—As a general rule, the answer is in the negative, if extraction is to be performed; in the affirmative, if displacement or division.

In cases of congenital cataract, at what age should the operation be performed?—It ought to be performed in infancy; and if possible, before teething commences; if not, soon after teething is completed.

Preparation of the patient for undergoing an operation for cataract.—If the case be free from local or constitutional complications, the patient requires no other preparation than a few days rest of mind and body, some attention to diet, and to the state of the bowels. If, on the contrary, any such complication exist, he ought, before the operation is undertaken, to be subjected to such treatment as is adapted either to remove them altogether, or to palliate them so far as to remove or diminish the risk of their interfering to prevent the success of the operation. The previous habits of the patient as to diet, the use of strong drinks, smoking, &c., should be carefully considered.

The treatment of the morbid states of the eye, which may complicate cataract, is discussed under their proper heads. In regard to the treatment of the various constitutional complications, it would be out of place here to enter into detail. It is proper, however, to observe, that in some cases, the abstraction of blood may be necessary, besides restriction of diet, even to abstinence from all strong drink, and animal food too, though in these respects care should be taken not to interfere too violently with confirmed habits. For the regulation of the bowels repeated purges may be required. In other cases, strengthening diet, and tonic and even stimulating treatment may be called for.

It need scarcely be remarked, that if the patient is subject to gout, rheumatism, or erysipelas, the operation should be carefully avoided, when there is reason to fear an attack is impending. Shortly after an attack, is the occasion which should be chosen. In any case, the operation is not to be undertaken while the patient has a foul tongue. [Nor ought he to have a full stomach, especially if anæsthesia is to be employed.]

On the morning of the operation, if there is no natural evacuation, a clyster should be given to procure one.

The only special preparation of the eye for the operation is the dilatation of the pupil, by means of the softened extract of belladonna, smeared on the eyebrows and eyelids, two or three hours before, or what is more convenient, the atropia solution dropped into the eye.

Seasons of the year best adapted for operations for cataract.—The operations for cataract may be performed during mild and steady weather at any season; and such weather most usually occurs from March to the end of October. [The best time of day is noon, when the sun gives the best light.]

Position of the patient, assistants, and operator.—The patient may either sit on a chair, or he may lie extended on a sofa or table with a pillow under his head. In infants, great advantage is obtained by bringing them under the influence of chloroform [or sulphuric

ether ; which we decidedly prefer in most cases, using if desirable, sometimes, a small proportion of chloroform along with it], otherwise they are best secured by wrapping them in a shawl, to confine their arms and hands, and laying them on their backs on a table. In very timid adults, also, chloroform [or ether] may be occasionally resorted to, at least in operations with the needle, the vomiting which sometimes supervenes being an objection of some weight to its employment in extraction.

When the patient sits, the operator usually stands, or, if he sits, it is on a high chair, before the patient, whilst an assistant stands behind to support his head, and to take charge of the upper eyelid. The patient's head should be held with the face looking somewhat upwards; and in order to secure it in this position, the assistant supports it against his breast, and holds the chin by one hand, whilst the other—the right if the right eye, the left if the left eye is the subject of operation—rests on the forehead; with the latter hand the assistant secures the upper eyelid. The operator takes charge of the lower eyelid, and for this purpose he uses the forefinger, the middle finger being applied to the inner corner, ready to prevent the rolling inwards of the eyeball, the ring finger is bent to be out of the way, the little finger rests on the patient's opposite cheek; with the right hand the operator holds the instrument, if it is the left eye which is to be operated on, and *vice versa*. When the patient lies extended on a sofa or table, the operator stands at his head; in which case, with one hand resting on the forehead, he secures the upper eyelid, whilst with the other he holds the instrument.

If the operator is not ambidexter, he, when the patient sits, can conveniently operate only on the left eye. When the patient lies extended on a sofa or table, the operator stands behind the head, and takes charge of the upper eyelid, if it is the right eye which is to be operated on. But if the left, then he must stand by the side of the patient; in this case, the assistant stands at the head, and secures the upper eyelid; the operator himself depressing the lower. [The recumbent position on the back is probably the best.]

In operating on the eye, it is of the greatest moment to have good light. A window directed to the north should, if possible, be chosen. If there be more than one window in the room, the others should have the curtains drawn over them. In regard to the position of the patient to the light, it should be such that neither the operator's body nor his hand be interposed between the eye and the light during the operation.

Opening and securing of the eyelids.—The patient, assistant, and operator being in their places, the next business is to open and secure the eyelids. The proper securing of the upper eyelid is a

most important point; it is effected by applying the points of two fingers, the fore and middle, or the middle and ring finger, according to circumstances, against the broad border of the tarsus, the eyelashes being smoothly extended between the eyelids and the surface of the fingers, and gently raising the eyelid, by sliding its firm part back under the margin of the orbit, until the fingers come to press against that margin. The upper eyelid may thus be completely secured without any great force, and without the slightest pressure on the eyeball, without the eyeball even being touched.

The lower eyelid is secured in a similar manner, and still more easily, with the forefinger, whilst the middle finger is applied over the caruncle. Fig. 23.

Fig. 23.

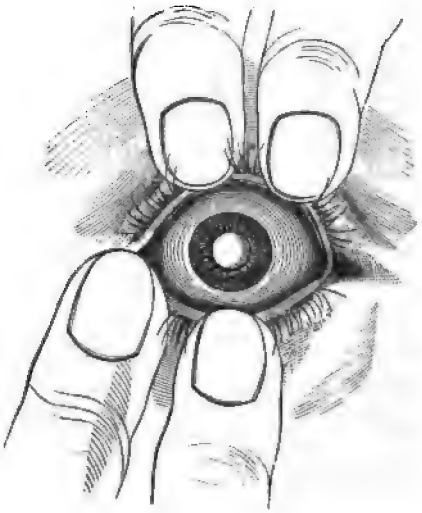

It is seldom necessary to employ a speculum for securing the upper eyelid.

When the eyelids are held apart unskilfully, they are apt to become everted, while folds of the conjunctiva are thrust out between them by the action of the orbicularis muscle, so that the front of the eyeball is almost buried, and the operation consequently impeded.

A compress of charpie is laid over the closed lids of the eye not operated on, and secured by a roller. If, however, the patient has complete command over himself, the eye should be left uncovered, that he may keep his gaze steadily fixed on some point, and thus properly direct and steady the eye to be operated on.

EXTRACTION OF THE CATARACT.

The kind of cataract, for the cure of which the operation of extraction is most commonly undertaken, is the common hard lenticular cataract of old persons.

The extraction may be effected through an incision, either in the cornea, or in the sclerotica. Extraction through an incision in the cornea, is the operation commonly practised; extraction through a sclerotic incsion not having been found so successful. Siliquose cataract and shreds of opaque capsule are, however, sometimes extracted through a small opening in the sclerotica.

Extraction of the hard or common lenticular cataract of old persons through the cornea.

Conditions necessary for, or at least favorable to, the successful performance of the operation.—1. Steadiness on the part of the patient during and after the operation. 2. Large palpebral fissure, so that the eyelids may be sufficiently separated to permit the due exposure of the whole front of the eyeball. 3. The eyeball neither much sunk nor very prominent: in the one case the section of the cornea cannot be well made; in the other, the healing of the wound does not proceed so favorably. 4. The cornea, healthy in structure (an *arcus senilis*, p. 55, is no impediment), and of due size and prominence. 5. The iris, free from synechia, and not inclined towards the cornea, so that the anterior chamber may be of good width. 6. The pupil natural, freely contracting and dilating according to the degree of light.

Conditions unfavorable to, or wholly forbidding, the performance of the operation.—Unsteadiness on the part of the patient; chronic cough; difficulty of breathing; very overhanging superior orbital margin and eyebrows; narrow palpebral fissure; very sunk or very prominent eyeball; the cornea unhealthy in structure, small and flat; the anterior chamber consequently small; synechia; small pupil, and not widely dilatable, even by belladonna; or, and above all, a dissolved state of the vitreous body and its connections.

When a dissolved state of the vitreous body exists, as it often does in old persons, the section of the cornea is perhaps no sooner made than the cataract, along with a greater or less quantity of the vitreous humor, bursts out from the eye; or, the cataract, sinking down behind the iris, a large quantity of vitreous humor alone bursts out. If the dissolution of the vitreous body be great, it will be evacuated wholly or in large quantity, and the eyeball may thus be destroyed, notwithstanding the utmost dexterity, delicacy, coolness, and circumspection on the part of the operator. But how is the existence of this state of the vitreous body ascertained before operation? (See p. 205.)

If during the operation of extraction on one eye, any indications of softening of the vitreous body should be observed, this ought to be a warning against proceeding at once to operate on the other; because, during the second operation, the muscles of the eyes and eyelids are apt to be involuntarily contracted, and the vitreous humor of the eye already operated on squeezed out.

It is to be observed, that in the eye in which the cataract has more lately formed, the vitreous body is less likely to be softened than in the other; so that, supposing it to be determined to operate by extraction on both eyes at the same time, it would be advisable to operate first on that in which the cataract has more recently formed.

Prognosis.—When the case is one of common hard lenticular cataract, and when the other conditions are favorable, the prognosis is good. Recovery of the eye, from the effects of the operation, sometimes takes place in less than three weeks; but, not unfrequently, some degree of external, or even anterior internal inflammation occurs, so that recovery is retarded. In general, convalescence should not be calculated on sooner than from four to six weeks; in some cases dangerous and destructive inflammation occurs, although the case appeared to be in all respects a proper one for operation, and the operation well and successfully performed.

The operation having succeeded as an operation, more perfect vision is in general obtained after extraction than after any other mode of operating.

Instruments and dressing.

A Beer's knife, for making the section of the cornea.[1] (Fig. 27, p. 249).

A set of two pairs of Daviel's scissors (Figs. 35, 36, p. 256,) for enlarging the corneal incision, if necessary, or the knives more commonly used for the purpose. (Figs. 30, 34, pp. 253, 255.)

A bent point for lacerating the capsule. (Fig. 37, p. 257.)

Daviel's curette or spoon. (Fig. 38, p. 258.)

A fine hook (Fig. 39, p. 259), or slender-bladed forceps (Fig. 42, p. 266), for extracting or assisting out the lens, in case of its sinking in the vitreous humor.

Two strips of black court plaster, about an eighth of an inch broad, and long enough to extend from the eyebrow to the cheek, over the eyelids. [The strips of gauze and the collodion, to be applied in the usual way above the eyebrow and to the cheek, will be found a convenient substitute for the ordinary adhesive strips.]

Some small pieces of lint.

[1] The sharpness of the point of the knife is tested by making it pierce very thin leather put on the stretch. If the knife pierces without force, and without making any noise, the point is good.

The operation of extracting a lenticular cataract, through an incision in the cornea, may be viewed as comprehending two principal parts, viz., 1st, the section of the cornea; and 2d, the laceration of the capsule, and extraction of the lens.

Fig. 27.

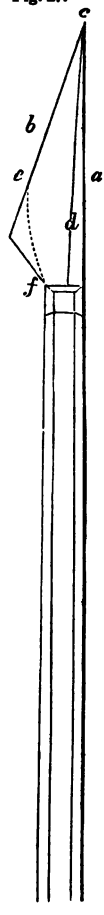

Section of the cornea.—This is usually considered the nicest, if not the most difficult part of the operation. It is made concentric with the margin of the cornea, and in order to be of sufficient size for the escape of the lens, about one-fortieth of an inch from the sclerotica, and to an extent corresponding to rather more than half—to the extent say of nine-sixteenths of the circumference of the cornea. This section may be made in the lower half of the cornea (Fig. 24), or the upper half (Fig. 25), or the outer and lower half (Fig. 26), thus:

Fig. 24.

Fig. 25.

Fig. 26.

The instrument usually employed for making the section of the cornea is Beer's cataract knife, which is represented in the annexed figure.

The back of the blade *a* is straight with the handle, the cutting edge *b* oblique, and forming with the back at the point *c* an angle of about 18° or 19°. For about one-tenth of an inch from the point, the back is cutting, as well as the edge.

The back of the blade generally, though blunt, should be thin, but in a line between the back and the edge, extending from point to heel, the blade is thick, the thickness increasing gradually from point to heel on the one hand, and from the edge and back respectively on the other. The line in the direction of which the thickness is greatest, is indicated by *d*. This conformation imparts the necessary rigidity to the blade, and is farther of use, during the performance of the operation, in filling up the incision as it is made, and thus preventing the premature escape of the aqueous humor, until the section of the cornea is nearly completed, which is a very important condition for its successful performance.

It may be remarked, that the greater breadth of the blade

towards the heel is quite unnecessary for the completion of the section of the cornea, as may be seen in Fig. 28, and is sometimes positively inconvenient during the operation, by coming into contact with the edge of the eyelid. All the part, therefore, comprised between *e* and *f*, Fig. 27, might be advantageously cut away as far as the dotted line.

The handle of the knife should be broad, as much as one-fifth or one-fourth of an inch broad, and flat, the flat sides to correspond to the flat surfaces of the blade.

The mode in which the section of the cornea is made with the knife, which has now been described, is to pierce through the cornea on the temporal side into the anterior chamber, which constitutes the act of *puncturation;* then to push the point of the knife, the flat surfaces of the blade being to and from the operator, through the anterior chamber, across to the nasal side of the cornea, where the point of the knife is again made to pierce through the cornea from the anterior chamber, an act called *counter-puncturation.* By now continuing to push the knife onwards, it, by its in-

Fig. 28.

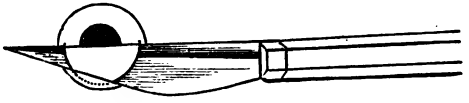

creasing breadth, *cuts itself out* in the direction of the dotted line, Fig. 28, and so the section of the cornea is completed. The section of the cornea thus comprehends three acts, viz., *puncturation, counter-puncturation,* and *cutting out.*

Method of holding the cataract knife.—The handle is to be held not exactly in the middle, but rather nearer the blade; its flat surfaces between the points of the fore and middle fingers on the one hand and the point of the thumb on the other, and the general direction of the handle somewhat at right angles to the thumb. (Fig. 29, p. 251).

By having the handle of the knife broad and flat, and by holding it in the manner just described, it is not liable to roll betwixt the fingers, and the little finger resting on the patient's cheek, all the manœuvres after puncturation can be readily executed by the movements of the fore fingers alone, so that the surfaces of the blade can be kept unerringly parallel to the surface of the iris, and the base of the cornea, during the passage of its point, through the anterior chamber: consequently its edge will have no tendency, either to cut abruptly out from the cornea; or, on the contrary, to be so inclined, as to come upon the sclerotica, and cut out there.

The position of the patient, whose pupils should be dilated by belladonna (p. 244), assistant and surgeon being arranged as above

Fig. 29.

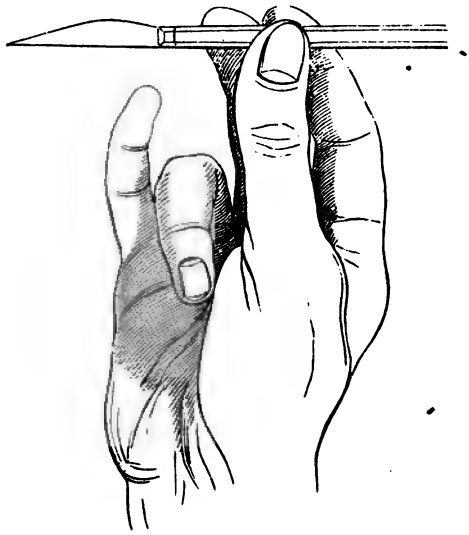

recommended (p. 244, et seq.), the operation is proceeded with as follows:

Section of the cornea, downwards—Puncturation.—The surgeon, holding the cataract knife in the manner above described, and with its back upwards and horizontal, rests the hand by means of the little finger on the patient's cheek, in such a way, that the blade of the knife may be by its corresponding flat surface close in front of the cornea, and with its point as far advanced towards the nose, as it must be, when counter-puncturation is effected.

Things being thus disposed, the surgeon, after touching the cornea, with the flat surface of the blade of the knife, to see whether or not the eye is disposed to start, and warning the patient not to hold his breath when the knife pierces, prepares for puncturation, by first retracting the fingers, holding the knife, and then slightly turning the hand, so that the point of the knife may be brought opposite, and somewhat perpendicular to the point of the cornea, where puncturation is to be made, viz., about one-fortieth of an inch from the temporal margin, and as much above the transverse diameter.

Watching his time then, when the eye is directed steadily forwards, the surgeon by a quick but assured movement, enters the knife at first somewhat perpendicularly to the surface of the cornea,[1] but just as it is about to penetrate, and thus gain the anterior chamber, the handle of the knife is to be inclined backwards, by bringing the hand into its former position, so that the surfaces of the blade may become parallel to the iris and base of the cornea. At the same time that this manœuvre is executed, the handle of the knife is to be inclined a little downwards, so that the point may be directed a little upwards, as if to make counter-puncturation at a point higher than is really intended, otherwise, in consequence of the depression which the point of the knife necessarily experiences in its progress towards the opposite side of the cornea, counter-puncturation would fall too low, and the section of the cornea would consequently be too small.

Passage of the knife across the anterior chamber, and counter-puncturation.—Immediately on puncturation being effected, the knife is pushed steadily and quickly on through the anterior chamber, to the opposite side of the cornea, and until counter-puncturation is accomplished. The point of the cornea where this should take place is one-fortieth of an inch from its nasal margin, and corresponding to, or a little above, the transverse diameter.

If, before counter-puncturation is effected, the aqueous humor should escape by any accident, such as the sudden movement of the eye away from the knife, in such quantity that the iris falls forward against the cornea, further proceedings should be desisted from, and the operation deferred until the restoration of the aqueous humor, and the subsidence of the reaction, if any, which may have taken place in consequence of the simple puncturation. Or if the eyeball should roll inwards and upwards so much that the surgeon cannot see the opposite side of the cornea, and if the patient cannot turn the eyeball right, it is better to withdraw the knife than counter-puncture at hazard.

Cutting out.—In pushing the knife on in order to cut out, its edge must not be pressed down against the substance of the cornea which it is cutting, but, by lowering somewhat the handle, the back of the knife should rather be kept pressed up against the upper angle of the wound of counter-puncturation. By this means the blade of the knife is made to fill both the incision and counter-

[1] The perpendicular direction recommended to be given to the point of the knife, in commencing puncturation is to obviate the risk of the point of the knife being thrust obliquely into the substance of the cornea, instead of penetrating directly through its substance into the anterior chamber. That the knife has been thrust into the substance of the cornea, and not penetrated into the anterior chamber, is readily perceived by the dull-looking way in which the knife shines through, in comparison to what it does when it is fairly in the anterior chamber; and also, by the continuance of resistance to the onward progress of the knife. All this can be readily illustrated by practising on the eye of a sheep or pig.

incision in the cornea, in proportion as it makes them, and thus no room is given for a premature escape of aqueous humor.

When the knife has almost cut itself out, a pause is to be made; the surgeon, having now complete command over the eyeball, makes it turn rather outwards, if in completing the section of the cornea, the point of the knife threatens to come upon, and be stopped by, the parts at the inner canthus. After this, the tag of the cornea which remains is to be slowly and cautiously cut by a sawing motion. The upper eyelid is at the same time to be let go, and as soon as the tag is cut, and the knife withdrawn, the lower eyelid is to be allowed to rise, care being taken that its border does not interfere with the corneal incision.

Whilst the cutting out is thus being accomplished, the patient is to be cautioned not to hold his breath, or make any effort to squeeze the eyelids together, for at this moment the lens, with a portion of vitreous body, if the latter is at all in a dissolved state, is apt to burst out. For fear of this it has been advised to leave the tag of cornea uncut, allow the eyelids to close, and cut the tag only after laceration of the capsule has been effected.

If, in cutting out, the iris should fall against the edge of the knife, in consequence of premature escape of aqueous humor, the surgeon should pause, and whilst pulling the eye forwards with the whole knife, apply the point of the middle finger against the cornea, and try by gentle pressure to disengage the iris from the edge of the knife, and to keep it so whilst completing the section. If this does not succeed, and if much of the iris lies before the edge of the knife, this instrument should be withdrawn, and the section completed as well as possible with the probe-pointed knife, or Daviel's scissors. But if a small part merely of the iris falls before its edge, the knife may be pushed on, even although the piece of the iris be cut off. If in consequence of this excision of a piece of the iris an opening is made, this and the pupil should be thrown into one by dividing the isthmus before concluding the operation.

Fig. 30.

Section of the cornea upwards.—This has of late years been the method preferred. The procedure differs from that above described only in the circumstances, that the edge of the knife is directed upwards—the back, which is directed downwards, as in the former case, being horizontal—and that the points of puncturation and counter-puncturation should be *below* instead of *above*, the transverse diameter of the cornea. In this case also, greater care is required at the time of completing the section of the cornea, in withdrawing the knife, and allowing the upper eyelid to fall down, for

in consequence of the tendency of the eyeball to roll up suddenly, the flap of the cornea is apt to be caught either by the knife or by the edge of the upper eyelid, and to be folded down.

Section of the cornea in its outer and lower half.—This was the section generally adopted by the first Wenzel (who used a double-edged knife for the purpose), and has again been pretty extensively practised by Professor Rosas, of Vienna (who uses a Beer's knife, with a sharp-cutting back), and the late Mr Tyrrell, who used the common Beer's knife. To effect the section, puncturation is made on the temporal side, 45° above the horizontal diameter of the cornea, and counter-puncturation below the horizontal diameter on the nasal side; so that of the semicircular incision, one-fourth is above, and three-fourths below, the horizontal diameter.

If, in consequence of the iris having fallen against the edge of the knife, it has been necessary to withdraw this instrument, the section of the cornea is best completed with the probe-pointed convex-edged knife (Fig. 30, p. 253). It is to be entered into the anterior chamber of the wound of puncturation, and its blunt point run close along the posterior surface of the cornea until it passes out by the wound of counter-puncturation. The convexly curved

Fig. 31.

edge of the knife approaching so near the part of the cornea to be cut does not leave room for the iris to fall against it, while by a sawing motion the section is completed.

The incision made in this manner by a knife heals better than one made by scissors. If, however, the surgeon finds he can effect his purpose more easily by means of Daviel's or even the common curved scissors, the disadvantage attending a division made by them is, on the whole, not so great as to deter from their employment. Daviel's scissors, and the mode of using them in enlarging the section of the cornea when too small, are described below.

Enlargement of section of the cornea when too small.—The section of the cornea may prove too small, either in consequence of the incision being too much within the margin of the cornea, thus—Fig. 32—

Fig. 32. Fig. 33.

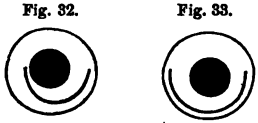

or not extending to the half of the circumference, as Fig. 33.

The first mentioned defective section can scarcely be remedied, the second may be so very readily.

For enlarging the section of the cornea when too small, either a probe-pointed concavely-curved edged knife, such as is here represented, Fig. 34, or a pair of curved scissors, may be employed.

Fig. 34.

When the knife is used, it is held as the cataract knife, and it is introduced through the incision of the cornea flatways, its round and blunt point gliding against the posterior surface of the cornea, contact with the iris being avoided as much as possible, and its edge directed against the angle where the incision is to be enlarged. By withdrawing the knife a little the cornea is cut; the knife being again pushed in, it is again a little withdrawn, and an additional cut made, and so on, cutting only on withdrawing the knife, until the wound is sufficiently enlarged, and that as much as possible in a line concentric with the margin of the cornea.

When scissors are had recourse to, Daviel's are those recommended, though a pair of simple curved scissors will answer the purpose. Daviel's scissors have a double curve, to adapt them to make as direct a snip of the cornea as possible. Two pairs bent in opposite ways are consequently required. One pair to enlarge the incision, supposing the section downwards, on the temporal side of the right eye, and on the nasal side of the left; or supposing the section upwards, to enlarge the incision on the temporal side of the left eye, and on the nasal side of the right. Another pair to meet the opposite circumstances. (Figures 35 and 36, p. 256.)

The way in which the scissors are to be held is this: The thumb in one ring, the ring finger in the other, the point of the forefinger on the joint, the middle finger, on the branch in the ring of which the ring finger is. The thumb and ring finger may be inserted into the rings, either from the convex or concave surface of the scissors, according to circumstances; but the convexity of the instrument ought of course always to be towards the eye.

Supposing the eye operated on to be the left, that the section of the cornea is downwards, and that it is on the temporal side the incision is to be enlarged, the pair of scissors to be used is that which, when held as above described, will present the concavity of its late-

ral curve towards the centre of the cornea. The blades then being sufficiently open, the point of the one next the centre of the cornea is to be introduced flatways behind the flap of the cornea, and care-

Fig. 35.

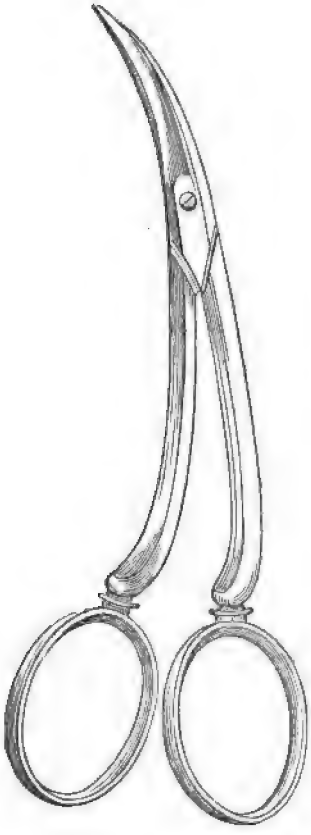

Fig. 36.



fully slid up between the cornea and iris to opposite that part of the circumference of the cornea which is to be cut.

There are now two precautions to be observed:

1st. In order to avoid haggling, the edges of the scissors should be directed, as much as possible, at right angles to the part to be cut, which is done by turning the scissors a little on their axis towards the nose.

2d. In order that the cut may be made as large as desired at

one stroke, their points should extend somewhat beyond the point in the cornea to which it is wished to enlarge the incision, because during the stroke the instrument necessarily slips somewhat back.

General observations on the precautions to be observed in making the section of the cornea.—According to the direction in which the edge of the knife is inclined, when it pierces the cornea, and is passing across the anterior chamber, so must that of the section be. If the knife is properly held and entered, all that the surgeon has to do in carrying it across the anterior chamber, is to watch its point, so that the counter-puncturation may be made at the proper place; this being effected, all that is now required is to push the knife steadily on in the manner above described, and it inevitably goes right. But if it has been ill-entered at first, though the deviation of its surfaces from parallelism with the surface of the iris and base of the cornea may have been very slight, the deviation of the edge from the right direction of course increases with the progressive movement of the knife, and then if attempts are made to bring the knife again into a proper direction, they cause the opening in the cornea already made to gape, and thus the aqueous humor is allowed to escape, so that the iris falls against the edge of the knife.

If the faulty direction of the edge of the knife is such that it will cut out too soon, so that the section will turn out too small, the operator should nevertheless proceed, and enlarge the incision afterwards. If, on the contrary, the direction of the edge of the knife is too much inclined towards the sclerotica, so that if the knife were pushed on it would cut both it and the conjunctiva, it should be withdrawn in time, and the section of the cornea completed with the probe-pointed knife or Daviel's scissors.

Fig. 37.

Laceration of the capsule and extraction of the lens, when the downward section has been made.—Different shaped instruments are in use for lacerating the capsule; sickle-shaped, or straight broad-pointed cataract needles, but the simplest instrument is one like a common sewing needle, bent at the point (Fig. 37). The instrument, of whatever form it may be, is commonly fixed on the same handle with the curette (Fig. 38), which is employed for assisting in the extraction of the lens.

The assistant having gently raised the upper eyelid, without making the slightest pressure on the eyeball, and the patient being directed to turn the eye a little upwards, the surgeon with one hand depresses the lower eyelid, and with the other slips the bent needle with the convexity of its curve first behind the flap of the cornea, until opposite the pupil, and then up as far as he can behind the iris. This being

done, he rotates the handle of the instrument so as to turn the point against the upper part of the cataract. By a rotatory movement now of the handle whilst held horizontally, he makes the point of the instrument lacerate the capsule from above downwards as far as the middle. He next, in a similar manner, lacerates the lower part of the capsule by a stroke from below.

In its natural state, the capsule, when punctured merely, will readily tear and allow the lens to escape; and although in lenticular cataract the same thing will often take place, it is proper not to trust to this, but to take pains to lacerate the anterior capsule freely, as just described.

The capsule having thus been freely lacerated, the instrument is to be carefully withdrawn with its convexity foremost, so as not to hook the iris or cornea.

It often happens that immediately on the laceration of the capsule, the lens begins to escape; if it does so, the surgeon will at once proceed to help it out in the manner to be described below; but if it does not, the eyelids are to be allowed to fall together for a minute or so before the extraction is proceeded with.

Fig. 88.

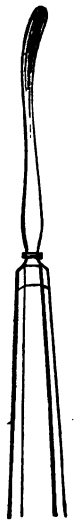

In the former case, the assistant still keeps the upper eyelid carefully elevated without making pressure on the eyeball, whilst the operator, continuing to keep down the lower eyelid with the hand, takes the curette in the other, and watches the progress of the escape of the lens, the advance of its lower edge through the pupil, its clearing the pupil, and its final escape through the incision of the cornea. Whilst this is going on, the patient is to be directed to turn the eyeball upwards. No farther interference may be required, but, if necessary, gentle pressure is to be made on the lower part of the eyeball, at some little distance from the margin of the cornea, and this may be done either by the surgeon pressing the margin of the lower eyelid which he is holding against the eyeball, or employing the curette for the purpose.

In the latter case, after the pause, the eyelids are opened as before, and the patient being directed to look upwards, the surgeon makes gentle pressure on the lower part of the eyeball, when the lens will be seen to slide by its lower edge through the pupil, which it stretches, to raise the flap of the cornea, and finally make its escape through the incision. If its escape through the incision of the cornea should be stopped, the lens is to be helped out by the bent point or by the curette from between the lips of the incision.

Laceration of the capsule, and extraction of the lens when the upward, or the downward and outward section has been made.—This part of the operation is effected in a manner essentially similar to that above described for the downward section; only in the one case, the laceration of the capsule is to be made from below upwards, and in the other from above downwards to below and outwards. In the extraction of the lens again, the patient should in the one case be directed to turn the eye downwards, and any pressure on the eyeball which may be necessary is to be made with the curette on its upper part, whilst in the other the patient turns the eye inwards and upwards, and pressure with the curette is made on the lower and outer part of the eyeball.

Fig. 39.

In its passage out, some of the soft exterior of the lens is often stripped off and retained in the aqueous chamber. No attempt need be made to remove this, as it becomes by-and-by absorbed. If, however, the lens should break in pieces, and a considerable piece be left in the anterior chamber, it should be scooped or hooked out.

After a few minutes' rest to the patient, the surgeon gently opens the eyelids to see if the iris and flap of the cornea are in their proper position, and the pupil clear. If the iris and pupil do not appear to be quite right, the upper eyelid is allowed to close, and is to be rubbed gently with the finger over the front of the eyeball, and then quickly opened to the light, when the iris will contract, and will thus, along with the pupil, be brought into a proper situation. This being the case, and the flap of the cornea in accurate apposition, the eyelids are to be closed—first the upper and then the lower.

If, after laceration of the capsule and moderate pressure on the eyeball, the lens does not advance, the surgeon must consider whether or not the section of the cornea is large enough, and whether or not the capsule has been sufficiently lacerated. If he is assured that everything is right in these two respects, an attempt is to be made to extract the cataract with a hook (Fig. 39).

Bandaging of the eye and treatment after the operation.—The flap of the cornea lying in proper apposition, the eyelids are to be closed. The upper eyelid is allowed to fall slowly over the eye,

when the upper section has been made. If it has been the lower section, it must be carefully seen that the edge of the lower lid does not interfere with the lower part of the flap; if it does so, the lower lid should be kept somewhat retracted by a strip of plaster, extending from it down on the cheek.

Both eyes are to be kept closed, and for this purpose a narrow strip of court-plaster [or gauze and collodion], extending from the eyebrow to the cheek, is to be applied over the eyelids on each side; whilst over all a shade composed of a fold of soft linen, to which is fixed a tape to tie round the head, thus—is to be hung.

Fig. 40.

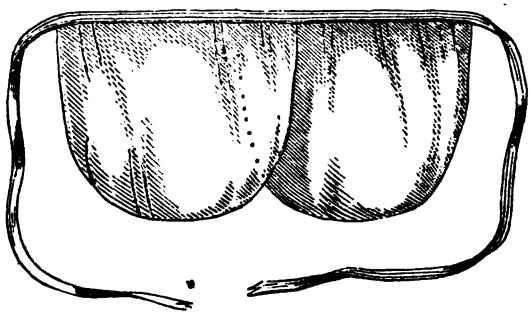

Another method of bandaging is to lay over the eyes when closed a light compress, and secure it by a band, the middle of which is laid over the nape of the neck, and the ends brought over the eyes, crossed on the forehead and pinned to each other behind.

The patient need not be put to bed immediately after the operation, unless he desires it, but may recline on an easy chair or sofa, until about his usual bedtime. The room should be somewhat darkened, and perfect quietness observed in the house. The patient should refrain from speaking, and endeavor to keep himself as composed as possible. His food should be so prepared as not to require much chewing.

At bedtime an opiate should not be omitted, if the patient is in the habit of taking one to procure sleep; if not in the habit, an opiate is to be given only if the patient is restless and not disposed to sleep.

Some practitioners make it a practice to bleed the patient to ʒviij or ʒxvj, on the evening of the operation, if he has not been bled before; but this is unnecessary, if the patient is, as he should be, in a proper condition at the time of the operation. It is time

enough to take blood, when symptoms of undue inflammation, such as pain in the eye, redness and swelling of the eyelids, begin to manifest themselves; and these symptoms ought to be carefully watched for from day to day. The third or fourth day is the time at which they most generally occur.

During the night the patient should be watched, lest by turning in bed or rubbing the eye with his hand while asleep, the eye should be injured. A good precaution is to secure the patient's hands to his side, so far that they may be prevented from being carried to the eye.

The patient should lie on his back until at least the third day, when, if matters go on well, he may sit up in bed. On the fourth day, he may be allowed to get out of bed for a few hours in the afternoon.

During the twenty-four or forty-eight hours succeeding extraction, the patient feels as if he had received a blow on the eye, and also from time to time experiences a slight smarting and pressing sensation, which is always relieved when a watery fluid, partly tears, partly aqueous humor, escapes from the eye. From these and incrusted Meibomian secretion, the eye is to be from time to time carefully cleansed with tepid water and a soft linen rag. The eye is not to be opened until the fourth or fifth day, but that things are going on well may be inferred if there is no pain, and the upper eyelid neither red nor swollen. On the fourth day, after the borders of the eyelids have been cleansed from any adherent matter, by means of tepid water, and a bit of soft lint, as just mentioned, and the strips of black court-plaster, if they have been used, removed, the eye may be opened and looked at, but closed again, and so on, from day to day, until the ninth or tenth. After that, the eyes being protected by a shade, the patient may freely open them. [Great mischief may be done by too early and too frequent examination of the eye. There is nothing to be gained by such interference, and everything to be lost. We have no doubt that it is a common cause of delay, if not of greater injury, after needle operations as well as after extraction. See Haynes Walton, p. 431, and Hays' Lawrence, p. 714.]

The corneal incision heals in the course of two or three days or even sooner, if there is nothing to prevent union by the first intention, such as prolapsus iridis, with or without prolapse of the vitreous body, or non-apposition of the edges of the incision. The incision, when enlarged by scissors, is apt not to heal completely by the first intention.

Untoward occurrences during the operation.—Protrusion of the iris may take place on the completion of the section, and again after the lens has been extracted. If uncomplicated with escape or protrusion of vitreous humor, the protruded iris is in general readily

replaced by means of the curette. After which the upper eyelid is to be drawn down, the finger rubbed over it at the place corresponding to the cornea, and then suddenly raised so as to expose the eye to the light. By this means, contraction of the pupil is excited, and the iris more fully drawn into its place.

Of all the untoward circumstances which may occur in performing the operation of extraction, the protrusion or escape of the vitreous humor in greater or less quantity is assuredly that most to be dreaded. For though it may be promoted by undue pressure on the eyeball, either by the operator or assistant, restlessness of the eye, or spasmodic contraction of the muscles of the eyeball at the time of completing the section of the cornea or afterwards, the condition on which it essentially depends is a softened or dissolved state of the vitreous body and its connections.

When the vitreous body is of its natural consistence, and its connections unweakened, as in young persons, there is little danger of its escape,—nay, if its escape were desired, it would perhaps not be easy to produce it by any ordinary pressure. To be convinced of this take the eye of an animal newly slaughtered, make a free section of the cornea, and then try to squeeze out the vitreous humor. It is only when the connections of the vitreous body have become dissolved by keeping the eye for twenty-four hours or so after death, that the vitreous body can be readily squeezed out. With the advance of age, however, softening of the vitreous body and its connections, as above observed (p. 205), tends to take place; hence it is that in the operation at present under consideration, viz., extraction of the common hard lenticular cataract of old persons, bursting out of the vitreous humor, with or without the lens, is so apt to occur.

Bursting out of the lens together with a greater or less quantity of vitreous humor immediately on completing the section of the cornea.—In this case the operation is completed, and whether it is likely to be followed by a good or bad result will, in a great measure, depend on the quantity of vitreous humor lost. If the quantity does not exceed one-fourth, it is possible for the eye to recover with pretty good vision; if more is lost, such an event is not to be hoped for.

In any case the mode of procedure is to close the eyelids immediately, and after some time, cautiously open them to see how the flap of the cornea lies. If the iris, as is very apt to be, is protruded, an attempt is to be made by the manœuvres above described, to replace it, and bring the edges of the corneal wound together, as far as can be done, preparatory to bandaging the eye. A portion of the hyaloid, however, may protrude, and thus prevent the replacement of the iris, and accurate closure of the corneal wound. All that can be done now is to close up the eyelids, and leave things to

nature. Under the most favorable circumstances, the wound of the cornea heals slowly, and the pupil is dislocated towards the cicatrice. Still, good vision may be restored.

Vitreous humor may begin to escape without the lens.—In this case the small hook is immediately to be introduced, and the cataract hooked by its lower edge, and brought out as quickly as possible.

If the cataract should sink in the vitreous humor nearly or quite out of sight, some attempt may be made to hook it out, but not persisted in if unsuccessful. In this case it must be left, and the eye closed, otherwise the complete evacuation of the vitreous humor will inevitably take place.

Untoward occurrences after the operation.—Inflammation, &c., occurring in consequence of the operation.—Though the cataract may have been extracted without accident, and though when the eye is bound up everything appears right, untoward circumstances may yet occur in the course of the following seven days. The most to be dreaded is inflammation, both external and anterior-internal, and which may be acute or slow, in either case impeding the union of the corneal incision and disposing to protrusion of the iris.

In the *acute inflammation*, along with severe pain, the eyelids are swollen, red, and tender to the touch, the conjunctiva is red, and perhaps in a state of inflammatory chemosis, the edges of the corneal incision are opaque, swollen, and everted, and the iris is discolored.

In the *slow inflammation*, which is apt to occur in old weakly persons, the pain may not be less severe than in the acute, but the swelling of the eyelids is merely œdematous, and the chemosis of the conjunctiva serous. The edges of the corneal incision are whitish-gray, the iris is discolored; pulse small and feeble; the patient is low and restless.

The acute inflammation requires to be treated actively by venesection and mercury, with low diet, and laxatives. Under the circumstances, the use of mercury has been dreaded, lest it might check the adhesive process, and thus prevent union of the section of the cornea. Experience, however, shows that after the operation of extraction the patient may be put under the use of mercury, without any prejudice to the union of the section of the cornea, but the reverse; for the mercury, reducing inflammation, promotes adhesion.

The slow inflammation is equally dangerous with the acute, but requires to be treated on an opposite plan, viz., with cordials and generous diet.

Secondary prolapsus iridis.—It has been above stated that prolapsus iridis is apt to take place at the time of the operation (*pri-*

mary prolapsus iridis); but though such has not occurred, the eye is not yet safe from prolapsus iridis, for in the course of the three or four days following the operation, the iris may yet protrude. This secondary prolapsus iridis may be occasioned by the bursting open of the half-healed corneal wound in consequence of some such effort as coughing, but it is generally owing to non-union of the corneal incision, and swelling of the iris, occasioned by the supervening inflammation.

Nothing should, in general, be done directly. If the protruded iris be large, and appear to be much distended by fluid behind, the propriety of puncturing may come to be a question. As the inflammation subsides, the protrusion sinks, and the iris will be involved in the cicatrice of the cornea, which will be broad and unsightly, whilst the pupil will be displaced and contracted, or altogether closed. By-and-by, touching the protruded iris once a day or every second day with the nitrate of silver pencil, will promote cicatrization. This may even be done from the first, if, instead of inflammation, there is defective action in the part.

Fig. 41.

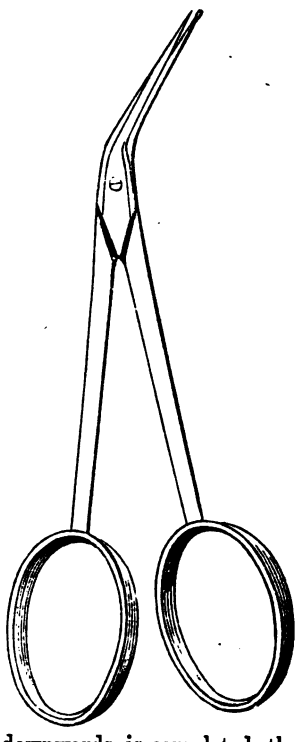

Extraction in a case complicated with synechia posterior.—In such a case the section of the cornea must be the lower, or the lower and outer. This is in order to permit of the introduction of Maunoir's scissors (Fig. 41), with which the iris along with the anterior capsule is to be cut to an extent sufficient to allow of the escape of the lens.

Advantages and disadvantages of the three different sections of the cornea.—The section downwards is on the whole more easily made than that upwards; the lower half of the cornea in general admitting of being better exposed, and thus more accessible to the knife than the upper half.

When the section of the cornea downwards is completed, the knife is more readily withdrawn, and the upper eyelid can be allowed at once to fall gently down over the flap without disturbing it; whereas, when the section upward

is completed, more nicety is required in withdrawing the knife and letting down the upper eyelid, in order that its border may not catch the flap of the cornea, and turn it down.

When the section downwards has been made, the escape of the lens takes place more easily, and less injuriously to the iris and corneal flap, than when the section upwards has been made, the tendency of the eyeball to roll upwards and inwards, being a great impediment to the escape of the lens in the latter case.

Escape of vitreous humor, it has been thought, takes place more readily, when the section is downwards than when it is upwards, in consequence of the operation of gravity, but this is not the case. It has been above seen, that this accident is owing to the vitreous body being in a dissolved state, and thus readily squeezed out by the spasmodic action of the muscles of the eyeball, an effort which is produced in whatever direction the section may be made, and whether the patient be lying horizontally or seated upright.

Nor is prolapsus iridis more prone to take place when the section is downwards than when it is upwards; but if it does take place when the section is downwards, the bad cicatrice which results is more readily seen, interferes more with vision, and if the pupil be closed, an artificial pupil cannot be made in so advantageous a situation afterwards. The contrary of all this is the case when the section is upwards; a bad cicatrice from protrusion of the iris and vitreous body is not seen, nor does it interfere with vision, and, supposing the pupil closed, the eye is in a better state for artificial pupil.

On the other hand, the pupil, though drawn towards the incision, may be of good size. In such a case, it is more useful when situated next the lower margin than when it is next the upper margin of the cornea.

The flap of the cornea when the section is upwards, is kept in good apposition by the upper eyelid, whereas when the section is downwards, the tarsal border of the lower eyelid is apt to displace the edges of the corneal flap, and so give rise to inflammation, prolapse of the iris, &c. This, may, however, be obviated by care.

The section downwards and outwards shares in advantages and disadvantages of the other two sections.

Extraction of capsulo-lenticular cataract.

It is well known that an opaque capsule does not become dissolved and absorbed as the lens may be. In capsulo-lenticular cataract, therefore, it may be necessary to remove the opaque capsule as well as the lens, out of the axis of vision.

The lens being extracted in the usual way, if shreds of the opaque capsule occupy the axis of the pupil, an attempt may be made to extract them. For this purpose the slender-bladed hooked

Fig. 42.

forceps is employed (Fig. 42). This instrument, closed, being introduced through the incision of the cornea, and its point passed through the pupil, is opened, and the shreds of opaque capsule laid hold of, cautiously detached by a gentle twitch, and extracted. If there be any indications of a dissolved state of vitreous body, this attempt to remove an opaque capsule is not safe. It is better to leave it, and by a subsequent operation with the needle, displace it from the axis of vision, or extract through a small opening of the cornea, as in the following case.

Extraction of siliquose cataract.

For the extraction of siliquose cataract a section one-third of the circumference of the cornea is sufficient. The section being made, the slender-bladed hooked forceps (Fig. 42), or a hook, is introduced, the cataract seized, cautiously detached from its connections, by being twisted and moved in different directions, and extracted.

Dr. Mackenzie recommends the siliquose cataract to be first detached and pushed into the anterior chamber by means of a cataract needle, introduced through the sclerotica, then the small section of the cornea to be made, a hook introduced, the capsule laid hold of and extracted.

In cases of capsulo-lenticular and siliquose cataract, the same good vision is not in general restored by extraction, as in cases of common hard lenticular cataract; but this is because the retina in those cases is not in general quite so sound. The result may be as good, however, as is consistent with the nature of the case, and better than could be obtained by any other mode of operating.

Shreds of opaque capsule and siliquose cataract have been sometimes extracted through a small opening in the sclerotica and subjacent ciliary body. The opening is made at the place of puncture in needle operations. Various ingenious hooks, forceps, &c., have been invented for effecting the extraction.

DISPLACEMENT OF THE CATARACT AND ITS MODIFICATIONS.

There are two modifications of the operation of displacement, viz., *couching* or *simple depression*, *and reclination*. In the one case, the displaced lens has its anterior surface downwards and somewhat forwards,—its posterior surface, upwards and somewhat backwards,—its superior edge forwards and somewhat upwards,—its lower backwards and somewhat downwards, thus:

Fig. 43.

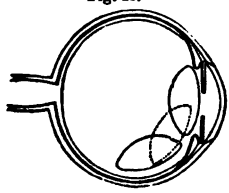

In the other case, the displaced lens has, at the same time that it was depressed, been made to turn back on its lower and outer margin, so that, its upper edge being forced back into the vitreous humor, its anterior surface comes to be uppermost, its posterior surface directed downwards, thus:

Fig. 44.

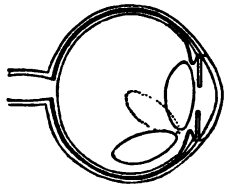

Both couching and reclination of the cataract may be effected by introducing the cataract-needle, either through the sclerotica, that is, *by sclerotic puncturation* (*scleroticonyxis*), or through the cornea, that is, *by corneal puncturation* (*keratonyxis*).

Reclination effecting all that couching can, and being in every respect a better operation, couching has altogether fallen into disuse. It is, therefore, unnecessary to say more about it here.

Indications for the operation of displacement.—The kind of cataract best fitted for displacement is the same as that best fitted for extraction. Whether or not, therefore, displacement should be performed instead of extraction, will depend upon the absence of the conditions necessary for or at least favorable to the successful performance of extraction (p. 247), or the existence of the conditions unfavorable to or wholly forbidding it (p. 247).

Fig. 45. Fig. 46.

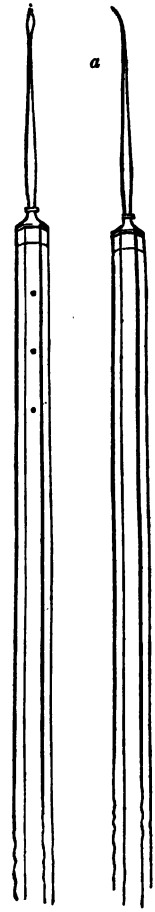

Prognosis.—The displaced lens, if disengaged from its capsule, may eventually disappear, or be reduced to a small size by solution and absorption. In many cases, however, it does not dissolve, and is always apt to rise again. The success of displacement is apt to be marred by posterior internal inflammation, either of an acute character, supervening immediately on the operation, or of a slow destructive character, coming on some time subsequently, and leading to loss of sensibility of the retina.

Instrument and dressing.—The only instrument required is a lance-shaped cataract needle, either straight or curved. (Figs. 45, 46). The dressings are the same as above mentioned for extraction.

Reclination by sclerotic puncturation.

For the convenience of description, the operation may be supposed to be divided into different steps.

The first step comprehends puncturation. The point of puncturation should be about three-twentieths of an inch from the temporal margin of the cornea, and in the line of its transverse diameter.[1]

The second step comprehends laceration of the posterior wall of the capsule, and corresponding part of vitreous body.

The third step comprehends the introduction of the needle into the posterior chamber, so that its lance head is seen through the pupil.

The fourth step, laceration of the anterior wall of the capsule, and the reclination of the cataract.

The pupils of the patient should be well dilated preparatory to the operation.

The position of the patient, assistant, and operator, is arranged as above recommended (p. 244, et seq.)

Method of holding the cataract needle.—The handle of the needle is to be held between the fore and middle fingers on the one hand, and the thumb on the other, much in the same way as above recommended for the cataract knife.

Puncturation.—The surgeon thus holding the needle, and resting his hand by the little finger on the patient's cheek, disposes it in such a way, that the blade of the needle is close in front of the cornea, in a line corresponding to the transverse diameter of the

[1] The direction to introduce the needle either above or below the transverse diameter of the eye is that which is most generally given; and the reason assigned for it is, that the long ciliary artery runs in the line of the transverse diameter; but as at about a quarter of an inch from the iris the long ciliary artery of the temporal side divides at an acute angle into two branches, an upper and a lower, it is obvious that the artery cannot be touched, and the surest way to avoid the branches is, to enter the needle as above recommended.

latter, and its point extending to opposite the nasal margin of the dilated pupil. He now prepares for puncturation, by retracting the fingers holding the needle, and slightly turning the hand, so that the point of the instrument may be presented to the point of the sclerotica, where puncturation is to be made.

If it be a straight needle that is used, its point, with the cutting edges looking to and from the cornea, the flat surfaces upwards and downwards, is directed perpendicularly to the surface of the eyeball at the place above mentioned, and steadily thrust in in a direction towards the centre of the eyeball, but no deeper than until the lance-head of the instrument disappears.

When a curved needle is used, its convexity should look upwards, and its concavity downwards in making the puncture; and in order that the point may be applied perpendicularly to the place to be punctured, it is necessary to depress the handle of the instrument; but of course, in proportion as the instrument penetrates, the handle is raised to the horizontal.

Laceration of the posterior wall of the capsule, and breach in the vitreous body for the reception of the lens.—Puncturation being accomplished, the head of the needle, with its cutting edges upwards and downwards—if a curved needle, the concave surface of course forwards,—is to be directed against the posterior wall of the capsule, and made to lacerate it and the vitreous body behind and below it, to the necessary extent.

Introduction of the needle into the posterior chamber, so that its lance-head is seen through the pupil.

Having lacerated the posterior wall of the capsule, and made a breach in the vitreous humor for the reception of the lens, the surgeon, withdrawing the instrument now so far that its neck comes again to correspond to the point of puncture, as it did when first introduced, and assuring himself by the marks on the handle, that the edges of the lance-head are directed upwards and downwards; and, if the needle be a curved one, that the convexity of

Fig. 47.

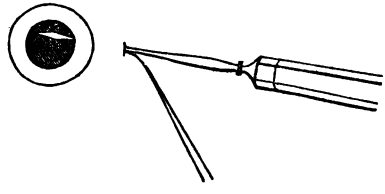

the curve is forwards, and the concavity backwards, inclines the handle of the instrument well back towards the temple of the

patient, and proceeds to put its lance-head into the posterior chamber, where it will be seen through the pupil with one surface looking forward, the other towards the cataract, and its edges upwards and downwards. (Fig. 47.)

In this step the needle necessarily passes through the circumferential part of the crystalline lens and capsule. But care should be taken not to spit the firm nuclear part of the lens on the one hand, or the ciliary body on the other. If this should occur, the needle ought to be a little withdrawn, to get its point free again, before pushing it on. In entering the posterior chamber, the point of the needle is apt to spit the iris, especially if the needle be a straight one. The remedy for this also, is to withdraw the instrument, until its point gets free, when it may again be pushed on. The importance of having the point of the needle free is evident. Again, the point of the needle may be made to project through the pupil, and spit the inner surface of the cornea.

Laceration of the anterior wall of the capsule, and reclination of the cataract.—In the last step, the lance-head of the needle appeared in the posterior chamber, by piercing the anterior wall of the capsule from behind. Such movements are now to be executed with the point of the needle as are calculated to insure the free laceration of the anterior wall of the capsule both vertically and horizontally.

Being sure that the point of the needle is free from entanglement, the surgeon now applies its lance-head flat against the lens, a little above its transverse diameter (if the needle is a curved one, it is by its concave surface that its lance-head is to be applied to the lens), and then by moving the handle of the instrument gently forwards a little, he presses back the upper part of the lens. When the upper part of the lens has yielded to this backward pressure, he rotates the needle slightly to keep it flat on the surface of the lens, and then presses the latter downwards, backwards, and outwards, by gently raising the handle of the instrument upwards, forwards, and inwards. The lens being thus depressed, is to be moved a little backwards, if its lower edge, now become anterior, should appear to press on the iris or ciliary body.

If the needle used is a curved one, it will be necessary, in order to complete the depression, to apply the convexity of its lance-head to the cataract. This is done by depressing the handle a very little, so as to lift the lance-head from off the cataract, and then rotating it one half round its axis.

Withdrawing the needle from the eye.—Having for half a minute or so, kept the point of the instrument resting on the depressed cataract to prevent it from rising, the surgeon now lifts it slowly

from off the cataract, by lowering the handle. Seeing that the cataract does not rise, he brings the head of the instrument back into the posterior chamber, by moving the handle a little backwards. Here the surgeon still retains the instrument within the eye for half a minute longer. The cataract remaining depressed, the needle may now be withdrawn from the eye by a series of manœuvres exactly the converse of those performed in introducing it. This is especially to be attended to, when its head comes to the puncture in the coats; here it is to be so rotated, that the surfaces shall be above and below as at the introduction of it, and then it is to be drawn out at right angles to the surface of the sclerotica, for which purpose, when the needle is curved, its handle must be depressed in proportion as the head is withdrawn.

If instead of being hard, as was supposed, the cataract should be found friable, breaking under the needle, reclination ought not of course to be persisted in, but the lens left to be dissolved and absorbed; in short, division is to be substituted for reclination. Sometimes the exterior strata of the lens are soft, and the nucleus hard; in this case the latter should be reclined and the former divided.

Reclination as now described, is in general readily effected in the common lenticular cataract of old people; but sometimes the cataract rises as soon as the point of the needle is withdrawn from it, and this over and over again. Such a cataract has been called *elastic cataract.*

The cause of the elastic reascension of the cataract is, I am disposed to believe, that in such cases the vitreous body still possesses its natural consistence, and therefore resists the sinking of the lens into its substance, as every one who has been accustomed to dissect healthy eyes, knows the vitreous body will do.

A persistence in attempts at displacement in such a case, would prove extremely detrimental to the internal structure of the eye. The attempt, therefore, ought not to be repeated, until the posterior wall of the capsule has been again lacerated, and a freer breach made in the vitreous body, for the reception of the reclined lens.

I would however remark, that when the vitreous body is of such firm consistence as to resist the lens being forced into its substance, extraction of the cataract would be a much better and safer operation, if there existed no particular indication of any weight against it.

The lens may, instead of going down before the needle, suddenly burst through the pupil into the anterior chamber. In such a case, if it appears that it was on account of the firmness of the vitreous body that the lens did not yield to the needle, the surgeon should immediately proceed to extraction; but if it appears that the vi-

treous body is dissolved, the connections of the lens weakened, and that on these accounts it was that the lens slipt into the anterior chamber, it would be safer practice, instead of extracting, to endeavor with the needle to bring the cataract back through the pupil, and to depress it.

If extraction be had recourse to, it will be sufficient to make a section of one-third only of the circumference of the cornea. This being done, a hook is introduced, the lens laid hold of, and extracted.

Reclination by corneal puncturation.

The instrument for this operation is the curved cataract needle.

The pupil should be well dilated, preparatory to the operation, and the position of the patient, assistant, and operator, arranged as above recommended (p. 244, et seq.)

The needle is held between the thumb on the one side, and the fore and middle finger on the other. The side of the handle on which the thumb is, corresponds to the convexity of the instrument; that on which the fore and middle fingers are to the concavity.

The first step comprehends the puncturation, the advance of the point of the needle through the dilated pupil, towards the cataract, and the application of the convexity of the needle against the upper part of the anterior surface of the cataract.

The second step is the reclination of the cataract.

The third step is the withdrawing of the needle from the eye.

Puncturation, &c.—The point of the cornea where puncturation is made, is about one-twentieth of an inch below its centre.

Holding the needle as above directed, the operator directs the lance-head of it towards the place of puncturation in such a way

Fig. 48.

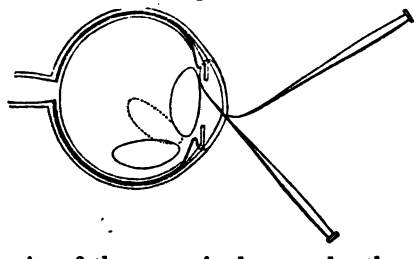

that the convexity of the curve is downwards, the concavity upwards, the extreme point perpendicular. The handle of the needle must therefore be directed upwards. (Fig. 48.)

When the eye is in proper position, the operator pierces the cornea perpendicularly, with a quick but steady thrust, executed solely by the movements of the thumb and fingers holding the instrument. When the lance-head of the needle has penetrated as far as the middle of its curve, the handle of the needle is to be gradually depressed towards the cheek, the puncturation completed, and the needle pushed on through the pupil, with the point upwards, and the convexity of its curve towards the upper part of the cataract behind the upper part of the iris. (Fig. 48.)

Reclination of the cataract.—Having applied the convexity of the needle against the upper part of the anterior surface of the cataract, and right in the middle line, the operator raises, gently at first, the handle of the instrument. The instrument acting as a lever, the fulcrum being the point of puncturation in the cornea, the point of the needle is by this movement made to press back the upper part of the cataract.

When the operator sees that the upper part of the cataract yields, he continues to raise the handle of the instrument firmly and steadily, thus turning the cataract before the needle downwards and backwards, and sinking it in the vitreous humor.

Having kept the point of the needle for half a minute or so resting on the reclined lens to prevent it from rising, the surgeon now withdraws it a little slowly, still keeping the handle elevated, and watches for another half minute whether or not it is disposed to rise again. If not, he continues to withdraw the needle still in the same direction until it is quite free of the cataract and the vitreous humor immediately surrounding, when he depresses the handle, and then brings its point again into the pupil.

Withdrawing of the needle.—The cataract not rising, the needle, after another pause, is finally withdrawn from the eye. And this is done by drawing it out in a horizontal direction, until the middle of the curved head becomes engaged in the puncture of the cornea, when the handle is to be raised, so that the extreme point may be withdrawn at right angles to the place of puncturation, as it was introduced.

In this operation, care is to be taken that the pupillary margin of the iris is not caught by the needle, and during the reclination, that the lower pupillary margin of the iris be not pressed on.

In elastic reascension of the cataract, attempts at reclination should not be persisted in, but the plan of operation relinquished. In this case, laceration of the vitreous body and posterior capsule cannot be effected, as it can in reclination by sclerotic puncturation.

Reclination by corneal puncturation has not been found to answer so well as that by sclerotic puncturation, and therefore has fallen into disuse.

Bandaging and after-treatment.—The light fold of linen (p.

260), to hang over both eyes, is sufficient bandage. In other respects the same general management is to be adopted as above recommended after extraction.

Accidents attendant on the operation of reclination.—In the course of a few hours after the operation, vomiting sometimes occurs. Reascension of the lens may be thereby occasioned.

Acute internal inflammation of the eye is apt to be excited by the operation. Most frequently, however, the supervening inflammation is of a chronic character, ending in disorganization of the eye and loss of vision. The inflammation appears to be at first posterior internal, with exudation on the surface of the retina, and into the vitreous humor, but by-and-by extending to the anterior segment of the eye. It commences from four to eight days after the operation. When the operation is performed by corneal puncturation, corneitis and iritis are apt to be excited primarily. [For the reasons here presented in stating the liabilities attending the operations of displacement, they are justly considered unscientific and objectionable. See Hays' Lawrence, p. 723; Walton, Operat. Ophth. Surg. p. 448, Am. ed.; also Dixon, Diseases of the Eye, p. 314.]

DIVISION OF THE CATARACT.

The object of this operation is to lacerate the capsule, and divide the lens, so that the latter may be gradually dissolved and absorbed, and thus ultimately altogether removed from the eye.

Considered as an operation, this is the most simple of all those for cataract, both in performance and in the extent of injury necessarily inflicted on the eye.

Indications.—Division is indicated in:

Soft or fluid cataracts—the cataracts of most common occurrence in early life. To this head belongs congenital cataract. [The experience of Wills Hospital has abundantly shown that it may be properly resorted to in a much wider range of cases. It has been successfully performed on a large number of patients over sixty, and on many at a still more advanced age, even up to ninety,—but of course, in such instances, with more frequent disappointment in the result. Softness or fluidity need not be required, since moderately hard or tough cataracts present no serious impediment to the operation, especially when the knife-needle is used. According to Dr. Hays (Lawrence on the Eye, 1854, p. 726), the hardest lens may be cut up with the knife-needle which he employs.]

Prognosis.—In the cases proper for the operation, the prognosis is good. There is in general little reaction, but though the lens may be perfectly absorbed, the capsule, which does not admit of

solution and absorption, if not already opaque, may become so and form what is called *secondary capsular cataract.* To anticipate this, the anterior wall of the capsule should, during the first operation, be as completely cut up as possible at the part corresponding to the pupil. The rapidity with which solution and absorption go on, varies from a few days to several months. In general it may be said that in children the absorption proceeds more quickly than in adults.

One operation may suffice, but, generally, solution proceeding slowly, the operation requires to be repeated, and that more than once. This, as the operation is so simple and painless, is no great objection. The interval between the repetitions of the operation should be about six weeks.

It is best to operate on both eyes at the same time. I have observed the solution to proceed more quickly after the operation on both eyes at the same time, than after the operation on one eye only. When the eye becomes inflamed, solution appears to be arrested.

If the retina was previously quite sound, a perfect restoration of vision may be calculated on, if solution and absorption go on pretty quickly; if not, by the time the cataract disappears, the sensibility of the retina may be found impaired.

The operation of division may be performed either by sclerotic puncturation, or by corneal puncturation.

Division of the cataract by sclerotic puncturation.

The instrument best adapted for this operation is a curved lance-shaped needle. The pupil should be well dilated, and the patient, assistant, and operator placed as above recommended (p. 245).

Except making the breach in the vitreous humor, and substituting division of the cataract for displacement, all the steps above described for reclination by sclerotic puncturation may be followed in this operation, viz.—1st. Puncturation. 2d. Laceration of the posterior wall of the capsule and division of the lens from behind. 3d. Introduction of the needle into the posterior chamber, so that its lance-head is seen through the pupil. 4th. Laceration of the anterior wall of the capsule and division of the lens from the front, if a first operation on the eye; if it be a repetition of an operation, the further division of the lens is all that is required.

As generally performed, the operation does not comprehend laceration of the posterior wall of the capsule and division of the lens from behind, but simply laceration of the anterior wall of the capsule and division of the lens from the front.

In this case the *first step* comprehends the puncturation. The *second step*, the introduction of the needle into the posterior

chamber, so that its lance-head is seen through the pupil. The *third step*, the laceration of the anterior wall of the capsule and the division of the lens.

The anterior wall of the capsule is lacerated by directing the point of the curved lance-head of the needle against it, and by slight rotatory movements of the handle of the instrument making several vertical incisions in the part of it corresponding to the pupil. The capsule is then to be divided horizontally, by pressing one of the edges of the needle against it, which is done by slightly moving the handle of the instrument forwards.

Division of the lens.—Having thus freely divided the capsule, the surgeon turns the sharp point of the needle against the lens opposite the pupil, and by slight rotatory movements of the handle of the instrument, breaks up its substance; if the lens is firm enough, he shaves off pieces with the edge of the lance-head of the needle, its concavity being directed forwards, and spoons the detached fragments into the anterior chamber.

It is to be remembered, that it is better not to risk reaction by attempting too much at one time, in the way of breaking up the lens, but the capsule ought always to be freely lacerated at first. Especial care should be taken not to displace the whole lens, or even any considerable piece of it unbroken up.

The withdrawing of the needle from the eye is effected by a series of manœuvres, exactly the converse of those performed in introducing it, as above described (p. 273).

[The needle which has been chiefly and so successfully used at Wills Hospital, and is still preferred by Dr. Littell for most cases, is described by him in his edition of Walton (op. cit. p. 459). It is *fine* and *straight*, slightly conoidal in the shank, and not essentially different from Walton's own, "being about six-tenths of an inch in length, flattened and a little widened towards its extremity, with an angular point, and as sharp an edge as it can be made to receive;—the object being the laceration of the capsule and the division of the lens with as little disturbance as possible of their relations with surrounding parts." In accordance with this object, great care must be taken to avoid touching the iris or ciliary bodies or dislocating the lens. Nor are we inclined to throw any fragments into the anterior chamber. (See Walton, pp. 454, 455, and Hewson's Mackenzie, pp. 772, 773.) The straight needle just described will probably be found to be the safest, and, on the whole, a most effective, instrument for the reduction of soft, or moderately hard cataracts, especially in the hands of a young operator. In aged patients and hard cataracts, however, and whenever a rapid solution is particularly desirable, and a free division may be attempted without unusual risk, we should prefer the operation of Dr. Hays, and the

short iris-knife needle which he has been using for some years past, and has recently described a second time. (See Am. Journ. of Med. Sci. 1855, p. 82; also Hewson's Mackenzie, p. 774, and Hays' Lawrence, 1854, p. 726.) A "straight-edged" lens-knife is also recommended and delineated by Dr. John Neill (Med. Examiner for June, 1855, p. 332), as one which he had found in his experience to be the best adapted to the operation for solution.

We have tried various forms and sizes of the cutting needle, and have become satisfied that a great deal depends upon the delicacy of the blade, and the sharpness of its edge and point; but that its proper management requires great care and skill on the part of the operator to avoid dislocating the lens, or wounding the iris or other parts not necessarily involved. The best patterns that we have seen are those now made, according to the directions of Dr. Hays, by Kolbe, surgeons' instrument maker, of Philadelphia, and that of Dr. Neill, made by Mr. Gemrig, also of this city.

Dr. Hays describes his mode of operating as follows:—The patient, with his pupil well dilated, being placed recumbent on his back, at a convenient height on a table or a settee, with his head supported by a round hair pillow; the eyelids are separated and the eyeball is steadied in the usual way. "The point of puncturation of the sclerotica should be a line and a half or two lines from the temporal margin of the cornea, and in the line of its transverse diameter. The straight needle is introduced perpendicularly to the surface of the eyeball, the edges looking upwards and downwards. The puncturation should be made quickly, and the needle introduced only a short distance. This accomplished, the surgeon should steady the eye with the needle, and wait an instant until the patient has recovered from the shock. The direction of the needle should then be changed, so that its point may be advanced between the iris and the lens; when the instrument should be steadily pushed on until its point reaches the opposite pupillary margin of the iris. In executing this step, care must be taken not to wound the ciliary body or iris, on the one side, or to spit the lens on the needle. If the former accident happens, injurious inflammation may result; if the latter, especially if the lens be hard, it will probably be dislocated, and in this case it must be either at once depressed or extracted; the latter is the preferable alternative. When the needle is pushed into the lens without dislocating it, the instrument should be carefully withdrawn until the point is free, and then pushed on again in a better direction. This step being accomplished, the needle should be rotated, one quarter round its axis, so as to present its cutting edge towards and exactly over the diameter of the lens. This last direction is highly important, as the lens will thus offer the firmest resistance, and will not

tilt over and be dislocated in being cut. A free incision should then be made by withdrawing the needle a short distance, pressing firmly its edge against the cataract. If the lens is hard, several incisions should be made in the anterior capsule; and then this membrane freely lacerated cross-wise with the point of the instrument; this accomplished, the instrument should be withdrawn. The lens exposed to the aqueous humor will become softened, partly absorbed, and at a subsequent period the operation may be repeated, and the lens completely broken up.

"If the lens is not very hard, in addition to lacerating the anterior capsule, more or less of the anterior portion of the lens may be broken up and placed in the anterior chamber; and if the lens is sufficiently soft, the whole of it may be broken up at the first operation. We have often, by adopting the method pointed out, completely divided the cataract into halves by a single cut" (op. citat. p. 727). In conclusion, we may address a very important caveat to the inexperienced reader of the foregoing, in the language of its distinguished author. "To perform this operation well, requires skill, experience, coolness, and judgment. No one should attempt it, until he has studied well the relations of the parts involved, and has fully considered all the difficulties he may encounter, and is prepared to obviate them." (Idem. p. 726.)]

Division of the cataract by corneal puncturation.

The instrument with which the performance of this operation is most simple, is a straight needle, ground flat on the sides towards the point, so that as it penetrates the cornea, it fills completely the puncture, though not in a forced manner, and thus prevents the escape of aqueous humor.

Preparatory to this operation, the pupil should be well dilated by belladonna.

First step.—This comprehends the puncturation and the advance of the point of the needle through the dilated pupil towards the cataract.

Fig. 49.

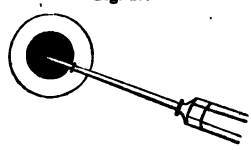

The point of the cornea where the needle is to be made to pierce, is about half way between its centre and its outer and lower margin.

The flat surfaces of the needle being the one towards the centre of the cornea, the other towards the margin, the point of the in-

strument is directed perpendicularly to the place above indicated, when it is to be made to pierce by a quick thrust, executed solely by the movements of the fingers. Having thus pierced the cornea, the handle of the instrument is depressed, and its point steadily pushed on towards the cataract, still by the movements of the fingers.

Second step.—This comprehends the laceration of the anterior capsule, if a first operation, or the breaking up of the lens if a repetition.

One of the edges of the instrument being directed against the capsule, one or more incisions are to be made in it from above and outwards, downwards and inwards, by a lever-movement of the handle of the needle.

The division of the lens is effected, so far as is proper, by similar incisions.

Withdrawing of the needle from the eye.—In doing this, the surfaces of the instrument are to be directed in the same way as when it was introduced.

On repeating the operation of division, it is usually found that the lens has become more brittle and more easily broken up into fragments than at the first operation.

Treatment and accidents after division.—The treatment after division, is the same in general as after displacement; except that the pupil is to be kept dilated.

Vomiting often occurs after division through the cornea, especially when the cataract is fluid, and may continue several hours. Opiates are to be given to relieve it.

Corneitis, aquo-capsulitis, and iritis are not unfrequently excited by corneal puncturation.

In cases of cataract complicated with extensive synechia posterior and contraction of the pupil, the consequence of iritis, the late Mr. Tyrrell recommended a modification of division by corneal puncturation, which he designated *drilling*.

He passed a very fine straight needle, of uniform thickness, somewhat obliquely through the cornea at the outer part; and then, directing the point towards the anterior capsule of the lens, close to the inner margin of the pupil (taking care not to injure the iris), and causing the instrument to penetrate the capsule, and enter the substance of the lens, to the extent of about one-sixteenth of an inch, he rotated the handle of the needle between the forefinger and thumb, so as to make the point act as a drill, and then withdrew the needle. An opening was thus secured more free than could be effected by a single puncture.

He usually had to repeat this operation seven or eight times at

intervals of from three to five weeks, taking care to puncture the opaque capsule in a fresh place at each operation, before the pupil was cleared.

The operation in no instance produced inflammation of any consequence, and did not confine the patient for more than two or three days.

In a few instances it was necessary to make an artificial pupil subsequently by incision with Maunoir's scissors. See *Artificial Pupil.*

Operation for cataract in infants.

Cataract not unfrequently occurs congenitally or supervenes shortly after birth. It is most commonly dotted, or central capsular, or central capsulo-lenticular. If limited to this small extent of opacity, no operation is called for. When, however, the opacity is obviously so extensive as to prevent objects being seen, it is advisable to operate.

The period after birth at which the operation should be performed, is before teething commences, or soon after it is completed (p. 239). A principal reason for performing the operation at so early a period is to obviate the occurrence of those irregular movements of the eyeballs, to be described below under the name of Oscillation and Nystagmus, which so often attend defective vision which has existed from birth or from an early period of life.

The operation for congenital cataract is division (p. 274, et seq.) by sclerotic puncturation. For the position and mode of securing the infant, see p. 245, or chloroform may be given.

Secondary cataract.

After the operation of extraction, some portion of the cataractous lens may remain obstructing the pupil, forming what is called secondary lenticular cataract. In such a case no interference is in general required, except keeping the pupil dilated by belladonna, the lenticular fragments being eventually absorbed. The posterior strata of the lens, both opaque and firm, sometimes remain adhering to the posterior wall of the capsule, and show little disposition to become absorbed. In such a case I have found it necessary to perform the operation of division some months after the extraction had been performed.

After the operation of division, the capsule is especially apt to become opaque and obstruct the pupil. This forms secondary *capsular* cataract.

Operation for secondary capsular cataract.—At the same time that the capsule becomes opaque, it is apt to become thickened and

very tough; it may not therefore be easy to divide it with the needle, so as to make an opening through it, opposite the pupil, but this should be first attempted; though the opaque capsule may often be detached in a mass, it does not admit readily of being depressed, as it always tends to rise again. This is owing to the resistance of the vitreous body, if sound, or if in a dissolved state to the opaque capsule being lighter than the fluid. In the former case, the opaque capsule should be extracted through a small section of the cornea, as above recommended for siliquose cataract; in the latter case, the capsule should be detached from below, and pushed upwards behind the iris, where it will float out of the way of vision. The same proceeding should be adopted in siliquose cataract, if there is reason to suppose that the vitreous body is in a state of dissolution.

Comparative advantages and disadvantages of extraction, displacement, and division.

By the operation of extraction, the cataract is removed wholly and at once from the eye, and very good vision restored; but the operation is a nice, if not a very difficult one, and liable to the occurrence of the various untoward circumstances above-mentioned, by which its success is readily marred.

The operation of displacement, which may be performed in the same cases as extraction, is neither so nice nor so difficult an operation, does not expose the eye to the same risk of immediate destruction, and though the cataract is apt to return to its former place, the operation may be repeated; but though displacement may have succeeded as an operation, and vision be restored, the eye is not so safe as after successful extraction, but, as above-mentioned (p. 274), is liable to become affected with internal inflammation, which ends in amaurosis.

Extraction thus possesses a decided advantage over displacement, and is therefore generally preferred, except when the unfavorable complications above-mentioned exist (p. 247).

The degree of softening of the vitreous body requisite to admit of safe displacement of the lens is not so great as to forbid extraction, but, of course, if, in the cases in which the vitreous body is so much dissolved, that the displaced lens is apt to float up again, displacement be contra-indicated, extraction is much more so.

All other things being equal, it might perhaps be laid down, as a general proposition, that in the very cases in which displacement admits of being most readily and safely performed, extraction is less safe, whilst, on the other hand, in the cases in which, in consequence of the soundness of the vitreous body, extraction is most safely and easily performed, displacement is least so.

As the cases for which division is best fitted are different from those in which extraction or displacement is indicated, there is no comparison to be made between them. It is, however, to be observed, that a combination of division and extraction has sometimes been had recourse to in cases of common lenticular cataract of old people. The object of this compound operation being that the lens may, by solution and absorption of its soft exterior part, be reduced to its hard nucleus, which, in consequence of its small size, will admit of being extracted through a small section of the cornea. This is a proceeding, however, not at all to be recommended. In any such case, where there is reason to dread making a larger section of the cornea, it is better not to extract at all, but divide the soft exterior of the lens and recline the nucleus.

In the case of a mad woman, about sixty years of age, on whom I could not venture to perform extraction, I divided the soft exterior of the lens and reclined the nucleus on both eyes at the same sitting, with good success, one repetition of the division being required. The operations were performed while the patient was under the influence of chloroform. [There are very few cases in which we should not be tempted to try the operation of division first, even if we were obliged, as in the contingency of a hard nucleus or a dislocated lens, to resort eventually to extraction. The operations of displacement are only justifiable, when neither of the others can be successfully performed. Even in combination with previous division of a soft exterior, we doubt whether displacement of the nucleus ought to be preferred to extraction, unless the latter were otherwise positively contra-indicated.]

Cataract glasses.

The difference in refractive power between the air and the cornea, being much greater than between the aqueous humor and crystalline body, the greatest amount of refraction which the rays of light undergo in the eye, in order that they may converge to foci on the retina, is that effected by the cornea on their first entrance. The crystalline body contributes comparatively little to the convergency. Hence, vision, after a successful operation for cataract, may be still *tolerably distinct* for objects at a certain distance. Still, in order that it may be *perfectly distinct*, the use of convex glasses is required.

But as with the loss of the crystalline body, there is loss of the faculty of the eye to adjust itself for different distances, except so far as variations in the size of the pupil contribute to this effect, glasses of different degrees of convexity are required, according as the patient wishes to view near or distant objects. Thus, convex

lenses of two and a half inches focus are generally required for reading, and lenses at four and a half inches focus for viewing distant objects.

Of course before fixing on any particular powers, the patient will try which suit him best, and the test which should guide him in his choice is, that when the spectacles are put on, or, if hand-glasses, when they are held immediately before the eyes, he sees objects distinctly at the same distance as he saw them before he became blind.

Recourse is not to be had to the use of cataract glasses until the eyes have perfectly recovered from the operation and have been so for some time,—say six months.

Section III.—Operations for Artificial Pupil.[1]

An artificial pupil is an opening made in the iris, to give passage to the rays of light, when the natural pupil is either covered by extensive central opacity of the cornea, with or without being contracted, or complicated with synechia; or when it is actually obliterated, with or without being complicated with opacity of the cornea or synechia, so that the rays of light can no longer be transmitted through it to the retina.

There are three principal modes of operating for artificial pupil which may be had recourse to, according to the nature of the case, viz., first, making the opening in the iris, by means of a simple incision or incisions—*the operation for artificial pupil by incision.* Second, making the opening by cutting out a piece of the iris—*the operation by excision.* Third, instead of actually making an opening in the iris, detaching the membrane at some part of its circumference from its ciliary connection—*the operation by separation.*

In some cases, the natural pupil admits of being so freed, as to be again available for the transmission of light to the retina. The operations by which this is effected, though not strictly operations for *artificial pupil,* are properly enough referred to the same head, as both in their performance and in their object they closely agree. The operations are:—First, the restoration to its natural position of the pupil dragged opposite a leucoma by partial anterior synechia, by means of *abscission of the band of adhesion.* Second, the *dislocation* of the natural pupil to opposite a clear part of the cornea.

In the cases in which an artificial pupil is required, the crys-

[1] Conformatio pupillæ artificialis—Coremorphosis—Coreplastice.

talline body may be healthy, or it may have been removed by a previous operation for cataract (of which operation the condition requiring the formation of an artificial pupil may be an effect), or it may be cataractous. In the first case, the crystalline must, if possible, be preserved untouched; in the last case, the operation for artificial pupil will require to be combined with that for cataract.

General conditions necessary, or at least favorable, to the success of operations for artificial pupil.

An operation for artificial pupil is not to be thought of unless the patient has lost *all useful vision with both eyes;* and then, only when there is reasonable evidence that the retina is still sound.

Before the operation is undertaken, the eye must have quite recovered from the inflammation which has been the cause, or been co-existent with the cause of the altered state of the eye requiring the operation.

Besides being free from inflammation, the eye should be otherwise tolerably healthy, at least free from granular conjunctiva, vascular cornea, varicosity, unnatural hardness or softness, dropsy, atrophy, &c. If there is dissolution of the vitreous body, operations through the cornea, like extraction of cataract under the same circumstances, require to be performed with extreme caution, or they may be altogether forbidden. If the inflammation which has caused the state of the eye requiring the artificial pupil has been scrofulous in a child, no operation should in general be attempted, until after puberty.

Prognosis of the operation for artificial pupil. As the eye has in general already suffered so much from inflammation, this process is apt to be re-excited to such a degree as to occasion failure of the operation, or even complete destruction of the eye. Inflammation is especially prone to supervene if that which caused the state of the eye requiring the artificial pupil had been scrofulous, syphilitic, or gouty. The most promising cases are those in which the condition of the eye requiring the operation, is of traumatic origin, as after operations for cataract, or has been occasioned by purulent ophthalmia.

The amount of vision restored by the operation, depends upon the previous state of the eye, and the mode of operating, which that state permitted to be adopted, together with the degree of reaction which follows the operation. The same good vision is seldom or never restored by the operation for artificial pupil, as by the operation for cataract; indeed it may in general be considered *success*, if by means of an operation for artificial pupil, sufficient vision be restored, to enable the person to move about by himself, and read a little.

Preparation of the patient for the operation of artificial pupil.—In addition to the same general treatment above laid down for the operation for cataract, in order to get the patient into as good a state of general health as possible, the preparation for undergoing the operation for artificial pupil should consist in bringing the eye into the favorable condition above-mentioned.

Place of the iris where the artificial pupil should be made.—The artificial pupil should be made, 1st, as near the middle as circumstances of the case will allow; 2d, after the middle, the nasal or temporal side is the next best place; then the lower, and lastly, the upper.

Position of the patient, assistants, and operator.—This should be the same in general as above recommended for the operations for cataract in general (p. 244 et seq.)

The *securing of the eyelids* also is to be effected in the same way as above recommended (p. 245 et seq.)

ARTIFICIAL PUPIL BY INCISION.[1]

There are two principal ways of operating for artificial pupil by incision, viz., through the sclerotica, and through the cornea. An important condition for the success of incision performed either way is, that the larger circle of the iris be still in a healthy state, as regards intimate structure and contractile endowments, so that the opening made in it may, by its retraction, come to gape, and the edges of the incision thus be prevented from reuniting.

In the cases which may be the subject of the operation of incision, the closure of the pupil may have been the consequence of iritis succeeding an operation for cataract. If the lens is still present but cataractous, it must be divided or displaced in the operation through the sclerotica, extracted if possible, in the operation through the cornea. The same must also be done even if the lens be quite healthy, as wounding it, which would of course be followed by opacity, cannot be avoided in the operation for artificial pupil by incision. It is, however, to be remarked, that if the lens be still clear, some other operation than incision, must, if possible, be chosen, by which the lens may be preserved untouched.

Incision through the sclerotica.[2]

In this operation, a single incision is made through the iris in a

[1] Iridotomy.

[2] Cheselden's operation for artificial pupil. This was the first operation performed for artificial pupil. The two cases in which Cheselden operated, were cases of closed pupil, after the operation for cataract, by couching.—Philosophical Transactions, vol. xxxv. An. 1728.

Fig. 51.

transverse direction, above or below the situation of the natural pupil. The radiating fibres being thus cut across, the edges of the incision retract, and a fusiform opening is the result. The cases in which this succeeds best, are those in which the closure of the pupil is owing to the iris having been prolapsed through a wound or large ulcerated opening of the cornea, and is thus on the stretch. It will also succeed in simple closed pupil, provided, as above said, the substance of the larger circle of the iris is still quite healthy. There should be a sufficiency of clear cornea opposite the place where the incision of the iris is made.

Fig. 50.

The instrument for incision through the sclerotica.—The instrument used for this purpose, and known under the name of Adams' iris knife, has a blade about nine-tenths of an inch long, about one-twentieth of an inch broad, single-edged, and sharp, but somewhat bellied at the point. (Fig. 51.)

The operation comprehends the following steps:

First step—Puncturation.—The point of puncturation is the same as in the operation of reclination of cataract, viz., three-twentieths of an inch from the temporal margin of the cornea, and in the line of its transverse diameter.

The operator holds the knife, like the straight cataract needle in reclination, its surfaces upwards and downwards, its cutting edge backwards, and rests his hand by the little finger, on the patient's cheek, in such a way that the blade of the knife is close in front of the cornea, in a line corresponding to its transverse diameter, and the point extending to nearly opposite the nasal margin. The hand being thus disposed, the thumb and fingers holding the knife are retracted, in order that the point may be applied perpendicularly to the surface of the eyeball, at the place above-mentioned, when it is to be steadily thrust towards the centre of the eyeball, but no deeper than one-eighth of an inch.

Second step.—The handle of the knife is now to be inclined *very much back towards the temple*, more than in the operation for cataract, in order that the point of the knife, when pushed on may come to pierce the iris from behind, near its temporal margin, say one-tenth of an inch from it, and appear in the anterior chamber. This being effected, the handle of the knife is now to be inclined forwards a little, so that when the knife is pushed further on, its

point may pass across the anterior chamber, towards its nasal side (Fig. 52).

Fig. 52.

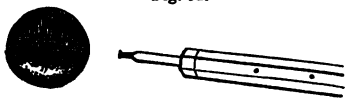

Third step—Incision of the iris.—By now inclining the knife still more forwards, so that its edge may be fairly applied against the iris, and then by withdrawing it somewhat, it is made to cut the iris. If by this first stroke the incision of the iris is not sufficiently large, the knife is to be again pushed on and again withdrawn, its edge being still kept fairly directed against the part of the iris to be cut. This is to be repeated until a sufficiently large incision, at least one-fifth of an inch, has been made. By the contraction of the iris, previously on the stretch, this incision immediately gapes, and that to a considerable degree, and so the fusiform pupil is made.

Incision of the iris being effected, the lens, if still present, must, whether clear (p. 285) or cataractous and soft, be divided, in order to its removal by solution and absorption; if cataractous and hard, it should be displaced.

In this step of the operation, it may happen, especially if the edge of the knife is unduly pressed back against the iris, that the iris becomes detached from its ciliary connection at some point, most frequently at the nasal side. This will impede the completion of the incision to the proper size. The aperture left by the separation may continue open, especially if the iris is healthy in its texture, but more frequently it will close from supervening inflammation. In such a case, incision, or some other operation through the cornea, may be subsequently had recourse to.

Incision through the cornea.

The particular modification of this operation usually adopted, is that of Janin, as improved on by Maunoir. It consists in making a small section of the cornea, at its lower and outer or its lower part, and by means of Maunoir's scissors, introduced through the opening, dividing the iris by two incisions, divaricating from the situation of the natural pupil (Fig. 53). By this both the circular and radiating fibre of the iris are divided. Modifying this plan, which cannot always be followed, Dr. Mackenzie cuts the radiating fibres only, making the incisions divaricate from a point near the margin of the iris (Fig. 54). In either case, the result of the two incisions is a triangular flap of iris, which contracts and shrivels, so as to leave a free opening. (Figs. 55, 56.)

The two incisions in this operation are made when the iris is not on the stretch, and when there is reason to suppose that the sub-

stance of the iris is not so healthy as to contract sufficiently to cause a single incision to gape, and thus to form a pupil which shall remain permanently open.

Fig. 53.

Fig. 54.

Fig. 55.

Fig. 56.

If the iris were healthy and stretched enough, so that there was reason to suppose that a single incision would gape sufficiently, the operation through the sclerotica, is to be preferred,—except when it is intended to extract the lens at the same time, whether cataractous or still clear, or when the circumstances of the case require that the incision for the new pupil should be vertical, as Janin made it, instead of horizontal; it not being easy to make a vertical incision in the iris by the operation through the sclerotica. When a single vertical incision is made, it should be on one or other side of the centre of the iris, in order that the radiating fibres may be cut across.

Fig. 57.

The instruments required for the operation are an extraction knife and a pair of Maunoir's scissors. The other instruments employed in extraction should also be ready (p. 248).

Maunoir's scissors are extremely fine, when closed not so thick as a common probe, bent sideways at an obtuse angle, the blade corresponding to the convexity, sharp at the point for piercing the iris, the other blade probe-pointed, that it

may admit of being easily and safely pushed through the anterior chamber.

The operation comprehends the following steps:

First step—Section of the cornea.—This is to be made at the outer and lower part or the lower part of the cornea, as for extraction of the cataract, but to the extent only of about one-fourth of the circumference of the cornea, unless it is contemplated to extract the lens or an opaque capsule, when the section should be to the extent of one-third of the circumference.

Second step—Introduction of the scissors and incision of the iris.—The surgeon introduces the scissors closed under the flap of the cornea, and when the point has arrived at that part of the iris where the incision is to be commenced—the situation of the natural pupil or near the margin of the iris, according to circumstances—he opens them, thrusts the sharp-pointed blade through the iris, and pushes them on,—the sharp-pointed blade through the posterior chamber, the probe-pointed blade through the anterior chamber, the iris between them, to the opposite part of the margin of the iris, where the incision is to terminate. By now closing the scissors, which should be done sharply, the iris interposed between the blades is cut.

The second incision is now to be made, commencing at the same point as the first, but divaricating from it (Figs. 53, 54). For this purpose the scissors, still kept closed, are to be withdrawn and re-introduced in the direction in which it is proposed to make the second incision. When the point of the scissors is now opposite the commencement of the incision which has just been made, the sharp-pointed blade is passed behind the iris, and the scissors pushed on, then closed, and the incision made as before.

An additional step which may be called for is, extraction of the lens, if present, or of an opaque capsule.[1]

ARTIFICIAL PUPIL BY EXCISION.[2]

There are two principal plans of excision, viz., that of Beer and Gibson, or lateral excision, and that of the first Wenzel, or central excision.

Lateral excision is the more important, as it is applicable to cases in which the lens is transparent, and in which it may and ought to be preserved so.

Central excision is applicable only in cases of closed pupil occurring after the operation for cataract, or combined with cataract.

[1] If after the section of the cornea is made, the iris should protrude, advantage is to be taken of this to make a pupil by excision rather than by incision.

[2] Iridectomy.

Lateral excision.

Lateral excision is performed by making a small section of the cornea at some convenient part of its circumference, seizing with a forceps the piece of iris which protrudes, and snipping it off, taking care to include the pupillary margin of that part of the iris. If the iris does not protrude spontaneously, the portion to be snipped off is drawn out with a blunt hook or the forceps, care being taken not to injure the crystalline body.

The cases in which lateral excision is applicable are cases of central opacity of the cornea, to such an extent as to cover the pupil, even when dilated by belladonna, in which the iris and pupil are either natural, or the former but partially adherent to the cornea, and the latter partially contracted;—the lens being still clear.

The conditions necessary for lateral excision are:—1st, a sufficient extent of clear cornea at that part of its circumference, near where the pupil is to be made, to allow for any opacity which may result from the cicatrice of the corneal incision, and that enough of clear cornea may remain opposite the new pupil; 2d, the iris sufficiently free from adhesions to admit of a portion of it protruding or being drawn out through the corneal incision, in order to be excised.

The eyelids are secured in the same way as in the operation for cataract, during the first step or section of the cornea, but during the second step, or excision of the piece of iris, both eyelids must be secured by the assistant, or one eyelid by one assistant, the other by another, as the operator requires to use both hands.

The instruments required for the operation are:

1. A cataract knife for making a small section of the cornea.
2. A fine forceps, Fig. 58, for drawing out the piece of iris to be excised, if the iris does not protrude spontaneously; if it does, the forceps are used for laying hold of it.
3. A pair of curved scissors for snipping off the piece of iris, Fig. 59, p. 292.

Lateral excision comprehends the following steps:

First step—Puncture or section of the cornea.—This is to be made close to the sclerotica, and to the extent of one-fourth of the circumference of the cornea.

Second step—Excision of the piece of iris.—The gush of aqueous humor which takes place on completing the section of the cornea will perhaps cause prolapsus of the iris.

The operator, leaving the eyelids in charge of his assistant or assistants, exchanges the knife for the fine forceps, and takes the curved scissors in the other hand, holding them in the manner represented in Figure 59 (next page), the thumb in one ring, the ring finger in the other, the point of the fore finger on the joint, the middle finger on the branch in the ring of which the ring finger is, with their convexity towards the eye, ready for use.

Fig. 58.

If prolapsus of the iris has already spontaneously taken place, it is seized with the forceps, raised up, and a portion, including the pupillary margin, snipt off. If the prolapsus has not taken place, and cannot be made to do so by gentle pressure, the operator carefully introduces the forceps, lays hold of the iris very cautiously at a little distance from the pupillary margin—close to the junction of the larger with the smaller circle of the iris, draws it out, and snips it off.

The size of the new pupil should be at least equal to that of the natural pupil in its middle state. As to the quantity of iris to be cut off, in order to obtain a new pupil of this size, it is to be remembered that if the structure of the iris is healthy, even when but a small piece is snipt off, the aperture which results will be of considerable size.

What of the iris may remain protruding is to be gently pressed back with the curette. The eyelids are then to be closed, rubbed over the cornea, and suddenly opened to the light.

A man of about twenty-five years of age, had extensive opacity of the centre of the cornea of both eyes in consequence of gonorrhœal ophthalmía. The pupil, while of its medium width, was covered by the opacity, but when dilated by belladonna or atropia, its circumference extended slightly beyond the densest part of the opacity, so that the patient was able to see objects, though very indistinctly, and to make his way in the street.

Seeing that there was no hope of any further clearing away of the opacities, I resolved to perform the operation for artificial pupil by lateral excision.

The left eye was first operated on. The upper eyelid having been secured by an assistant, I made, with a cataract knife, a section of the cornea to the extent of a quarter of an inch at its inner and lower margin. Immediately on this being completed the aqueous humor escaped, and the adjacent part of the iris became prolapsed.

The eyelids were now allowed to close, while the aqueous humor at the inner corner and on the cheek was wiped away with small

Fig. 59.

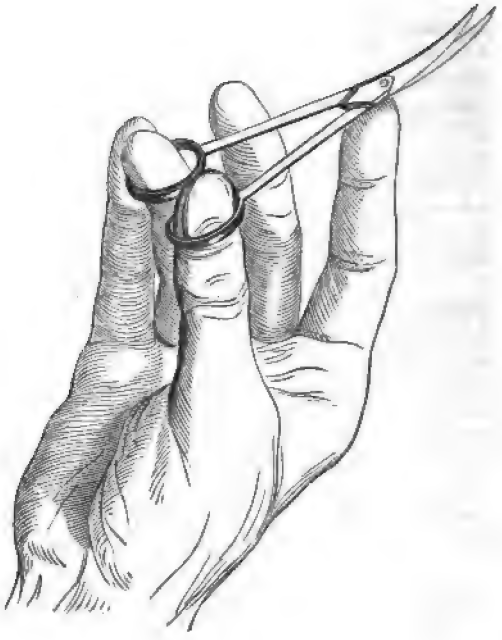

pieces of lint. The eyelids were then again opened, and the one secured by one assistant and the other by another, whereupon I seized the protruding portion of iris with a pin hook pointed forceps and snipped it off, taking care to include the pupillary edge. The eyelids were then allowed to close again. After about a minute, the upper eyelid was gently rubbed over the cornea, and then suddenly opened to the light. A sufficiently good pupil having been obtained, no more of the iris now protruding, and the edges of the corneal wound being in apposition, the lids were finally closed and retained by a narrow slip of plaster.

A week after this operation, the healing process having gone on most favorably, I considered it advisable to operate on the right eye. The operation was performed exactly in the same manner as

on the left eye. A fortnight after the patient was convalescent and able to make out large printed words by the aid of convex glasses six inches focus.

The sight has gone on improving so that he can see to read and write a little with the help of spectacles.

Figure 60 represents one of the eyes.

Fig. 60.

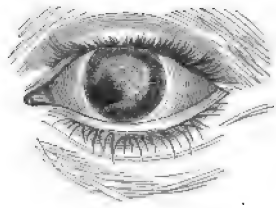

Central excision.

As performed by Wenzel, this consisted, 1st, in making a half section of the cornea as for extraction, with the additional manœuvre of so puncturing and counter-puncturing the iris with the point of the knife in its passage through the anterior chamber, that in the act of cutting out, a semicircular flap of the iris was formed. This flap of the iris was then cut off with a small pair of

Fig. 61.

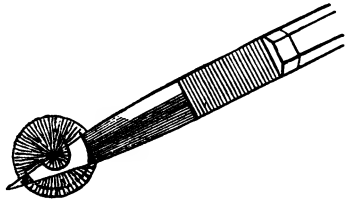

scissors, introduced through the incision of the cornea. If cataract existed, it was extracted at the same time.

The cases in which Wenzel thus operated, were cases of closed pupil, the lens either having been previously removed by operation or still remaining but cataractous. Of the operation, however, it is to be observed, that not more is effected by it than is or may be by Maunoir's operation by incision, in which the section of the cornea is much smaller. Hence Maunoir's operation is preferable.

ARTIFICIAL PUPIL BY SEPARATION.[1]

This operation consists in detaching the iris from its ciliary

[1] Iridodialysis.

Fig. 62.

connection at some convenient part, and drawing it aside, so as to provide a passage for the light. It may be performed through the sclerotica or through the cornea. Performed through the cornea, as it now always is, the lens, if clear, may be preserved so.

Separation through the cornea.

When the iris is in a healthy state, an opening made by separation, may remain permanent, in consequence of the contraction of the iris, as is shown in cases of accident, in which, by a smart stroke on the eye, the iris has been detached at some part of its ciliary connection. But in the cases in which separation is designedly had recourse to for the purpose of making an artificial pupil, the permanency of the opening cannot in general be calculated on, in consequence of alterations in the structure of the iris, produced by the disease which occasioned the necessity for the artificial pupil.

In order, therefore, to insure the permanency of a new pupil made by separation, the ciliary margin of the detached portion of iris is drawn out through the puncture of the cornea by which the detaching instrument was introduced, and either left there to be united in the cicatrice or cut off.

Cases in which separation is applicable.—Separation is applicable in all cases, but as it is not so good an operation as excision or incision, it is had recourse to in those only in which these two modes of operating are inadmissible. The cases are:

1st. Such extensive central opacity of the cornea, that the clear circumferential part is too small to admit of being encroached on by the opacity which might result from the cicatrice of an incision made for lateral excision.

In the case now mentioned, the iris and its connections being natural, separation is more easy and more successful than in the cases next to be mentioned, and, although the new pupil might remain permanent without strangulating the detached portion of iris in the puncture of the cornea, or cutting it off, it is nevertheless proper, for the sake of certainty, to add the one or other of these acts to the simple separation.

2d. Extensive central opacity of the cornea and adhesion of the pupillary margin of the iris to it, in which, in consequence of the narrowness of the circumferential portion of cornea remaining clear, the opacity of a cicatrice cannot be risked for Maunoir's operation, and in which not even incision through the sclerotica promises anything, in consequence of the morbid state of iris behind the clear part of the cornea, or in consequence of the situation of that part;

or when, although incision might be otherwise admissible, the lens is clear, and it is desirable to preserve it so.

As considerable pain attends separation, the assistant must secure the head well, to prevent any sudden movement by which the operator might be made to detach more of the iris than necessary.

Instruments for the operation:

1. Jaeger's keratome, Fig. 63, or Beer's cataract knife.

2. A simple hook,[1] Fig. 64.

The steps of the operation are:

1st. Puncture of the cornea by which to introduce the hook.

2d. Introduction of the hook, through the puncture of the cornea, into the anterior chamber.

3d. Hooking and detachment of part of the iris. And,

4th. Prolapsus of it through the corneal puncture.

Puncture of the cornea.—This should be about one-tenth of an inch in length; the place where it should be made, which is an important point to determine, depends principally on the part of the iris to be detached, but in some measure also on the state of the cornea, for the incision ought, if possible, to be made at a part of the cornea where there is no adhesion of the iris.

The opening in the cornea is made by simple puncturation with the keratome or cataract knife, but, at the same time, care is to be taken to make the opening as wide within as without, otherwise the prolapsed piece of iris will not be so readily retained. Another precaution should be to let as little of the aqueous humor escape as possible.

Introduction of the hook.—Having made the incision in the cornea, the operator lays aside the knife for the hook. This he holds

Fig. 63. Fig. 64.

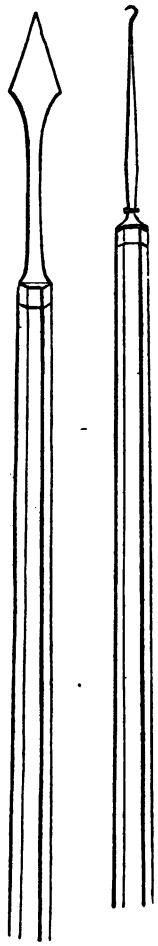

[1] Instead of a simple hook, various complex instruments have been invented and recommended. Of these the principal are:

Reisinger's *double hook.*—This is composed of two delicate hooks, united like the branches of a forceps, and so corresponding with each other in size and direction, that when the instrument is closed like a forceps, the two hooks form but a single one. The instru-

like a cataract needle, and introduces the hook, convexity foremost, and flatways, through the opening in the cornea, and in the direction of its axis, into the anterior chamber. The hook being fairly in the anterior chamber, the handle of the instrument is to be inclined so far backwards, that its blade may come to be parallel between the iris and cornea. This being arranged, the instrument is to be pushed on through the anterior chamber, the sharp point of the hook being, if anything, rather towards the iris than the cornea, to the ciliary circumference of the part of the iris to be detached. Before attaining this point, a little of the extremity of the hook disappears behind the margin of the sclerotica.

Hooking and detachment of part of the iris.—Having thus gained the ciliary circumference of the iris, the handle of the instrument is to be so far rotated and inclined, that the point of the hook may be directed fairly against the iris, and fixed into it, and that as close to the ciliary circumference as possible.

The iris being hooked, the instrument is to be rotated and inclined, so that it may be brought back to the position it was in before the iris was hooked. A steady and sustained, but gentle pull or two is now to be made, until the iris begins to separate. When this takes place the instrument is to be rotated half on its axis, so that the iris may be the more securely hooked. If this manœuvre be attempted before separation has commenced, the iris, being often diminished in the cohesion of its texture, will only be torn, and the hold of it by the hook altogether lost. By now continuing to pull the instrument slowly and steadily, separation goes on.

Prolapse of the separated portion of the iris through the corneal incision.—When the hook arrives with the hooked part of the

ment thus admits of being used, not only as a double hook, or as a single hook, but as a forceps.

GRAEFE'S *coreoncion*.—This consisted originally of a simple hook, provided with a guard which could be slid towards its point, or withdrawn from it, by means of a ferrule on the handle. At the opposite end of the instrument, there was a small knife for making the opening in the cornea. Graefe afterwards changed the simple hook for a double one made of hardened gold. He also added a spring by which the guard could be carried towards the point of the double hook, which was at the same time closed.

SCHLAGINTWEIT'S *iriankistron*.—This is an instrument very similar to Graefe's simple *coreoncion*, the principal difference being, that in the former the guard is received by the concavity of the hook, whereas in the latter it meets the point

LANGENBECK'S *coreoncion*.—This consists of a silver tube, like a pencil case, which serves as the handle, and fixed to one end of it a fine gold tube about one inch and a quarter long. A steel wire, terminating in a fine hook, is enclosed within the gold tube, and being fixed within the handle of the instrument somewhat as a pencil is in a pencil case, it admits of being protruded by touching a knob on the side of the handle. By means of a spiral spring within the handle, it is again drawn back. In this closed state the concavity of the hook is received by the edge of the golden tube, and its point thus kept so guarded that it is not apt to catch or wound any part by accident.

It is to be remarked that these and analogous instruments, called by different names, are quite unnecessary to the dexterous surgeon, and in the hands of an awkward person, are not so manageable as the simple hook or forceps.

It is unnecessary to give figures of the instruments.

iris at the puncture in the cornea, some nice manipulation is required to bring it out without letting the iris slip away. The essential point is to press back the lip of the corneal puncture, which is behind the blade of the hook, in order to make the puncture gape.

As much of the iris at least is to be prolapsed as will suffice to secure its retention in the corneal wound, and as much more as may be necessary to make the new pupil of proper size. In order to the retention of the prolapsed iris, it is to be drawn to one or other end of the puncture, and jammed there between its lips.

If it be necessary, in order to obtain a proper sized pupil, to draw more of the iris out than is actually necessary for its being

Fig. 65.

retained in the corneal incision, the superabundant part should be cut off. This may happen when the state of the eye has rendered it necessary to make the incision of the cornea nearer the margin where the new pupil is to be, than was above indicated.

When the prolapsed iris cannot be retained between the lips of the corneal incision, somewhat more should be drawn out, and the whole cut off (*Iridect omedialysis*).

During the detachment of the iris a considerable effusion of blood generally takes place into the aqueous chambers.

As the pain is very great, an opiate should be given to the patient after the operation.

If the case in which separation is had recourse to, be complicated with cataract, division or displacement may, according to the nature of the cataract, be performed after recovery of the eye from the separation. Extraction is not admissible; the state of the eye, which rendered it necessary to have recourse to separation, being in general such as to forbid extraction.

OPERATIONS FOR AGAIN RENDERING THE NATURAL PUPIL AVAILABLE.

Restoration of the pupil to its natural position by abscission.

If the pupil is dragged by a small synechia anterior, from its natural situation to opposite an opaque part of the cornea, and if it

appears that were the adhesion destroyed, the pupil would come to be opposite a clear part of the cornea, the operation to be adopted is simply the abscission of the adhesion. This is effected by means of a needle cutting on the edges and increasing in thickness. It is passed through the cornea into the anterior chamber slantingly, in order that the aqueous humor may not escape, and the adhesions cut. In doing this, great care should be taken not to injure the lens. Injury to the lens may be readily avoided if the aqueous humor has not been allowed to escape, but not easily if this accident has occurred.

Dislocation of the pupil to opposite a clear part of the cornea.[1]

This is effected by prolapsing a portion of the iris through a puncture of the cornea, and so dragging the pupil away from the opaque middle part to opposite the still clear circumferential part of the cornea. The puncture of the cornea is made with an iris knife, or the point of a cataract knife, close to the sclerotica, and should be about one-tenth of an inch in extent. If the iris is not prolapsed by the gush of aqueous humor, it may be so by means of the fine forceps (Fig. 58); or a blunt hook is introduced through the puncture, the iris caught by its pupillary margin drawn out. The prolapsed portion of iris is left strangulated in the opening of the cornea, in order that it may become adherent in the cicatrice.

This operation, it will be observed, comprises all the steps of lateral excision, save the cutting away of the prolapsed portion of iris. Now as there is no advantage in thus stopping short, but on the contrary, lateral excision at once is preferable to dislocation.

[Dr. Hays briefly describes his "operation by distortion" in a note, which we here extract from the former edition of this work: "We have performed this operation by another, and, we conceive, preferable method. This consists in puncturing the cornea with a cataract knife, and then incising that coat to the extent of one-sixth or one-fourth of its circumference, by a rapid cut, so as to cause the sudden evacuation of the aqueous humor. With the gush of this fluid the iris is prolapsed and is strangulated in the wound. If the cataract knife be properly constructed and the incision in the cornea be skilfully made, this operation will rarely fail, and the danger of wounding the capsule of the lens, with the hook, is obviated." (Lawrence on the Eye, last ed. p. 494.)]

Treatment after operations for artificial pupil.—This should be the same in general as after operations for cataract. The patient is to be kept in bed, his eyes protected from the light, and the antiphlogistic regimen observed. According to the form and severity of inflammation, which may supervene, so must be the treatment.

[1] Operations of Adams and Himly.

If the lens has been removed, the patient will, of course, require cataract glasses, when he comes to use the eye. Even when the lens is still present, as after lateral excision on account of central opacity of the cornea, convex glasses, of as high a power as cataract glasses, may be required.

In cases in which the lens is still clear, and the pupillary margin of the iris is adherent to the cornea to a greater extent, Tyrrell's hook (Fig. 66) may be introduced into the anterior chamber through a small incision in the cornea, and the iris cautiously hooked by its pupillary margin, and torn by dragging it in withdrawing the instrument.

Fig. 66.

In cases, again, in which the pupillary margin of the iris is wholly adherent to the cornea, and if the new pupil admits of being placed opposite the lower and outer part of the cornea, then such a mode of operating as the following, which was recommended by Mr. Tyrrell, may be adopted. He introduced his broad needle, cutting on each edge to the extent of one-fifth of an inch, through the margin of the cornea into the anterior chamber, and pierced with it the iris close to its adhesion to the cornea, being careful not to pass the point of the instrument backward, for fear of wounding the capsule of the lens. Having thus made a very small opening in the iris with the needle, he withdrew it, and then passed the blunt hook into the anterior chamber, and hooked the iris through the opening previously made in it, and gently withdrew the instrument. In doing this, the iris was usually torn from the point caught with the hook, and such a quantity of the membrane brought through the opening in the cornea by the hook as effected a sufficient aperture in the iris; but sometimes only a fissure resulted. Under such circumstances, Mr. Tyrrell made, after the eye had recovered from the first operation, a second opening through the cornea, a little above the centre, and seizing the upper margin of the fissure in the iris with the hook, he drew it to and through the puncture of the cornea, and thus formed a triangular-shaped opening in the iris. "The principal risk in these cases," he remarks, "arises from being obliged to use a pointed instrument to effect an opening in the iris, to permit the passage of the hook, the proximity of the capsule of the lens being so close to the iris, that it is easily injured, when cataract follows."[1]

[1] Practical Work, &c., vol. ii. p. 511.

INDEX OF THE DIFFERENT MORBID STATES OF THE EYE, IN WHICH VISION MAY BE RESTORED BY THE OPERATION FOR ARTIFICIAL PUPIL, AND OF THE PLAN OF OPERATING, OR MODIFICATION OF IT ADAPTED TO EACH PARTICULAR STATE.

In the above description of the different methods of performing the operation for artificial pupil, the different morbid states of the eye in which they are respectively applicable, have been mentioned. Here, it will now be useful to classify the morbid states, and indicate the plan of operation applicable for each species.

GENUS I.—OF MORBID STATES OF THE EYE.

Cornea principally affected.—The iris and pupil either natural, or the iris, otherwise healthy in structure, adherent to the cornea, to the degree either of synechia anterior or partial staphyloma, the pupil being more or less dragged and contracted. The lens and capsule sound, or the lens not present.

SPECIES OF MORBID STATES.	PLAN OF OPERATION.
Central incurable opacity of the cornea, of such a size as to cover the pupil, even when dilated by belladonna; iris and pupil quite natural; lens sound.	Lateral excision, where there is the greatest extent of clear cornea.
The opacity of the cornea not so extensive, but contraction of the pupil to a greater or less degree, and dragging of it behind the opaque part of the cornea, in consequence of synechia anterior or partial staphyloma; the lens sound.	Reduction of pupil to its natural situation by abscission, if the synechia be small and appears likely to admit of being readily divided. Otherwise, excision of prolapsed iris through section of cornea.
Cases in which the pupillary margin of the iris is adherent to the cornea either wholly or to a considerable extent; the iris, otherwise sound in structure, but much on the stretch.	Incision through the sclerotica, if the lens be no longer present. If on the contrary the lens be still present and sound, and if there be a sufficient extent of clear cornea, lateral excision may be adopted in the following manner:—Having made a section of the cornea, the fine forceps is to be introduced, and the iris laid hold of by a fold either dragged out, or torn and dragged out, and cut off.

GENUS II.—OF MORBID STATES OF THE EYE.

Iris and pupil affected, cornea sound, lens clear or opaque.

SPECIES OF MORBID STATES.	PLAN OF OPERATION.
Simple closure of the pupil from iritis, the lens and capsule supposed to be clear.	Excision of prolapsed iris through section of cornea half way between centre and circumference; if not separation.

SPECIES OF MORBID STATES.	PLAN OF OPERATION.
Closure of the pupil with cataractous lens, and posterior synechia.	If the substance of the iris appears to be healthy, and likely to contract when cut, so as to cause the incision to gape; and if the lens be soft, and fitted for division, incision through the sclerotica with division of the lens. If the lens be hard, and requiring extraction, it will be advisable to perform Maunoir's operation by incision, and extract the cataract through the opening. If the iris is not healthy, separation and subsequent displacement of the cataract, or excision with extraction, may be had recourse to.
Closure of the pupil, after the removal of a cataract.	This was the kind of case in which Cheselden performed his operation by incision, through the sclerotica; and if the texture of the iris has remained tolerably sound, the operation will in general succeed. If the texture of the iris, though not much altered, still appears to have suffered somewhat, it may be advisable to try Maunoir's operation by incision, rather than Cheselden's; but if the texture of the iris be decidedly altered, then excision, or separation must be had recourse to.
Partial opacity of the cornea, closed pupil, synechia anterior or posterior, and cataract. This is a combination of all the morbid states above enumerated.	Except in so far as the situation and extent of the clear part of the cornea on the one hand, and the state of the iris on the other, in such cases, necessitates a modification of plan in operating, what has been said in the preceding paragraphs is here applicable.

Section IV.—Congenital Defects of the Iris and Pupil.

Congenital absence of the iris.[1]

The whole iris may be congenitally absent, or there may be still some trace of it (*complete or incomplete congenital absence of the iris*).

There is a uniform dark, though not the jet black appearance, behind the cornea, but when the light falls upon the eye in a certain direction, a dark red reflection from its bottom is observed.

[1] Irideremia congenita.

Both eyes have generally been found to suffer from the congenital defect; which in some cases has been complete in the one and incomplete in the other.

Persons affected with absence of the iris, do not bear exposure to strong light well, and their vision is imperfect; but by their habit of keeping the eyebrows depressed and the eyelids half-closed, their eyes are somewhat protected from the too great influx of light, and their vision at the same time rendered more distinct.

The eyes may be in other respects perfectly formed, or they may be the subjects of additional malformations.

Cataract in general, sooner or later forms; sometimes it already existed congenitally. It often appears tremulous.

Though cataract exists, the vision is still in some degree retained, as the rays of light find a passage to the retina through the *zonula lucida*, which is seen around the circumference of the opaque lens.

In consequence of injury, the greater part of the iris may be detached from its ciliary connection, in which case it shrinks to a small size, and the eye thus comes to appear as if there was incomplete absence of the iris.

Treatment.—The only thing that can be done for cases of congenital absence of the iris, is to wear over the eyes, in the manner of spectacles, arched plates of black horn or the like, having transverse slits in them to see through, analogous to the snow-eyes of the Esquimaux. If the state of vision require it, concave or convex glasses may be fitted into the slits.

When cataract has formed, and if an operation should be thought advisable, division is the mode of operating to be adopted.

In partial irideremia, the pupillary circle is the part incompletely developed.

Congenital fissure of the iris.[1]

The fissure extends from the pupil towards the ciliary circumference of the iris, and its direction is almost constantly downwards.

In some cases the cleft contracts along with the pupil, though slowly; in other cases, the power of contraction appears to be confined to the pupil.

Vision is in general unimpaired.

The fissure usually becomes narrow in approaching the ciliary circumference of the iris, but in some instances the opposite disposition has presented itself. In some cases the fissure has been found to implicate the pupillary edge of the iris merely like an an-

[1] Coloboma iridis congenitum—Irido-schisma.

gular notch. Again, a peculiar variety of the defect has been met with, viz., consisting of a fissure in the proper substance of the iris only, whilst the uvea remained perfect.

Fig. 67.

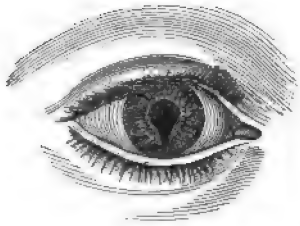

Sometimes one eye alone is affected with congenital fissure of the iris; sometimes both. A case is on record in which there was this malformation in one eye, and in the other a double pupil, like the figure of 8.

In general, the lower half of the eye is less convex than the upper, and apparently less developed. In some cases the whole eye has appeared smaller than natural, the cornea flatter, the pigment deficient, and the eyeball oscillatory. In other cases a complication with cataract has been found to exist, but a considerable degree of vision still remained, as the light penetrated to the retina through the fissure of the iris, and thence through the zonula lucida by the circumference of the lens. In numerous cases, however, the eyeball has appeared quite natural in other respects, and vision good.

The malformation has been observed to be hereditary in families.

It has been found on dissection that the coloboma iridis was a part of a more extensive fissure, involving both the retina and choroid. Coupling this with the fact, that at a very early period a fissure extends through the retina, choroid, and iris, at the lower part, we are readily led to perceive that congenital fissure, implicating the lower part of the iris, is owing to an arrestment of development. In those cases, however, in which, as is said, the fissure implicated some other than the lower part of the iris, the defect cannot be attributed to this cause.

Fissure of the iris from injury (*coloboma iridis traumaticum*) may occur at any part of the iris, and to any extent. There being usually injury of some other part of the eyeball, the mere fissure of the iris is not the principal part of the case.

Misplacement of the pupil and deformity of it, are sometimes

met with as congenital malformations; as also the existence of more than one pupil, as above noticed (p. 303).

Congenital imperforation of the iris.

In many works on the Diseases of the Eye, persistence of the pupillary membrane is alleged as a condition sometimes met with requiring an operation for artificial pupil; and as instances, Cheselden's operations are referred to, never any others. Cheselden's operations, however, were not performed in cases of persistent pupillary membrane, but, as above mentioned (p. 285, note), in cases of closed pupil, after the operation for cataract.

Though the pupillary membrane may sometimes still exist at birth, it ere long disappears, and I believe there is no unequivocal case on record, in which it remained permanent and formed an obstacle to vision requiring the interference of art.

CHAPTER IV.

SECTION I.—ABNORMAL STATES OF THE OPTICAL REFRACTIONS AND ADJUSTMENTS OF THE EYE.

MYOSIS AND MYDRIASIS.

THE name *myosis* is given to an unnaturally contracted,—that of *mydriasis* to an unnaturally dilated state of the pupil, persisting in opposition to the influences to which the pupil is ordinarily obedient, and independent of morbid adhesions, or other organic change of the iris.

To understand the nature of myosis, and mydriasis, it is necessary, in the first place, to have a clear conception of the conditions on which the movements of the pupil depend.

Conditions on which the movements of the pupil depend.

The pupil is, in dull light, in its medium state, which is about one-fifth of an inch in diameter. It becomes contracted to a smaller size when the light to which the eye is exposed is strong; but, on the contrary, dilated to a larger size, when the light is weak. During sleep the pupil is very much contracted. Some time after death it is found of the medium size.

When the pupil is of its medium size, the iris is in a state of re-

laxation, contraction of the pupil to a smaller, and dilatation of it to a larger size, are manifestations of an active state of the iris,—the former of its circular, the latter of its radiating fibres. The contractions of either of these sets of fibres having ceased, it is the elasticity of the iris which brings the pupil back to its medium diameter.

The circular fibres of the iris, by which the pupil is contracted, owe their contractile power to the nerve of the third pair, whilst the radiating fibres, by the action of which the pupil is dilated, owe their contractile power to nervous fibres derived from the spinal marrow opposite the last cervical and two upper dorsal vertebræ, through the corresponding spinal nerves, and thence through the sympathetic in the neck, and which are communicated to the ciliary nerves through the medium of the ophthalmic branch of the fifth, and its connections with the carotid plexus.

When the whole nerve of the third pair is paralyzed, there is fixed dilatation of the pupil to a medium degree, from paralysis of the circular fibres of the iris permitting of unrestrained action of the radiating fibres. Besides this effect on the pupil, there are, ptosis, or falling down of the upper eyelid in consequence of paralysis of the levator palpebræ, permitting of unrestrained action of the orbicularis palpebrarum, and a disposition of the eye to turn outwards, in consequence of paralysis of the internal rectus, and other muscles supplied by the third nerve, permitting unrestrained action of the external rectus.

When fixed dilatation of the pupil occurs, unaccompanied by ptosis and incapacity to turn the eye except outwards and a little downwards, it may be owing to paralysis of that branch only of the nerve of the third pair, which goes to the lenticular ganglion; but in many cases, those of mydriasis, but especially those of amaurosis, in which the pupil moves in concert with that of the opposite sound eye,—there is no reason for supposing that the third pair is at all affected. The dilatation of the pupil is most probably owing to spasmodic contraction of the radiating fibres of the iris overpowering the action of the circular ones.

If this be so, the contraction of the radiating fibres may be supposed to be owing, in the amaurotic cases, to reflex action of the nerves on which the contractile power of the radiating fibres depends, called forth by the insensible state of the retina, in a manner analogous to that in which the absence of the excitement by light of the healthy retina calls forth dilatation of the pupil, whilst, in consequence of the same insensible state of the retina, reflex action of the nerves on which the contractile power of the circular fibres depends, is no longer called forth by the stimulus of light; but in the cases of fixed dilatation of the pupil, in which the retina is

quite sensible (mydriasis properly so called), the mode in which excitement is communicated to the nerves supplying the radiating fibres of the iris must be different. The remote causes are blows on the eye and head, gastric irritation from worms, hardened fæces, &c., and these perhaps operate directly through the sympathetic.

By cutting the sympathetic and vagus in the neck in dogs, contraction of the pupil takes place, in consequence of the radiating fibres of the iris being thereby deprived of their supply of nervous influence and paralyzed, whilst the circular fibres of the iris continue in a state of unrestrained contraction. But it is to be observed that as an immediate effect of the section of the sympathetic, dilatation of the pupil may occur in consequence of the irritation of the nervous fibres, excited at the time by the section. Besides paralysis of the radiating fibres of the iris, and consequent contraction of the pupil, paralysis of the walls of the bloodvessels of the eye is produced. The consequence of which is one form of inflammatory congestion of the corresponding side of the head.[1]

Persistent contraction of the pupil, apparently in consequence of spasmodic action of the circular fibres of the iris, occurs in some cases of amaurosis (erethitic cases). The spasmodic action appears to be kept up by the irritable state of the retina, exciting reflex action of the nerves of the third pair, in a manner similar, except in degree, to what occurs in ordinary circumstances by the action of light. In some cases the spasmodic action appears to be occasioned by irritation of the branches of the ophthalmic of the fifth pair exciting reflex action of the oculo-motor.

The motions of the pupil are involuntary. The power of moving the pupil by an act of the will, which some persons possess, is owing, not to a direct voluntary power they have over the iris, but to the circumstance that they can readily exert the voluntary power of adjustment, which calls forth sympathetic movements of the pupil, as will be explained below (p. 310.)

It is not by directly exciting the iris, that light calls forth contraction of the pupil, but by exciting the retina and optic nerve, and thereby determining reflex action of the nerve of the third pair. Hence, when the retina is insensible, or cut off by section of the optic nerve from its connection with the brain, or when the nerve of the third pair is cut off by section from its connection with the brain, the pupil is not influenced by light, but remains fixed in a dilated state.

In some cases of amaurotic blindness, the motions of the pupil under the influence of light are natural. This is explained by

[1] See a paper on the state of the Blood and the Bloodvessels by the author, in the xxxvi vol. of the Med.-Chir. Trans. p. 401. After section of the sympathetic in the neck in dogs and cats, Donders says that on examining the bottom of the eye by means of the ophthalmoscope, he observed no change in the retinal and choroidal vessels.

supposing that the morbid condition on which the blindness depends, involves only the part of the brain which is the seat of visual perception, and that it is in front of this part of the brain that that condition of structure exists through which reflection takes place, from the optic on the oculo-motor nerve.

In most cases of amaurosis, motion of the pupil is not excited by the light. If, in a case of this kind, one eye only be affected, the pupil remains fixed, so long as the sound eye is covered, but as soon as the latter is exposed to the light, and motion of its pupil thereby excited, motion of the pupil of the amaurotic eye is generally, though not always, likewise excited. This sympathy between the two irides, which is also manifested in the healthy state by motion of both pupils, though one eye only be exposed to variations of light,[1] is explicable by the fact that the optic nerves have each a root in both sides of the brain, and may therefore each be connected in the manner above explained with both oculo-motor nerves.

Myosis.

Myosis may occur uncomplicated with defective sensibility of the retina, but as mere contraction of the pupil does not disturb vision much, except in weak light, it does not usually come under the notice of the practitioner.

Myosis, when it comes under the notice of the practitioner, is generally attended by defective vision;—the myosis and the defective vision being equally symptoms of a morbid condition of the retina.

In those cases in which vision is not impaired, myosis appears to be the result of the habitual contraction of the pupil, induced by constant employment of the eyes on minute and brilliant objects, and is, therefore, frequently met with in jewellers, watchmakers, engravers, &c. The circular fibres, from being at first dynamically and temporarily, would seem, at last, to become organically and permanently contracted.

In the other cases it appears to be owing to the tonic contraction of the sphincter fibres, in consequence of reflex nervous action, excited by the state of the retina, differing from what is the case in ordinary circumstances only by being long kept up.

Treatment.—In cases of myosis of the first kind, belladonna has not much effect on the pupil; and in cases of the second kind, when it does produce some degree of dilatation, vision is not improved; but, on the contrary, disturbed by it. The principles which should regulate the treatment of such cases, are the same as those laid down for the cases comprehended under Amaurosis.

[1] It is to be remembered, as above stated (p. 58), that in the healthy state, when one eye is covered, the pupil of the opposite one is rather less contracted than when both eyes are exposed to the light.

Mydriasis.

Mydriasis, unaccompanied by any other disturbance of vision than is accounted for by the state of the pupil, viz., dazzling, confusion, multiplication and coloration of objects, especially near objects, in consequence of diminution of the correction of spherical, chromatic, and distantial aberrations, is to be carefully distinguished from the dilatation of the pupil, which is so common a symptom of amaurosis.

That a case is one of simple mydriasis, is ascertained, if the patient, on looking through the aperture, of less than the ordinary size of the pupil, is able to see objects quite distinctly. An instru-

Fig. 68.



ment such as that represented in the above figure may be kept for the purpose, but an extemporaneous one can be made by piercing a card with a thick pin. If the card be blackened on the surface next the eye so much the better (p. 64). Vision is also improved by convex glasses, and is better in dull light.

Treatment.—The treatment of mydriasis accompanying ptosis and divergence of the eye, as the consequence of paralysis of the oculo-motor nerve, is discussed below under that head. Simple uncomplicated mydriasis is sometimes removed by irritating applications to the conjunctiva. But before this local treatment is had recourse to, gastric irritation or other disordered states (p. 306), of which the mydriasis is likely to be a symptom, should be the object of treatment.

MYOPY, OR SHORTSIGHTEDNESS, AND PRESBYOPY, OR FARSIGHTEDNESS.

When the distance at which an ordinary sized type can be read *comfortably*, is much less than twelve inches, the vision is said to be myopic, when, on the contrary, it is much greater, vision is said to be presbyopic.

Preparatory to entering on an account of myopy and presbyopy, it will be useful to make some observations on refraction by convergent lenses, and on the adjustment of the eye to different distances.

Refraction by convergent lenses, and the adjustment of the eye to different distances.

The rays of light from very distant objects, though not strictly parallel, are usually assumed to be so. The focus to which such rays are brought by a convergent lens, is called the *principal focus of the lens.*

If rays do not come from such a distant body as to be parallel, but are more or less divergent, then the focus to which they are brought by the lens, is farther off from the lens than its principal focus, viz., at some point between this and infinite distance. This point is nearer the principal focus the more distant the body whence the rays emanated; in other words, the more nearly parallel they are, and *vice versâ.*

The point of an object from which any given pencil of divergent rays emanates, is named the focus of incident rays, and the focus to which these divergent incident rays are brought by the lens is named the focus of refracted rays. These two foci, the focus of incident rays, and the focus of refracted rays, in consequence of the relation between them above pointed out, viz., that when the one is near the other is distant from the lens, are named *conjugate foci.*

From this it will be perceived, that if the refractive media of the eye were incapable of change, either as regards power, or as regards their relative situation to the retina, the rays of light from objects at one particular distance only, would be collected into foci on the retina. Rays from objects farther from the eye than that distance would come to foci before arriving at the retina, and having crossed, would fall on the retina in circles of dissipation. Rays from objects nearer would not come to foci, except behind the retina, on which therefore they would fall likewise in circles of dissipation.

The result of this would be, that objects could be seen perfectly distinctly only when situated at one particular distance from the eye. But we know that this is not the case. We know that we can see objects *perfectly* distinctly at different distances, within certain limits. Hence the eye must admit of adjustment to different distances, like our optical instruments.

Here the distinction is to be explained between perfect and distinct vision. In perfect vision, the outline, color, and details of the object appear traced with the utmost accuracy, clearness, and strength; and this we have only when the rays of light are brought accurately to foci on the retina. In distinct vision, larger objects are seen so well, that they are readily recognized; the title-page of a book, for example, is readily read, but there is a want of clearness

of outline and strength of tint, and small objects or the details of large objects are very imperfectly recognized; this is owing to the rays of light not falling on the retina in foci, but in small circles of dissipation.

The limits within which the eye can see perfectly distinctly at different distances, in other words, the limits of perfect vision, varies somewhat in different persons, and even in the two eyes of the same person; but in general they may be put down at between nine and fifteen inches. For some distance below nine, or above fifteen inches, the vision may be still distinct, but not perfect.

Though there can be no doubt that the eye is capable of adjustment for vision at different distances, the means by which this is effected have not been unequivocally demonstrated; still, as the power of adjustment is lost with the crystalline body, it is very probable that it depends on a change in the position and form[1] of the lens. By a very slight movement of the lens forward, and a very slight increase of its curvature, the eye could be adjusted for near distances, and *vice versâ*.

When the eye is adjusted for near objects, the pupil is contracted, and the axes of the eyeballs converged, and *vice versâ;* but these variations in the size of the pupil and direction of the eyeballs, are merely a concomitant and auxiliary, not an essential condition.[2]

Shortsightedness.

This is that state of vision in which the person can see objects perfectly distinctly only when they are at shorter distances from the eyes, than the average above stated.

It is owing either to too great refractive power of the refractive media of the eye, or to the distance of the retina behind the crystalline being too great; so that in either case, the rays of light come to a focus before arriving at the retina, cross and are in a state of dissipation, when they do impinge on that nervous membrane, and therefore form indistinct and confused images.

By bringing the object near the eyes, it is distinctly seen, because the rays from it, which enter the eyes, being now more divergent than when it was distant, are not so soon brought to a focus; in other words, the different points of the object, as foci of incident rays, and the foci to which these rays are brought in the

[1] Dr. Crane, a Dutch physiologist, has found that in the adjustment for near and distant sight, a change of form and place of the images reflected from the anterior surface of the lens is observable—a proof that the power of adjustment depends, in part at least, in a change of form of the anterior surface of the lens.

[2] With a contracted pupil or by looking through a small aperture, a presbyopic eye can see near objects, and a myopic eye distant objects more distinctly. This is owing to the exclusion of the extreme circumferential rays of the cones of light which enter the eye and the consequent diminution of the circles of dissipation on the retina.

interior of the eye by the refractive media, are *conjugate foci*, and accordingly when the foci of incident rays are brought nearer the refractive media, the foci of refracted rays recede from them.

Too great a refractive power of the media of the eye, may be owing either to too great convexity of their curvatures,—the curvatures of the cornea and crystalline,—or too great refractive density, or both conjointly.

The situation of the retina at too great a distance behind the crystalline body, may be owing either to a preternatural elongation of the axis of the eyeball, or to the lens being nearer the cornea than usual.

In shortsightedness, the power of adjusting the eye to different distances, is still retained, but within certain limits, thus :—the nearest distance may be from two to four inches, the furthest, from six to twelve.

Appearances presented by the eyes of myopic persons.—In many cases there is nothing peculiar to be observed ; but frequently the eyes are prominent and firm, the cornea very convex, the anterior chamber deep, and the pupil dilated.

Peculiarities of the vision of shortsighted people :

1st., They see small objects more distinctly than other people, because from their nearness the objects are viewed under a larger visual angle.

2d. They see them also with a weaker light, because the objects being near, a greater quantity of rays from them arrive at the eye. Hence, they can read small print with a weak light.

3d. But they can also see more distinctly, and somewhat further off by a strong light than by a weaker one, because the pupil is contracted by the strong light, and all but the more direct rays of light thereby excluded. On the same principle they see at some distance distinctly through a pinhole in a card ; and when they try to view distant objects, they half close their eyelids. The rays of light in these cases have their divergence at the same time somewhat increased by diffraction.

They sometimes see objects beyond the limits of their distinct vision, double, or even multiplied.

Subjects of shortsightedness.—This defect of vision seldom occurs in so great a degree before puberty as to be troublesome ; when in a great degree in children it may be a symptom of central cataract (p. 240). After puberty, when the eyes come to be used in earnest, shortsightedness is usually first discovered to exist, and it may go on gradually increasing, especially if the person uses his eyes much in reading, and on minute objects ; hence, the greater frequency of shortsightedness among the educated classes, and those whose occupation is with minute work. Myopy does not

always diminish with years. We meet with persons of the most advanced age who still find it necessary to use glasses as deeply concave as they did in youth, if not more so. Nay, myopy sometimes occurs in old persons, whose vision was previously good for ordinary distances.

Diagnosis.—Attention has been above (p. 64) directed to the distinction of true or optical shortsightedness under consideration from that shortsightedness which depends on defective sensibility of the retina. In this latter form, which may be named amblyopic shortsightedness, although objects are seen better near at hand, they are not seen distinctly, as in true shortsightedness; and help is obtained from convex instead of concave glasses.

In amblyopic shortsightedness, near objects are, as above said, seen better, because more light being received into the eye from them, a stronger impression is made on the retina. On the same principle, convex glasses help the sight,—and that for distant as well as near objects,—by concentrating the light. On the same principle also, well illuminated objects are seen better.

An analogous form of shortsightedness is occasioned by impaired transparency of the lens.

But, besides distinguishing one form of shortsightedness from another, it is sometimes necessary to determine whether there be shortsightedness at all—in short, whether or not a case be one of feigning.

The simplest plan is to try whether the person can read middle-sized print with such deep concave glasses as Numbers 6 and 10. If he can do so he must be shortsighted. But in addition to this test it may be useful to try the person further by requesting him to read, now with concave, now with convex glasses, without of course letting him know the difference, and noting the consistency or inconsistency of his answers to the question—how he sees with them?

Treatment.—To persons whose occupation is with minute objects, shortsightedness, unless in a very great degree, is rather an advantage, as they are enabled to observe all the details of their work very accurately; and in the ordinary exercise of vision, the use of concave glasses is a ready and simple help.

When a tendency to shortsightedness manifests itself in young persons, and especially if the future occupation of the person is to be of a kind requiring good vision for distant objects, much exertion of the eyes on minute work should be avoided, and the eyes frequently exercised on large and distant objects.

Concave glasses help the vision of shortsighted persons for distant objects, simply by increasing the divergence of the rays of

light before they enter the eye, so that they may be less speedily brought to foci than they would otherwise have been, in consequence of the increased refractive power of the media of the eye; or, supposing the refractive power of the media of the eye not increased, but the distance of the retina behind the lens increased, that they may be brought to foci at a greater distance behind the lens than they would otherwise have been, in order to correspond with the greater distance of the retina behind the lens.

Concave glasses are made of different degrees of concavity, the shallower being those adapted for the slighter degrees of shortsightedness, the more concave for the greater degrees.

When very shortsighted, a person requires to use concave glasses, not only to be enabled to see distant objects, but also for reading with, in order to avoid the necessity of stooping. For the latter purpose shallower glasses suffice. Less shortsighted people use glasses only to be enabled to see distant objects.

The focal length of the concave glass which a person will require to see objects at more than two hundred or three hundred yards distance, should be about equal to the distance at which he can see to read distinctly an ordinary type with the naked eye—six inches for example.

The focal length of the concave glass which a very shortsighted person will require to see to read at a convenient distance, is determined thus:—Suppose he sees to read with the naked eye at the distance of six inches, and desires to be able to read at the distance of twelve, the one distance is to be multiplied by the other, and the product seventy-two divided by the difference between the two distances, viz., six. The quotient twelve, is the number of inches the focal length of the glass required should be.

But when a person finds it necessary to have recourse to glasses for shortsightedness, he should go to an optician, and select two or three pairs which appear to assist his vision best; or send for two or three pairs of about the focal length, which according to the above calculation he thinks will suit him, and try them leisurely at home for a day or two before fixing his choice on one particular pair.

The following are the circumstances which should guide him in his choice:

The glasses should be the lowest power which will enable him to distinguish objects as he wishes, quite readily and clearly, and at the same time comfortably. If they should make objects appear small and very bright, and if in using them the person feel his eyes strained and fatigued, or if he becomes dizzy, and if after putting them aside the vision is obscure, they are not fit for his purpose—they are too concave.

Having once fitted himself, a person should not too hastily change his glasses, although they may appear not to enable him to see quite so clearly as when he first used them.

A glass to each eye should always be employed, vision is by this clearer, and its exercise less fatiguing to the eyes, than when a glass to one eye only is used. The use of a glass to one eye only is, in fact, very detrimental, especially to the opposite eye.

Farsightedness.

With this state of vision the person can see objects distinctly only when they are at a very considerable distance from the eyes; in reading, for example, he holds the book at arm's length.

Farsightedness being in almost all respects the converse of shortsightedness, the best way of discussing it here will be simply to reverse the account above given of shortsightedness, and which will therefore stand thus:

Farsightedness is owing either to diminished refractive power of the refractive media of the eyes, or to the distance of the retina behind the crystalline body being too short; so that in either case the rays of light tend to come to a focus at a point behind the retina, on which therefore they impinge in circles of dissipation, and form indistinct and confused images.

By removing the object from the eyes, it comes to be distinctly seen, because the rays from it which enter the eye, being now less divergent than when it was near, are more quickly brought to a focus; in other words, the different points of the object as foci of incident rays, and the foci to which these rays are brought in the interior of the eye by the refractive media are *conjugate foci*; and, accordingly, when the foci of incident rays are removed from the refractive media, the foci of refractive rays come near them.

Diminished refractive power of the media of the eye may be owing to diminution of the convexity of their curvatures, flattening of the cornea, and crystalline. As to refractive density, there is probably an increase rather than a diminution of it, but this appears to be more than over-balanced by the diminution of curvature.

The situation of the retina too near the crystalline may be owing either to a preternatural shortening of the axis of the eyeball or a receding of the lens from the cornea.

In farsightedness, the power of adjusting the eye to different distances is much weakened. In this respect farsightedness differs from shortsightedness, in which the power of adjustment is still retained. In farsightedness it may be said that the habitual adjustment of the eye is for distant objects, and that in trying to read,

for example, the power of adjustment is exerted to the utmost, hence the fatigue and confusion of vision which soon ensue.

Appearances presented by the eyes of farsighted people.—In many cases there is nothing peculiar to be observed; but frequently the eyes are sunk, the cornea flat, and of small diameter, and the pupil contracted.

Peculiarities of vision of farsighted people:

1. They see small objects indistinctly at every distance, because when near, they are out of focus, and when removed from the eye somewhat, they are seen at a small visual angle and with little light. By increasing the light, they see better. Hence they do not see so well by candle-light as before, and when attempting to read by candle-light, they place perhaps the candle between them and the book held at arm's length.

2. They see large and distant objects very distinctly.

3. In most presbyopic persons, Dr. N. Arnott has ascertained that double vision in the eyes singly exists in a slight degree.

Subjects of farsightedness.—Farsightedness seldom occurs except in persons who have passed middle age, and in them it is so common, that it is to be viewed as a natural change in the state of the eye. As it occurs in young persons, it will be spoken of under the head of *Asthenopy*.

Prevention and treatment.—Though instances have occurred of persons who have been long presbyopic, recovering their former vision, and thereby being enabled to lay aside the use of their spectacles, recovery from presbyopy is not to be calculated on, but this is of small moment, as vision can be so perfectly assisted by means of spectacles.

Something, however, may be done in the way of preserving the sight by avoiding over-exertion of the eyes in reading and other minute work, especially by artificial light, at the time of life when farsightedness, with diminution of adjusting power, usually comes on.

Convex glasses help the vision of farsighted people for near objects, by diminishing the divergence of the rays of light before they enter the eye, so that they may be more speedily brought to foci than they would otherwise have been, in consequence of the diminished refractive power of the eye; or, supposing the refractive power of the eye not diminished, but the distance of the retina behind the lens diminished, that they may be brought to foci at a less distance behind the lens, than they would otherwise have been, in order to correspond with the diminished distance of the retina behind the lens.

Presbyopic persons, at the same time that they have lost the power of adjustment for near objects, may be somewhat cataractous,

or have their retina impaired in sensibility. In such cases, convex glasses, besides remedying the defective adjustment, are of use by concentrating the light.

Convex glasses are made of different degrees of convexity. The least convex being those adapted for the slighter degrees of farsightedness, the more convex for the greater degrees.

To see distant objects, farsighted persons do not in general require convex glasses. It is most commonly to enable them to read and do minute work that farsighted people use spectacles.

If it is only at a *very great* distance that a person can see distinctly, the focal length of the convex glass which he will require to enable him to read will be equal to the distance at which he wishes to see to read.

If he is not so very farsighted, but can see small objects distinctly at twenty inches distance, for example, the focal length of the convex glasses, which he will require to enable him to read at twelve inches distance, is determined by multiplying the two distances together, and dividing the product, 240, by the difference between them, viz., eight. The quotient thirty is the focal length in inches of the glasses required.

But when a person finds it necessary to have recourse to glasses for farsightedness, he should go to an optician, and select two or three pairs which appear to assist his vision best, or send for two or three of about the focal length, which, according to the above calculation, he thinks will suit him, and try them leisurely at home for a day or two before fixing his choice on one particular pair.

The following are the circumstances which should guide him in his choice :—The glasses should be of the lowest power which will enable him to see objects distinctly as he wishes, and at the same time comfortably. Glasses which make the objects appear larger than natural, and strain and fatigue the eyes and cause headache, are not adapted to his case,—they are too convex. It is usually found that glasses the next degree more convex are required for work by artificial light.

The alteration in the eye on which the farsightedness depends, generally goes on to increase with age, hence, it is necessary, after a time,—a few years,—to change the glasses first chosen for others more convex. In regard to this exchange it is to be observed, that it ought not to be too hastily had recourse to, nor, on the other hand, too long delayed. The same feeling of necessity which first prompted to the use of glasses, will indicate the necessity of change.

Reading Glass.—This is a double-convex lens, broad enough to permit both eyes to see through it. It is used for the purpose of

magnifying the object,—the names on maps, or the like; whereas, convex spectacles are used merely to render objects distinct at a given distance, without magnifying them, as above mentioned.

Cylindrical eye.

Mr. Airy has written an account[1] of one of his own eyes, which he ascertained to refract the rays to a nearer focus in a vertical than in a horizontal plane. This would take place, he remarks, if the cornea, instead of being a surface of revolution, in which the curvature of all its sections through the axis must be equal, were of some other form, in which the curvature in a vertical plane is greater than in a horizontal. This is, in fact, the natural form of the cornea, but in the instance of Mr. Airy's eye, existing, perhaps, in an exaggerated degree so as to disturb vision.

With such unnatural conformation of the eye, a point appears a line of uncertain length; a circle an oval; everything being seen elongated in one direction. The cylindrical deformation has been met with oblique, so that a square appeared a parallelogram.

The defect is remedied by glasses which, to the healthy eye, would make a line of the same length appear a point,—which would, in fact, shorten all objects in the same degree and in the same direction, as they are lengthened by the defective eye.[2]

Each case of cylindrical eye being thus more or less peculiar, lenses must be specially prepared for it; and it is evident that this demands both skill and intelligence on the part of the optician. The general principle on which the glass is shaped, Mr. Ross informs me, is this: one side of the lens is made a portion of a cylinder, of the same diameter as the cylinder cornea, having its axis, however, placed at right angles to that of the latter. The other side of the lens is made plane, convex, or concave, to suit the condition of the eye irrespective of its cylindricity.

Unequally refractive state of the two eyes.

The two eyes may be in different degrees myopic or presbyopic. Though in either of these cases, the use of concave or convex glasses of a different focal length for each eye is theoretically indicated, it is not in practice found to answer. It generally gives rise to such confusion of sight and actual pain that it is soon abandoned.

Again, one eye may be myopic, and the other presbyopic. In this case a concave glass for the former and a convex one for the

[1] Transactions of the Cambridge Philosophical Society, quoted in the Encyclopædia Metropolitana, article LIGHT, p. 398, § 359.

[2] On the Use and Abuse of Spectacles, by Andrew Ross, Optician, London.

latter, are theoretically indicated, but they are found practically as inefficient as glasses of different focal lengths in the preceding cases.

Loss of power of adjustment.

The eye may fall into a state in which the vision is neither myopic nor presbyopic, and in which the power of accommodation being lost, convex glasses are required to see near objects, and concave glasses to see distant objects.

Chromatic vision.

The colored vision to be noticed here must be distinguished from that dependent on subjective excitement of the retina, to be considered below, in Section I. of the next chapter (p. 327, et seq.)

Although the eye, strictly speaking, may not be perfectly achromatic, it is so in a healthy state to all intents and purposes; but in certain morbid states its optical parts may become so suffused and deranged as to decompose the light, and make objects appear as if surrounded by the colors of the rainbow, thus:

1st. In puromucous inflammation of the conjunctiva, films of mucus suffusing the cornea give rise to the appearance of iridescence around objects (p. 117).

2d. When there is defective adjustment of the eye, and when, consequently, the rays of light do not fall in foci on the retina, vision, at the same time that it is thus rendered indistinct, and even multiplied, may appear slightly iridescent. Hence iridescence around objects is seen when the adjusting power of the eye is disturbed by passion, mental abstraction, sleepiness, the action of belladonna, mydriasis. Hence, also, persons who have one eye myopic, and the other presbyopic, often see colors when they look at very near or very distant objects with both eyes, because one eye only is adjusted to the distance of the object.

Diplopy and polyopy with one eye.

In consequence probably of the refractive media of the eye not having perfectly regular curves, diplopy and polyopy with one eye occur, as just mentioned, when the eye is not adjusted to the distance of the object looked at; hence shortsighted people see distant objects, and farsighted people near objects, double or multiplied with one eye as well as iridescent.

But vision of one eye may be double or multiplied independently of defective power of adjustment to distance, in consequence of partial opacity of the cornea, or, more generally, partial opacity of

the lens or its capsule. The action of these morbid states is well illustrated by Scheiner's experiment, which consists in looking at a pin, for example, through two pinholes in a card placed so close to each other as to be included within a space equal to the diameter of the pupil. The pin appears double, except when held at a certain distance—that of perfect vision with the naked eye.

Asthenopy, or weaksightedness.[1]

Subjective symptoms.—An incapacity to exercise vision on near objects, as in reading, sewing, and the like, for any length of time. The patient is able at first to see to read quite distinctly, but the vision soon grows confused,—the words appearing as if mixed together. The eyes at the same time become tired and painful—the pain extending to the head.

If the eyes are closed, and rest given to them for a few minutes, vision may be again exercised, but in a short time the eyes will again become fatigued, and the vision confused. Both eyes are in general equally affected.

The vision of distant objects is not disturbed, and by the use of convex glasses the exercise of vision on near objects may be much assisted.

Objective symptoms.—The eyes may appear dull and heavy, and are perhaps directed towards objects in a weak, indecisive manner, but in general they present no positive appearance of disease. The pupils are sometimes quite lively—sometimes sluggish.

Age.—Asthenopy commences in childhood or youth, and may continue throughout life; but it is seldom met with originating in the middle period of life.

State of health.—The subjects of the affection often, but by no means always, labor under general nervous debility—the result sometimes of general disease.

Causes.—There is often no evident cause. A very frequent cause is pure over-exertion of the eyes, as in students, artists, clerks, engravers, watchmakers, tailors, sempstresses, &c., especially by artificial light, together with want of sleep, want of exercise in the open air, &c. The complaint sometimes occurs as a sequela of inflammation of the eye, especially scrofulous, external, and internal. Injuries of the fifth nerve in the circumorbital region, and affections of the brain, are sometimes followed by asthenopy. Losses of blood, seminal losses, and the like, excite the affection apparently by occasioning general nervous debility.

Nature of the complaint.—Asthenopy appears to consist in debility of the apparatus by which the eye is adjusted for the vision

[1] Mackenzie in Edin. Med. and Surg. Journal, No. 156.

of near objects. It is as if one were to hold a book too near. Though he might be able by an effort to adjust his eyes so as to see to read for a minute or two, the sight would then become confused, and the eyes tired. The use of convex glasses would, however, prevent this. Along with this defective power of adjustment, there is an irritable state of the retina, connected in some manner with tendency to internal congestion of the eyes.

Diagnosis.—Asthenopy is principally to be distinguished from presbyopy, night-blindness, and amblyopy, or incomplete amaurosis.

1st. *Presbyopy.*—Presbyopy sometimes occurs in children, and might be confounded with asthenopy, as the two have this in common, that distant objects are seen without straining of the eyes, whilst in asthenopy during a paroxysm as well as in presbyopy, near objects are not. Presbyopy is, however, distinguished from asthenopy in the circumstance, that by rest the eyes do not acquire the power of distinguishing near objects.

2d. *Night-blindness.*—Asthenopy is in many cases most troublesome during the use of artificial light, and even approaches to night-blindness in the suddenness of its attacks, and the degree of imperfect vision which attends it.

3d. *Amblyopy, or incomplete amaurosis.*—In amblyopy there is constantly present an indistinctness of sight extending to all objects, large and small, distant and near; in asthenopy indistinctness of sight comes on only after the eyes have been exerted on near objects. In amblyopy the patient sees best after having fixed his eyes for some time on the object he examines; in asthenopy, on the contrary, vision fails then.

Prognosis.—This is, on the whole, unfavorable, especially if the complaint is of long standing, if it has originated in an ophthalmia, injury of the fifth nerve, or of the encephalon. Less unfavorable when it has arisen under other circumstances, provided what appears to be the exciting cause admits of removal. Asthenopy, though it has become confirmed, rarely passes into amblyopy, and is not likely to end in blindness.

Treatment.—The first thing in the way of treatment is the avoidance, or removal by appropriate means, of any cause which may appear to be in operation, such as over-use of the eyes, seminal losses, &c.

If the complaint appear to have resulted from previous inflammation of the eye, injury of the fifth nerve, or some affection of the brain, an alterative course of treatment, with counter irritation, may be tried.

Rest to the eyes, the occasional application to them of the cold douche, good diet, exercise, country air, sea-bathing, and the like, must in general constitute a leading part of the treatment of asthenopy.

When the patient requires to employ his eyes on near objects, he has no other resource than to use convex glasses, which, in some cases, must be of the very lowest power only; but it would be advisable for the patient, if his occupation requires much use of the eyes, to change it, if possible, for one of an opposite kind.

Complications.—Asthenopy is often complicated with some other affection. It may be complicated with the effects of some one of the ophthalmiæ; with myopy or presbyopy; with muscæ volitantes; sometimes oscillation of the eyes, and not unfrequently strabismus, with amblyopy or incomplete amaurosis. Persons blind of one eye are not unfrequently affected with asthenopy in the other. One eye may be incompletely amaurotic, the other asthenopic. When asthenopy is complicated with amblyopy, the vision is at all times more or less obscure, but on reading, &c., it soon becomes still more so, recovering, however, after a little rest.

The following are a few cases in illustration of the occurrence of asthenopia:

A lad, æt. 17, complained that his eyes soon got tired in reading, and that the words appear confused and mixed together. On trying convex glasses, forty-eight inches focus, he found that he could continue to read for a longer time than usual.

A young woman, æt. 18.—Three years ago began to menstruate, and about that time the sight became so affected that she could not continue to read or see for more than a minute or two at a time. In trying to read, holds the book or paper at the distance of about two feet. With convex glasses, forty-eight inches focus, sees to read very comfortably.

A woman, æt. 29.—When a girl at school, the eyes soon became fatigued when occupied in reading, writing, or sewing; the sight becoming dim at the same time, and tears flowing. After an interval of rest, however, the sight became clear again. For the last five years she reports that the sight has been becoming more and more dim; so that she cannot see to get through her work. At present she can see to read if she holds the book very close to the eyes. The sight of the right eye is better than that of the left. Concave glasses No. 2, improve the sight somewhat.

The pupil influenced by the light.

A woman, æt. 30.—Seven months ago, when suckling her infant, seven months old, was attacked with severe inflammation in both eyes. From the adhesions of the pupillary edge of the iris, disclosed by dilating the pupil by atropia, it appears that this inflammation was iritis. After the inflammation subsided, the sight was found to be dim, and she was unable to continue the use of her eyes for more than a few minutes at a time. This asthenopia still exists.

Section II.—Vision of Objects in and on the Eye.[1]

Under certain circumstances, one may see objects in or on his own eyes. The appearance constitutes what is commonly known by the name of *muscæ volitantes.*[2] Under this name, however, certain other morbid appearances are often also included, which are not owing to the visual perception of any object in or on the eye, but are entirely subjective; are owing, for example, to insensible spots of the retina. Such appearances as the latter have no real motion, but apparent motion only, depending on that of the eye; hence they are distinguished by the name of *fixed muscæ* from the former appearances, which present the real as well as apparent motions.

VISION OF OBJECTS IN THE EYES.

Common muscæ volitantes.[3]

Fig. 69.

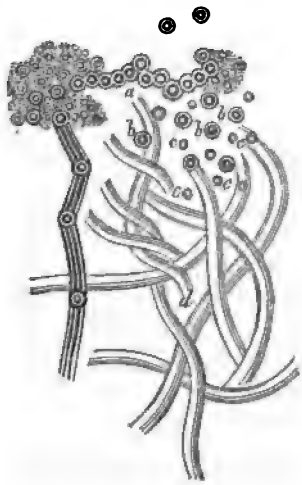

Muscæ volitantes appear to the patient who has made no particular examination of them, under the form of blackish motes, or of a thin gray film, like the wing of a fly, or of semi-transparent gray threads, like spiders' web, but if viewed attentively against the clear sky, a white wall, or the like, they are recognized to be made up of appearances such as the following:—1st. A convoluted string of beads, or a convoluted transparent tube, containing in its interior a row of beads smaller than its diameter, except here and there where one larger than the rest is seen occupying its whole diameter, the end of the string or tube sometimes presenting a dark knobbed extremity, as if formed by an aggregation of the beads composing the string, or contained within the tube (Fig. 69, *a*); 2d, Insulated beads, some of which, and these the more frequent, have a well-defined outline (*b*)—others, and these rarer, have an indistinct outline (*c*); and,

[1] Mackenzie, in Edin. Med. and Surg. Journal, No. 164.
[2] Spectra, Scotomata, Myodesopia, &c.
[3] Floating muscæ—Entohyaloid muscæ.

3d, a parcel of flexuous round watery-looking or spun-glass like filaments with dark contours, often divided inferiorly into truncated branches (*d*).

These different appearances may be seen altogether, the beaded appearance on one side of the parcel of watery-looking filaments, and interspersed here and there the insulated beads, one or two of the well-defined of which often appearing as if attached to the outside of the beaded tubes; or some one of the appearances may be seen principally or exclusively.

According as the distance of the object against which the muscæ volitantes are viewed is greater or less, they appear larger and fainter, or smaller and more distinct.

Vision is not affected by floating muscæ. Between the several portions of the muscæ and by the side of them, the eye still sees everything with perfect distinctness. Even the portions of the retina, over which the shadows which cause the appearance of the muscæ fall, are found by the patient, when the corpuscles ascend out of the field of vision, to be perfectly sensible.

Muscæ volitantes are often detected suddenly, and thus are supposed to have just occurred. They are most observed when the patient looks at the clear sky, a thin cloud, snow on the ground, a white wall, or the like. They are not, if at all, noticed under the opposite circumstances of a dull light, and looking at a dark object. They are not much seen when near objects are looked at.

They are rarely seen in the axis of vision, but generally to one or other side or above or below. The patient thus seeing them only by a side glance, finds it difficult to fix them in order to study their appearance. They move as the eye moves upwards and downwards, or from side to side; but besides this motion, which, as dependent on that of the eye, is merely apparent, the muscæ have a real motion of their own, and still more extensive than their apparent motion. Thus, if from looking before him in a horizontal direction, the patient suddenly raises his eyes and fixes them on some object above the horizon, he observes that the muscæ fly upwards considerably beyond that degree of elevation, and even beyond the field of view, and then come sailing down before him till they disappear below.

Besides the motions of ascent and descent, the muscæ volitantes under consideration present lateral movements, although less marked, as well as changes in the relative positions of their several parts.

Nature of floating muscæ.—Hitherto a very common opinion as to the nature of floating muscæ has been, that they are subjective sensations, depending on some intrinsic change of state of the optic nervous apparatus, thus confounding them with mixed muscæ, but that they are truly objective sensations, occasioned by the pre-

sence of particles in the interior of the eye, but extrinsic, and in front of the retina, throwing their diffracted shadows on the retina, admits of mathematical demonstration.

But without entering minutely into the matter, the proposition may be easily demonstrated thus:—Hold between a convex lens and the white surface on which the image of the light falls, some small object, as a pin. When this is near the lens, its shadow is not seen on the white ground, but when it is brought nearer and nearer the white surface, its shadow appears more and more distinctly.

The particles, moreover, appear to be of normal occurrence in the eye, for the appearance of floating muscæ may in general be seen by any person by simply looking through a small aperture in a card at the clear sky, or through the eyeglass of a compound microscope at the flame of a candle two or three feet distant, or simply by bringing the eyelids towards each other, and looking at a lighted candle.

On contemplating the spectra thus brought into view, viz., the beaded filaments, the distinct and indistinctly defined globules, and the watery-like filaments, called by Dr. Mackenzie respectively the *pearly spectrum*, *the distinct insulo-globular spectrum*, and the *watery spectrum*, it is observed that they are situated in different planes, one behind the other, "that they never mingle with one another, so as to change the order in which they stand before the eye; but the pearly spectrum always appears the nearest, then the sharply-defined insulo-globular, then the obscurely-defined globules, and farthest away the watery threads."

Seat of the particles, the presence of which occasions muscæ volitantes.—This admits of being mathematically demonstrated to be in front of the retina, in or behind the vitreous body, but at the same time it appears that it is different for the different kinds, being in almost immediate proximity with the retina for the pearly spectrum, and farthest from the retina for the watery spectrum.

Nature of the particles, the presence of which occasions floating muscæ.—This has not yet been with certainty determined. In the vitreous humor (as also in the aqueous) there is contained a great number of corpuscles, most of them resembling lymph corpuscles, though smaller, being between 1-4000th and 1-5000th of an inch in diameter; but it appears from the calculations of Brewster, Mackenzie, and Reute, that the size of the particles, the presence of which occasions floating muscæ, is much greater than this.

Muscæ volitantes are often seen by persons without any particular notice of them being taken, as they are indistinct, present themselves occasionally only, and are therefore not troublesome.

Their appearance in cataract is owing to the opaque lens acting much in the same way as the perforated card.

They are seen most distinctly, and are therefore most troublesome, when there exists an irritable state of the retina, with weakened irradiation (p. 329, et seq.) Such a state of the retina may therefore be viewed as the general condition on which floating muscæ, considered as a disease depend.

Dilution of the images of external objects favors, distinctness, on the contrary, prevents the perception of muscæ. Hence, when the person is short or farsighted, they appear less evident to him when he uses the glasses fitted to render his vision distinct. This appears to be owing to the stronger impression of the external objects making up for the weakened irradiation, so that the weak impression of the objects of the muscæ is more readily effaced.

The pupil of an eye affected with muscæ volitantes is generally contracted, even, when the eye is myopic.

Exciting causes.—Over-use of the eye on minute objects;—Inflammatory diseases of the eyes, external as well as internal;—The seeking for them in experiments;—Intemperance;—Febrile diseases;—Influenza;—Disease of the heart;—Want of sleep;—Dyspepsia;—Abdominal congestion;—Hysteria;—Hypochondriasis;—Morbid sensibility of the system generally, arising from pressure of business, anxiety, and distress of mind. All these causes appear to operate in the same manner, occasioning a congested state of the eyes and weakened irradiation of the retina.

When a hypochondriacal person once detects muscæ volitantes, he takes such frequent notice of them, that they become to him more and more troublesome.

Prognosis.—From what has been said, it will be seen that the occurrence of floating muscæ is of itself no indication that either cataract or amaurosis is taking place. If, however, there be along with the appearance of muscæ a failure of vision, and if that failure be not attributable to myopy or presbyopy, which may be ascertained by a concave or a convex glass not improving vision, then cataract or amaurotic amblyopy may possibly exist.

In uncomplicated cases, the muscæ may indeed increase in numbers, but very slowly, and never to such extent as to interfere with the distinctness of vision in any very troublesome degree. But sometimes the muscæ remain stationary, or even become less.

As they depend on the vision of objects naturally existing in the eye, in consequence of a morbid sensibility of the retina, whatever tends to promote or relieve this will have the effect of promoting or relieving the muscæ.

The particles on which the appearance of muscæ volitantes, as

above described, is supposed to depend, are too minute to be detected by the ophthalmoscope. In certain cases of exaggerated muscæ, however, accompanying a morbid state of the posterior segment of the eyeball, it is related by Dr. Van Tright, that numerous shreds and tortuous filaments could be seen moving harmoniously in the vitreous humor.

Treatment.—The removal or abatement of the exciting cause, if it can be detected, is the first thing to be looked to. Rest to the eyes, if they have been overstrained, relaxation from business, quiet to the mind. When the stomach and liver are out of order, mercurial alteratives, followed by tonics, regulated exercise, and change of air. Cold applications to the eyes, such as the cold douche bath (p. 66) twice or thrice daily, for five or ten minutes, is the most important local application.

Spectrum of the vascular ramifications and network of the retina.

This may be seen by means of the following experiment, which, from having been first pointed out by Professor Purkinje, is commonly called the experiment of Purkinje. It consists in shading, without closing one eye, and looking straight forward with the other, whilst a lighted candle (the room being otherwise dark) is moved up and down close to the eye on the temporal side. In a short time a magnified spectrum of dark ramifications and anastomoses, on a light ground, appears floating before the eye, moving in a direction opposite to the movements of the candle.

In this experiment those parts of the retina covered by the ramifications of the central vessels not being so much excited by the light as the rest of the membrane, do not retain the impression so long as until the return of the candle; hence the appearance of dark ramifications in the field corresponding to those parts.[1]

Circulatory spectrum.

An appearance of grayish watery-like particles darting in every direction before the eyes, somewhat like the circulation in the web of the frog's foot under the microscope, may be seen by a healthy eye, by gazing at the clear sky for a short time. If the eyelids are shut, the particles are seen dark red. This appears to be an objective

[1] A spectrum of the vessels of the retina is, in certain states of the eye, seen independently of external light—light on a dark ground; but this is owing to pressure on the retina by the vessels. Being thus a subjective phenomenon, it belongs to the head of *photopsy*.—See next chapter. The appearance above referred to in p. 104, is similar to the vascular spectrum, but is owing to insensibility of the retina, from the pressure and opacity occasioned by the congestion and exudation in inflammation of the vascular layer of the retina. This, therefore, also belongs to the next chapter—to the head of *fixed muscæ*.

sensation, produced probably by the shadows on the retina of the blood corpuscles circulating in its vascular layer.[1]

VISION OF OBJECTS ON THE EYE.

Muco-lacrymal muscæ.

Sometimes, though rarely, appearances are seen like opaque round spots, surrounded by a halo, which occasionally seem to run together, and again divide, and which slide downwards, but reascend after every nictitation.

These appearances seem to depend on spectra, produced by the shadows of minute globules of air, in the mucus and tears, on the cornea. They are therefore called by Dr. Mackenzie, muco-lacrymal muscæ volitantes.

CHAPTER V.

AMAUROTIC AFFECTIONS.

Section I.—Introduction.—Abnormal Excitement of Visual Sensations.

In amaurotic affections, various visual sensations, though not in themselves unnatural, are apt to be excited unnaturally. As such, are important as symptoms, it is necessary to study them; but previously to doing so, the circumstances attending their natural occurrence must in each be taken into consideration.

Sensations of light and color, independent of external light, excited by internal influences operating on the optic nervous apparatus.

In the unexcited condition of the optic nervous apparatus, there is darkness before the eyes, but in the excited condition, light and color are seen.

The agent by which the optic nervous apparatus is usually excited, is the principle of light; but an excited condition, and consequently the sensations of light and color, may be called forth by other influences, such, for example, as pressure. And it is to be

[1] When one stoops and then suddenly rises. the appearance of showers of lucid globules before the eyes is of a different nature, being a subjective sensation, excited by pressure on the retina by the determination of blood. So also is an appearance similar to that above described, except that the particles are lucid. The appearance of lucid spectra therefore, belongs to the head of *photopsy*. See next chapter.

[2] Photopsy and Chroopsy.

observed, that whatever may be the stimulus which excites the optic nervous apparatus, no other sensations but light and color can be called forth in it.

As nervous primitive fibres are throughout the whole course physiologically the same, it is indifferent what part of the optic nervous apparatus be excited, in order that luminous sensations may be perceived—whether the retina itself be irritated, the fibres of the optic nerve in the orbit irritated or cut, or whether the cerebral part of the optic nervous apparatus be pressed on by congestion or tumor. As, moreover, the activity of nervous fibres is always manifested at their peripheral extremities, so in whatever part the optic nervous apparatus be excited, the luminous sensation which results is always referred by the sensorium to the periphery; not only to the periphery, however, but as in natural vision to without the body—(*projection outwards*).

A familiar example of a luminous spectrum of the kind under consideration is that which, on pressing the eyeball, is seen projecting outwards, and on the side opposite to that where the pressure is applied.

Other examples are—a spectrum of the vessels of the retina, *light on a dark ground*, which, in certain states of the eye, is seen, and which is owing to pressure on the retina by its vessels in a state of congestion;[1] the appearance of a shower of lucid globules before the eyes on suddenly rising from a stooping posture, from the disturbance in the circulation in the optic nervous apparatus thereby occasioned.

Analogous appearances of fiery scintillations, flashes of light, and colored coruscations, occurring spontaneously, are symptoms of irritation or excitement of some part of the optic nervous apparatus—cerebral or ocular,—from inflammatory congestion; when ocular, from inflammatory congestion of the choroid, as above mentioned (p. 105), rather than from inflammatory congestion of the retina. As such inflammatory congestion may end in amaurosis, so the luminous and colored spectra are symptoms of incipient amaurosis. They may continue to appear, however, after all visual sensibility is lost.

A woman, deaf for some years, and troubled with noises in her head, became subject to photopsy also; and fell into the hallucination of supposing that people had everywhere conspired to annoy her by throwing glares of light into her eyes. I found it impossible to convince her of the real nature of her complaint. Her intellect was evidently impaired from the same disease of the brain to which the noises in the head and the photopsy were owing.

[1] The difference between this and the spectrum in Purkinje's experiment is above explained.—See note, p. 326.

Sensations of light and color of the kind just considered are to be distinguished on the one hand from those which depend on an optical derangement in the eye itself, whereby its achromatism is destroyed (p. 318, et seq.), and on the other from accidental or complementary colors, considered in the next article but one.

Reciprocal action of the different parts of the retina on each other's sensations.

Participation of the different parts of the retina in each other's sensations or irradiation of sensations.—Any one fibril of a sensitive nerve may be in action alone. But it is possible for fibrils in a state of activity to communicate a similar state to neighboring ones. This, which is effected at the central extremities of the fibrils, and of which the result is an extension of the original sensation, is called, irradiation of sensations.

The retina is prone to such irradiations of sensations. Thus, if the eye be kept fixed for some time on a small strip of colored paper, lying on a sheet of white, the strip will after a time vanish for a moment. The circumferential part of the retina is more prone to irradiation of sensations than the middle part, but at the entrance of the optic nerve it is most so; in fact, the well known vanishing of images at this part in Mariotte's experiment is an exemplification of irradiation. It appears to be owing to irradiation that the spectrum of the retinal vessels is not in the ordinary exercise of vision seen.

An insensible spot of the retina, if small, may in consequence of irradiation not be seen, or at least not constantly seen, as a fixed musca.

On the other hand, weakened irradiation, which is an accompaniment of diminished sensibility of the retina, allows of small insensible spots of the retina to be more readily seen, as fixed muscæ; and appears to be the condition on which ocular spectra and complementary colors from retention of retinal sensations to a morbid degree, as well as muscæ volitantes (p. 325), depend.

Excitement of opposite conditions in contiguous parts of the retina.—A state of activity of one part of the retina, instead of exciting a similar, may excite an opposite state. Thus, as is well known, the brighter the light, the deeper the shadow. Another example is presented by the following experiment:—A small strip of gray paper lying on a sheet of red, after the eye has been fixed on it for some time, appears of a green color, the complementary color of the red ground.

In accordance with this law, an insensible spot of the retina, if large, occasions more distinctly the appearance of a black spot in the field of vision, or a fixed musca, the brighter the light.

Spectra consequent to impressions on the retina and complementary colors.

In the natural state, the sensations of the retina remain a short space of time after the impression which occasioned them has ceased to act. Hence, an image of an object may continue to be seen for some seconds after the eyes have been turned away from looking at it. This phenomenon is, in general, most readily observed in twilight; in daylight, the impression of the object on the retina requires to have acted more intensely and a longer time to produce the effect.

The spectrum appears when the eyes are directed to the sky, projected in the distance, and of gigantic size.

The spectrum is seen differently, according as the eyes, when turned away from the object, are darkened or directed to an illuminated surface. In the former case, the lights and shadows are the same as appeared at the time of regarding the object; in the latter, they are the reverse.

If the object from which the impression has been derived is colored, the spectrum is colored also, but differently, thus :—If the eye be fixed on a red colored object for some time, and then turned away from it, a spectrum of the object will continue to be seen, but, instead of a red, of a green color. If, on the contrary, the object looked at be green, the spectrum will be red; again, if blue, the spectrum will be orange; if orange, the spectrum will be blue; if yellow, the spectrum will be violet; if violet, the spectrum will be yellow.

From this it is seen that the color of the spectrum is always that which being added to the color of the object looked at, makes up the sum of the three prismatic colors, yellow, red, and blue, which, by their combination, form white light; hence, the name complementary which has been given to the color of the spectrum.

In the annexed figure the primitive colors yellow, red, and blue, are placed at the angles of the triangle, the compound colors, orange, violet, and green, at the intermediate points. The primitive color and the compound one, which thus stand opposed, viz., yellow and violet, red and green, blue and orange, are complementary of each other.

Fig. 70.

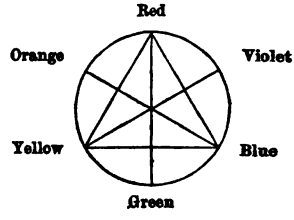

A spectrum is very readily produced, by looking at the setting sun. If on turning the eyes away they are darkened, the color of

the spectrum is at first luminous white; it then changes to yellow, and from that runs through the different colors of orange, red, violet, blue, to black, when the spectrum ceases. If, on the contrary, the eyes are directed to a white surface, the spectrum is at first black, then blue, which color is succeeded by violet, red, orange, yellow, until the spectrum, becoming white, is no longer distinguished.

In certain morbid states of the retina, even although vision be much impaired, the sensation remains after the impression a much longer time than natural; hence arise illusions of vision from the spectrum and complementary colors. In such a case, for example, if the person, after his eye has rested on some small and near object, the tassel of a blind, for example, should accidentally look towards the sky, he will see a magnified image of it; but not aware of the cause, he is astonished by what appears to him, a gigantic human figure in the air.

Section II.—Impairment and Loss of Sensibility of the Optic Nervous Apparatus, or Amaurosis in its various Degrees.

The sensibility of the retina is greatest in the region of the yellow spot (not in the situation of the foramen centrale as shown by Herschel, but to one or other side of it). From thence the sensibility diminishes towards the ora serrata.

In consequence of this, we see only that part of an object very distinctly, to which the axes of the eyes are at the moment directed. In examining an object, the axes of the eyes are so moved, that the central region of the retina may be successively impressed by the rays of light from its different parts.

The difference in the degree of sensibility of the middle and circumferential parts of the retina may be illustrated by a reference to the difference in the degree of sensibility of the skin of the lips, for example, and the skin of the cheeks. Whilst the points of the two legs of a pair of compasses, when separated a very short distance from each other, are applied to the skin of the lips, the mind distinguishes the two impressions; but when applied to the skin of the cheek, there is no distinct perception of two points, but a sensation as if one impression only were made.

As impressions on the less sensitive skin of the cheek are perceived, as if smaller than impressions on the more sensitive skin of the lips; so objects seen by the less sensitive circumferential part of the retina appear smaller than when seen by the more sensitive middle part; or *ceteris paribus*, an imperfectly illuminated object appears smaller than one brightly illuminated.

In amblyopy, objects appear smaller than natural, owing perhaps to the defective sensibility of the retina (*amaurotic micropy*).

Defective perception of colors.

Cases are recorded in which persons were unable, in different degrees, to distinguish certain colors, their sight in other respects being unimpaired. The colors most generally confounded were red with green, and pink with blue. Yellow and blue were the colors most readily recognized.

The affection appears to have been in most cases congenital and incurable.

Transitory hemiopy.

The following is an account of Hemiopy, by Dr. Wollaston, as it occurred in his own person:—"I suddenly found, after violent exercise, two or three hours before, that I could see but half the face of a man whom I met; and it was the same with respect to every object I looked at. In attempting to read the name JOHNSON over a door, I saw only SON; the commencement of the name being wholly obliterated to my view. The loss of sight was towards my left, and was the same, whether I looked with the right eye or the left. This blindness was not so complete as to amount to absolute darkness, but was a shaded darkness, without definite outline. The complaint was of short duration, and in about a quarter of an hour might be said to be wholly gone, having receded with a gradual motion from the centre of vision obliquely upwards towards the left."

More than twenty years subsequently, a similar attack occurred again, without Dr. W. being able to assign any cause whatever, or to connect it with any previous or subsequent indisposition. "The blindness," says he, "was first observed, as before, on looking at the face of a person I met, whose *left* eye was to my sight obliterated. My blindness was in this instance the reverse of the former, being to *my right* (instead of the left) of the spot to which my eyes were directed; so that I have no reason to suppose it in any manner connected with the former affection. * * * On this occasion the affection, after having lasted with little alteration for about twenty minutes, was removed suddenly and entirely by the excitement of agreeable news respecting the safe arrival of a friend from a very hazardous enterprise."

Such cases are not uncommon. I have myself twice experienced an attack. The first occurred some years ago in returning from a walk before dinner one hot day in summer. I felt exhausted, languid, and slightly giddy, but in other respects quite well. After

dining and drinking a glass of port wine and water, the hemiopy became somewhat alleviated, but did not entirely go off until after tea, having continued two or three hours. The second attack occurred some months ago, in consequence of gastric derangement.

In some persons, the affection is of frequent occurrence, coming on along with indigestion, headache and nausea, but going off in a few hours[1].

Admitting the doctrine of corresponding parts of the two retinæ as modified in the manner explained in the next chapter, and admitting the structural condition of their correspondence to be, in addition to semi-decussation of the optic nerves, some continuity between the fibres of the corresponding sides of the retinæ, we may, with Dr. Wollaston, consider the proximate cause of hemiopy to be some temporary affection of the brain at the origin of one or other optic nerve.

Treatment.—According as hemiopy depends simply on fatigue or gastric derangement, so must the treatment be regulated.

Night-blindness.[2]

Indistinct vision, recurring regularly at night, is sometimes met with as a congenital and habitual infirmity; there are instances of its having prevailed as an epidemic. Most frequently it is met with as an occasional complaint, especially in warm countries and warm latitudes at sea.

In the beginning of the complaint the patient is still able to see objects a short time after sunset, and perhaps to see a little by clear moonlight, and he can see distinctly by bright candlelight. Vision, however, becomes more and more imperfect at night, so that after a few days the patient can no longer discriminate the largest objects after sunset or by moonlight, &c.; and after a longer lapse of time, he ceases to see any object distinctly by the brightest candlelight.

The pupils move naturally during the day, but after sunset they become dilated, and contract sluggishly on exposure to light. Sometimes they are considerably dilated, both by day and night. In cases of long duration, the pupils are often contracted, and there are evident manifestations of intolerance of light.

Causes.—The principal causes of night-blindness appear to be fatigue and exposure to the strong light of the sun and gastric de-

[1] The case of a friend of his, which Dr. Wollaston describes, does not appear to be of this kind, but a case of common incomplete amaurosis. The blindness came on after the patient had suffered severe pains in his head for some days, about the left temple, and towards the back of the left eye; his vision became considerably impaired, attended with other symptoms, indicating a slight compression on the brain.

[2] Cæcitas nocturna. The words *hemeralopia* and *nyctalopia* have been differently used by authors; some expressing by hemeralopia night-blindness, and by nyctalopia day-blindness; whilst others have employed the words in an opposite sense.

rangement; lunar influence is also considered to operate as a cause. I have met with two cases apparently arising from exposure of the eyes to naphtha vapor. The following is one of the cases:

A lad aged 17. Has been working for the last fortnight with shell-lac, naphtha, and gutta percha. Since then he finds that his sight, which is perfectly good during the day, becomes regularly dim at night.

Congenital night-blindness has been known to affect more than one member of the same family. An instance of this kind has come under my own notice. A most remarkable history of a hereditary night-blindness, which has prevailed in one family for two centuries, has been recorded by M. Cunier.[1] The following case came under my notice not long ago:

A coachman, about 30 years old, whose brother has been affected with night-blindness from birth, has himself been, for the last two months, incapable of seeing his way in driving when night came on. His health is good. His eyes look natural—pupils obedient to the light.

Prognosis.—Under proper treatment the prognosis may be always favorable. The duration of the disease is generally from two weeks to three or six months. If, however, it be neglected or mistreated, vision may become imperfect in the day-time as well as at night. In some cases, the disease has terminated in total blindness.

Europeans who have been once affected with night-blindness, are particularly liable to a recurrence of the complaint as long as they remain in tropical climates.

Treatment.—The remedies to be first had recourse to are those adapted for the removal and alleviation of any general complaint, of which the night-blindness may be symptomatic. If gastric derangement, for example, emetics and purgatives are to be prescribed. If after the removal or alleviation of the general complaint, the night-blindness has not of itself gone off, a succession of blisters to the temple has been found a most efficacious remedy.

In some cases it may be advisable to take blood by cupping or leeches from the neighborhood of the eye. During the treatment, the eyes are to be kept shaded, and occasionally bathed with cold water.

In the case of the coachman above mentioned, the sight became so much improved under the use of alterative doses of mercury, continued for three months, that he came to see pretty well at night. A spectrum, however, made its appearance before the right eye—at first in the form of a spot the size of a pea, dark by day, bright and starry looking by night, by day in the form of a flickering flame.

[1] Annales de la Société de Medecine de Gand. 1840.

Day-blindness.

The photophobia, which persons accustomed to dark residences, albinoes, and children laboring under scrofulous ophthalmia, experience when exposed to strong daylight, does not merit the appellation of day-blindness, understood as the counterpart of night-blindness. In this sense it does not certainly appear that there is any such disease as day-blindness.

In amaurotic amblyopia, though the patient does not see well either by day or night, it happens in some cases that he sees proportionally better at night.

Fixed muscæ.

These appearances never change their position, either in regard to each other, or to the optic axis. Their motion is thus merely apparent, depending on the motion of the eyeball. But it often requires some attention and power of observation on the part of the patient to distinguish what is real from what is apparent motion.

Fixed muscæ vary in number, size, and form. At first semi-transparent, they afterwards become black, or at least dark. They appear in reading, like blotches on the paper, but when the eyes are directed to a distant object, they appear so large that they cover it perhaps. Fixed muscæ are most distinct in the light, in darkness they are either not seen or seen as luminous appearances. If confined to one eye they are most distinct when the other eye is closed.

Fixed muscæ are owing to insensible spots on the retina. The centre of the retina is sometimes the part affected, and the appearance seen is that of a dark spot in the middle of the field of vision. Thus the flame of a candle is, perhaps, invisible, whilst the light halo around is seen.

The appearance of a skin with veins in it, above referred to (p. 104), differs from the vascular spectrum as seen in Purkinje's experiment, inasmuch as it is owing to insensibility of the retina from the pressure and opacity occasioned by the congestion and exudation in inflammation of its vascular layer. It therefore belongs to the present head of fixed muscæ. Muscæ may change in form, size, and darkness; and though any given muscæ may not alter its position, it may disappear whilst others may present themselves in another part of the field.

The insensible spots on the retina on which the appearance of fixed muscæ depends, constitute partial amaurosis; this may pass into total amaurosis, the insensible spots gradually increasing in size until objects are no longer seen.

AMAUROSIS.[1]

Amaurosis considered empirically.

Amaurosis is impairment or loss of vision from disease of the optic nervous apparatus.

Different degrees of amaurosis.—Amaurosis is said to be *incomplete* or *complete*, according as the sensibility for visual impressions is impaired merely, or quite lost; and *partial* or *total*, according as the impairment or loss of sensibility affects a part only, or the whole retina.

In incomplete amaurosis, the patient's field of vision is obscured as if a gauze or cloud were interposed between him and the objects looked at.

In partial amaurosis, the obscurity may involve the centre or the circumference of the field, or some one side only; or it may be limited to a mere spot, or to several spots dispersed throughout the field. Objects are thus seen or not, according to the part of the field of view in which they are situated; or if large enough to occupy the whole field, their circumferential or central part only is seen, or one half only (*visus dimidiatus*), or a part here and there (*visus interruptus*). When the insensibility is limited to a spot or spots merely, the appearance of fixed muscæ is occasioned (p. 335).

Peculiarities of amaurotic vision.—Vision is often better one day, worse another; sometimes better in the morning, sometimes in the evening; sometimes better after meals, sometimes worse.

The amaurotic person generally sees an object indistinctly, until such time as he has steadily fixed his eyes on it (*visus iridescens*). Sometimes, however, by moving the object before him, he sees it better than when at rest.

Objects sometimes appear smaller (*amaurotic micropy*) (p. 332).

The patient usually sees better in strong light, but in some cases, better in dull light. Sometimes he is intolerant of light, even when the amaurosis is complete.

In some cases the patient sees distant objects better than near; in other cases again, near objects better than distant; and sometimes he sees objects multiplied with one eye, and iridescent: the flame of a candle, for instance, spreading out into rays, and surrounded by colored halos.

Subjective visual sensations.—Photopsy, chroopsy, and the undue retention of impressions, giving rise to ocular spectra and accidental colors, are frequent attendants on amaurosis. The gauze or net-

[1] Gutta serena of the Arabians, in contradistinction to *gutta opaca*, the name they gave to cataract.

work seen in the light may still be visible in the dark; but instead of being gray or black, it is of a silvery or gold color.

Common subjective sensations.—Uneasy feelings or actual pain in the eye or head, may or may not have been, or be present. Dryness of the eyes and nostrils is sometimes felt.

Double vision, confusion and distortion of objects, sometimes occur early in the disease, from some degree of attending strabismus. A similar disturbance of vision may occur without evident strabismus or loss of correspondence of the axes of the eyeballs, but in consequence of loss of correspondence of the vertical and horizontal diameters of the eyeballs, from disturbance of the harmonic action of the oblique muscles. The nature of such disturbance of vision is ascertained by closing one eye, whereupon vision with the other is improved.

Objective symptoms.—The defective and disturbed vision may be the only symptoms present. There may be no objective symptom, even the staring appearance of the eyes, and their want of power to converge on an object with precision, may be absent in incipient cases. In general, however, there are objective symptoms enough to indicate the nature of the affection, and to confirm the patient's statements.[1]

The pupil is more or less dilated, and if not quite immovable, its movements are limited and slow. This, although one of the most characteristic appearances presented by the amaurotic eye, is not constant. In cases in which one eye only is affected, the pupil often moves quite naturally, consentaneously with the pupil of the healthy eye; but if this latter eye be covered, whilst the amaurotic eye is examined under the influence of different degrees of light, then the pupil of the amaurotic eye is found to remain dilated and fixed, uninfluenced by the degree of light. Sometimes again, in complete amaurosis of both eyes, the pupils are as obedient to changes in the degree of light, as in health (p. 306).

Besides the peculiarities of the pupil just considered, there may be deformity of it from greater dilatation towards some one or other side, or even a displacement of the pupil, and the iris may be inclined towards the cornea, or its pupillary margin reverted backwards from the cornea.

Sometimes the pupil is much contracted (p. 306).

There is often an appearance as if of opacity behind the pupil, deep-seated, analogous to the appearance in glaucoma, but pale, and not so well marked. It is to be remarked, however, that this appearance, in an equal degree, may sometimes be seen in elderly persons, whose vision is quite good; and on the other hand, nume-

[1] The general aspect of the amaurotic patient is above sketched (p. 38).

rous cases of amaurosis, and this of the most complete kind, present no such appearance of opacity, but a clear black pupil.

In uncomplicated amaurosis, the catoptrical lenticular images are distinct.

Congestion of the conjunctiva, or, on the contrary, great paleness of it, lacrymation or dryness of the eyes, too great hardness, or too great softness of the eyeball, increased prominence, strabismus or paralytic luscitas, and rolling of the eyes, may, in different cases, be accompaniments of amaurosis.

General symptoms.—Symptoms of intercranial disease often attend amaurosis, such as pain in the head, constant, intermittent, or periodic, and varying in seat, extent, and nature; vertigo, tinnitus aurium, tendency to coma, sleeplessness, &c.

The digestive organs are sometimes deranged, sometimes not.

The pulse may be strong, or weak, or natural.

Such are the principal symptoms which may attend amaurosis. Some, it will be observed, are altogether the contrary of others, so that not one alone can be admitted as pathognomonic, scarcely even the defective vision itself.

These differences in the phenomena depend partly on differences in the nature of the morbid condition on which the loss of sensibility depends, partly on the development of that morbid condition. For the same reason the invasion and progress of the disease differ in different cases.

Invasion and progress.—The invasion of the amaurosis may be sudden or gradual. In the former case, vision may be at once wholly lost, or nearly so, in the latter case, it may be only after a time that the vision is seriously impaired. In some cases the impairment of vision remains at a certain stage without advancing, in other cases it continues to increase, the obscurity thickening and spreading, until the whole field of vision is obliterated to the sense, the perception of light lost, and the amaurosis complete. Sometimes amaurosis commences as night-blindness.

Except when the cause is of a purely local nature, both eyes generally become affected; one eye first perhaps, and by-and-by the other. The blindness being complete and total in one eye, some degree of vision may still be retained in the other.

Constitution, and previous disease of the patient.—Amaurotic patients are met with in all constitutions, and are found to have been the subjects of very different diseases, and yet these diseases will often appear to have had some connection, either as cause, or as themselves depending on the same cause with the amaurosis, and may still require to be taken into consideration along with the present state of general health of the patient, in determining the kind of treatment to be had recourse to.

The diseases, the previous existence of which is often found to have some connection with the amaurosis, either as cause, or as depending themselves on the same cause, are scrofula, syphilis, gout, rheumatism, dyspepsia, hypochondriasis, hysteria, apoplexy, epilepsy, paralysis, phrenitis, typhus fever, lead poisoning, &c.

In some cases the disease is found to occur in connection with disturbed menstruation, hysteria, pregnancy, during labor, hæmorrhoids, and again to disappear entirely, but again to occur, and then perhaps to remain permanently.

Causes.—The paralysis of the optic nervous apparatus, on which amaurosis depends, may be the result of morbid conditions of that apparatus, differing both as regards nature and seat.

As regards nature, they may be congestion, or inflammation and its consequences; nervous exhaustion; or pressure by neighboring parts. As regards seat, this may be in the retina, or the optic nerve, or the cerebral portion of the optic nervous apparatus.

Diagnosis in general.—Amaurosis in its incipient stage especially, ought to be carefully distinguished, for this is in general the only stage at which treatment is likely to be of much avail.

The affections from which amaurosis requires to be distinguished are principally: Cataract, mydriasis, myopy, presbyopy, asthenopy, muscæ volitantes, night-blindness, glaucoma. See those different articles.

Amaurosis is, however, often complicated with some one or other of these affections.

The distinction of incipient amaurosis from incipient cataract, is of especial importance, as supposing incipient amaurosis mistaken for incipient cataract, it might be allowed to go on unchecked, under the impression that ripening of the cataract was taking place. The patient would thus be deprived of all chance of the benefit which might be derived from treatment in rescuing him from irretrievable blindness.

Prognosis.—The prognosis in a decided case of amaurosis is most unfavorable. The disease, when it comes on suddenly, even when complete blindness is present, is not unfrequently relieved or cured, if it has not already existed long. The disease which has come on gradually, accompanied by pains in the head, is more hopeless in general, as in this case the cause most usually is material disorganization of some part of the optic nervous apparatus; whereas, sudden cases may be owing to some congestion, extravasation, or exudation, admitting of removal by timely treatment.

The prognosis is decidedly bad, when the eyeball is either preternaturally hard or soft, or affected with cataract; or if the disease is hereditary, or complicated with epilepsy, paralysis of some part indicating affection of the brain, &c.

In cases in which one eye only is affected, there is reason to fear for the other.

Amaurosis considered pathologically.

Seat of the morbid conditions of which paralysis of the optic nervous apparatus may be the result.—The retina, the optic nerve, or that part of the brain with which the optic nerve is connected, may be together or separately the seat of the morbid condition on which the amaurosis depends. If the retina only be affected, it cannot receive the impression which should be transmitted by the optic nerve to the brain; if the optic nerve only be affected, it cannot transmit the visual impression from the retina to the brain; if that part of the brain with which the optic nerve is connected, be alone affected, the sensorial power to take cognizance of the visual impressions transmitted by the optic nerve is lost.

Thus, the general result is the same, whether the different parts of the optic nervous apparatus be affected together or separately. Notwithstanding this, it is of importance practically to determine as accurately as possible the seat of the morbid condition on which the loss of vision in any given case depends.

Nature of the morbid conditions of which paralysis of the optic nervous apparatus may be the result.—In the first place, it is to be observed, that paralysis of the optic nervous apparatus, like paralysis of other parts of the nervous system, may occur without any morbid condition, the nature of which is appreciable, either by particular symptoms during life or by anatomical examination after death. Generally, however, there are symptoms and other circumstances of the case during life, or appearances after death, sufficient to account for the paralysis. In regard to appearances after death, however, it is to be observed that many of the morbid conditions in which the optic nervous apparatus has been found in cases of amaurosis, though of themselves very efficient causes of paralysis, and irremediable, are not to be viewed as standing in the relation of original cause of the paralysis, but rather as the effect, or, at the least, as the coincident effect of the morbid condition which was the immediate cause of the paralysis. To such morbid conditions may be referred, hardening or softening of the brain, of the optic nerve or retina, atrophy, thickening or other enlargement (which may be followed by atrophy).

The morbid conditions, acting as the immediate cause of paralysis of the optic nervous apparatus in amaurosis, are in their nature essentially the same as those which act as the immediate cause of paralysis of other parts of the nervous system, and may be referred to the two principal heads of intrinsic and extrinsic.

Intrinsic morbid conditions of the optic nervous apparatus act-

ing as causes of its paralysis in amaurosis.—These may be at first inflammation or simple congestion of some part or the whole optic nervous apparatus, and as effects of this, exudation of serum or lymph, or extravasation of blood. Or the opposite condition of a defective supply of blood to the parts, followed by marasmus.

These morbid conditions, it is to be observed, may be confined to the optic nervous apparatus, but extend to the brain generally, in which case the amaurosis will form a point of inferior consideration.

Morbid conditions extrinsic of the optic nervous apparatus acting as causes of its paralysis in amaurosis.—These operate by *pressure* on the optic nervous apparatus. To them belong abscesses of the brain, hydrocephalic collections, tumors, &c., of the brain or its membranes, aneurismal affections of the cerebral or ophthalmic arteries, exostosis, &c., of the bones of the cranium or orbit, abscesses in the orbit, tumors in the orbit, or in the neighboring cavities and sinuses of the skull or face, affections within the eyeball, as inflammation of the choroid, hydrophthalmic collections, and the like.

Eventually the pressure may produce organic change of the optic nervous apparatus.

It will be observed that many of these morbid conditions are of such grave importance in themselves, that the amaurosis produced by them forms but a secondary consideration in the case.

Both intrinsic and extrinsic morbid conditions of paralysis in amaurosis may coexist. Examples readily suggest themselves. To take one from the eyeball, besides inflammatory or simple congestion of the retina, there may be a similar state of the choroid producing pressure on the retina.

Morbid conditions of the retina on which the paralysis in amaurosis may depend—Intrinsic.—Vascular congestion of the retina or choroid, or both, simple or inflammatory, acute or chronic, and, as the consequence of it, extravasation of blood, degeneration of the structure of the retina (see *Posterior Internal Ophthalmia*), thickening, atrophy, softening, adhesion between the retina and choroid, &c. Injuries, whether direct wounds, or the lesion, whatever its nature may be, produced by concussion, or by a sudden glare of intense light, or by over-exertion of vision.

Extrinsic, but still seated within the eyeball.—Inflammation or congestion of the choroid and its consequences. Subsclerotic dropsy, vitreous dropsy, hæmophthalmus, displaced lens. Inflammation of the choroid may thus act, both by producing disorganization of the retina, and giving rise to pressure on it.

The morbid conditions extrinsic to the retina and seated without the eyeball, are, for the most part, the same as the extrinsic morbid

conditions to which the orbital portion of the optic nerve is subjected.

Morbid conditions of the optic nerve on which the paralysis in amaurosis may depend—Intrinsic.—Direct injury of the optic nerve.—Congestion, simple or inflammatory, and as general or partial induration or atrophy,—thickening of the sheath and exudation between it and the nerve. Tumors attached to or contained within the sheath or involving the substance of the optic nerve, including medullary or melanotic disease. Aneurismal enlargement of the central artery of the retina while within the optic nerve. Extravasation of blood in the same place.

Extrinsic.—These necessarily come under two separate heads, viz., those to which the orbital, and those to which the intracranial portion of the optic nerve is subjected.

The latter will come under the more general head of extrinsic morbid conditions affecting the intracranial portion of the optic nervous apparatus; the former therefore alone fail to be enumerated here.

Inflammation and abscess in the orbit; exostosis of the orbital bones; tumors in the orbit or neighboring cavities; fractures of the anterior part of the base of the skull or of the orbit.

Morbid conditions of the intracranial portion of the optic nervous apparatus on which the paralysis in amaurosis may depend—Intrinsic.—Injuries—concussion, laceration; congestion—simple or inflammatory, and its effects, hardening or softening, hypertrophy or atrophy, abscess, &c.; apoplexy; scrofulous tubercles; tumors of different kinds; hydatids.

These morbid conditions may implicate other parts of the brain at the same time.

Extrinsic.—Fracture of the cranium with depression or extravasation of blood in the situation of the intracranial portion of the optic nervous apparatus; exostosis of the bones of the cranium in the same situation; tumors of the dura mater; inflammation of the membranes of the brain, and its consequences, adhesions, thickenings, depositions of serum, lymph, pus, &c.; hydrocephalus, superficial or ventricular; tumors of the brain, implicating the optic nervous apparatus by pressure, such as enlarged pituitary, or pineal gland; aneurism of one of the encephalic arteries.

Of these different morbid conditions, it is to be observed, that many of them are well-marked and recognized forms of disease in the rational pathological sense, the amaurosis being at once recognizable as a symptom merely. Others again, are not so recognizable during life, and the blindness being the prominent symptom, the case is said to be one of amaurosis in the empirical sense.

Causes of the different morbid conditions of the optic nervous

apparatus in amaurosis.—These may be said to comprehend the remote causes of disease in general, in addition to such as act on the eyes in particular.

Amaurosis considered therapeutically.

The nature of the morbid condition on which the amaurosis depends, and the causes which may have excited that morbid condition, are points which must be ascertained before any rational mode of treatment can be determined on. In numerous cases, however, it must be confessed that these points cannot be satisfactorily determined; the treatment adopted must, therefore, be partially empirical and partly founded on general indications.

The different morbid conditions on which amaurosis may originally and essentially depend are, it has been above seen, referable to the three following principal heads:

1. Congestion of the optic nervous apparatus and its effects.
2. Exhaustion of the optic nervous apparatus.
3. Pressure on some part of the optic nervous apparatus.

These conditions, however, it is to be observed, may be more or less mixed up with each other, or one may supervene on the other; hence, according as one or other appears to be in operation at the time, so must be the treatment.

Amaurosis from congestion of the optic nervous apparatus.—The causes to which congestive amaurosis is owing are very various. Exposure of the eyes to strong heat and light in those who work before large fires, &c. Over-exertion of the sight. Forced exertions of the body while stooping the head, especially in plethoric or drunken persons. Pregnancy. Sudden suppression of discharges—the menstrual, perspiratory, hæmorrhoidal, purulent, &c. Gastro-hepatic, or gastro-intestinal irritation, as in dyspepsia, scybala, worms. Irritation of the nerve of the fifth pair. Passions of the mind. Fevers.

Prognosis and treatment.—The cases of amaurosis under consideration, if early seen, are in general those in which treatment may be undertaken with most hope of advantage, provided—and this is the first point to which attention must be directed—the causes just enumerated can be avoided, removed, or mitigated.

The plan of treatment is, first, the general antiphlogistic plan above described (p. 110, et seq.), consisting principally of bleeding and mercurialization, and afterwards the tonic and alterative, together with counter-irritation (p. 112).

If the disease has already fallen into a chronic state, the tonic and alterative plan of treatment, with counter-irritation, may be the only one admissible.

Amaurosis from exhaustion of the optic nervous apparatus.—Exhaustion of the optic nervous apparatus is often a mere accompaniment of general nervous exhaustion, arising from great loss of blood, or excessive discharge of secretion, as in protracted suckling, seminal losses, especially by onanism, or arising from grief and other depressing passions—from low nervous fevers, fright, &c.

Prognosis and treatment.—In the cases depending on exhaustion of the nervous system, the prognosis is much less favorable than in those depending on congestion.

The plan of treatment fitted for them is the tonic and alterative (p. 112), in prolonged courses.

It is in this form of amaurosis that strychnia and veratria, endermically applied, have been much recommended; but their efficacy has not been satisfactorily established. The same must be said of electricity and galvanism, and stimulating vapors to the eyes.

The amauroses which arise from super-excitation occasioned by sudden strong impressions on the retina, such as an intense glare of light falling on the eye, concussion of the eyeball, or a stroke of lightning, and also those arising from overplying vision, appear to depend partly on nervous exhaustion, and partly on congestion. For example, the spot of the retina acted on by a sudden glare of light, or by smart concussion from a blow, is at once rendered insensible, and the result is a fixed musca, which may ultimately go away or remain; or the whole retina may become insensible, though this more generally takes place slowly, as a consequence of supervening congestion or inflammation.

In such a case, the treatment should be the same as for congestive amaurosis.

Amaurosis resulting from pressure on some part of the optic nervous apparatus.—In many such cases the amaurosis is but a secondary consideration, more pressing symptoms of the organic disease being present; in other cases the amaurosis may be the only or principal appreciable symptom.

Prognosis and treatment.—Except when the cause of pressure is seated in the orbit or in the eye, and is removable by operation, any treatment adopted must be regulated according as the general symptoms agree with one or other of the preceding forms, consisting in the one case, of bloodletting and mercurialization, in the other of tonics, alteratives, and counter-irritation. When, as is often the case, it cannot be determined what is the nature of the cause of pressure, or even that the case is one of pressure, the treatment must still be regulated by the same principle.

Section III.—Glaucoma and Cat's Eye.

GLAUCOMA.

Glaucoma is a name applied to a peculiar greenish opaque appearance, deep behind the pupil, changing its seat according to the direction in which the light is admitted, being always most concentrated on the side opposite the light. This appearance occurs in very different degrees, from a greenish reflection barely discernible to a grass-green opacity.

Hippocrates and the ancient Greeks comprehended under the name of *glaucoma* every kind of opacity which appears behind the pupil. The later Greeks, as Rufus, Galen, Paul of Egina, and others, however, restricted the term to the incurable opacities behind the pupil, while to the curable, they gave the name of *hypochyma:* the former they supposed to be a disease of the lens, the latter to be a concretion in front of the lens.

Brisseau[1] appears to have been the first who gave out the opinion, that while cataract, as first shown by Rolfink, Borel, and others, is an opacity of the crystalline body, glaucoma is an opacity of the vitreous.

By some the appearance of glaucoma has been supposed to be owing to reflection from the bottom of the eye, in consequence of the morbid state of the retina and choroid, with loss of pigment, which often exists in glaucoma.

It was, however, satisfactorily demonstrated by Dr. Mackenzie, in 1828, that the cause of the glaucomatous appearances resides in the lens.

The change in the state of the lens, on which the glaucomatous appearance depends, consists in its having become, especially in its central part or kernel, colored—more or less deep amber when viewed by transmitted light, green when viewed by reflected light. The lens usually retains its transparency unimpaired, except in so far as the depth of color interferes with it, but it may become at the same time more or less opaque.

The proofs adduced by Dr. Mackenzie that the cause of the glaucomatous appearance resides in the lens, are the following:

1. On removing the lens by operation from a glaucomatous eye, the pupil no longer presents the glaucomatous color, but appears black, as natural.

2. On dissection of glaucomatous eyes, he found the lens, especially its central part or nucleus, of a yellow, amber, yellowish-red, or reddish-brown color, when viewed by transmitted light; greenish when viewed by reflected light.

[1] Traité de la Cataracte et du Glaucome. Paris, 1709.

In demonstration of the different degrees of opacity of the lens which may exist in the different stages of glaucoma, Dr. Mackenzie was the first to apply the catoptrical test (p. 240).

Along with a glaucomatous appearance behind the pupil, vision may still be good, or it may be defective or totally lost. In the latter case, the defective vision may be owing in part to the deeply colored nucleus of the lens intercepting the rays of light in the manner of cataract, or to actual cataractous opacity coexisting, but in most cases it is owing to complication with insensibility of the retina.

From this it may be inferred, that the glaucomatous state of the lens occurs in diseased states of the eye, essentially different from one another. Hence, if we take glaucoma as a genus, the principal species are as follows:

1. *Simple glaucoma.*
2. *Glaucoma with cataract.*
3. *Chronic glaucoma with amaurosis.*
4. *Chronic glaucoma with amaurosis and cataract.*
5. *Acute glaucoma with amaurosis.*

Simple glaucoma.

Here we have the glaucomatous appearance behind the pupil, but the eye, in other respects, appears quite healthy—the cornea clear, the pupil lively, the consistence of the eyeball normal, and vision—with the exception that it may be presbyopic or myopic—good.

Simple glaucoma is of frequent occurrence in old people. It continues for life, but does not necessarily become complicated either with cataract or amaurosis.

Simple glaucoma with cataract.[1]

In this species of glaucoma, the green reflection from the glaucomatous nucleus of the lens, is seen somewhat obscured by the cataractous whiteness of the surface. The retina is sound, but, as is usual at the advanced period of life when this species of cataract occurs, the vitreous body is more or less dissolved.

This form of glaucoma does not essentially differ from the kind of hard cataract above noticed (p. 235).

Treatment.—As was first pointed out by Dr. Mackenzie in 1828, the operation for cataract may be performed with success in cases of simple glaucoma with cataract. But this is the only species of glaucoma in which an operation for the removal of the lens is

[1] Simple glaucomatous cataract—green cataract in the limited acceptation.

admissible. The operation may be by extraction or reclination [or division], according to the circumstances of the case (p. 237).

Chronic glaucoma with amaurosis.

This, which is the species of glaucoma generally taken as the type of the disease; is identical with chronic arthritic posterior internal ophthalmia (p. 172, et seq.)

The eyeball is hard to the touch from dissolution of the hyaloid, and superabundance of vitreous humor. The sclerotica is attenuated and dark-looking; the white of the eye pervaded by varicose vessels; the cornea often slightly nebulous and rough; the iris pale and inclined towards the cornea; the pupil, at first limited and sluggish in its motions, becomes dilated—generally ovally dilated—and fixed; the peculiar glaucomatous appearance behind the pupil well marked.

Vision is impaired or lost.

In addition to the defective vision, there are muscæ and fiery and colored spectra before the eyes, and not unfrequently more or less severe pain in the forehead, supra-orbital regions, temples, or face, of a rheumatic or gouty character.

Both eyes are usually affected, but one may be less so than the other.

The characters above given (p. 235), as distinguishing glaucoma from cataract, are those of this form of glaucoma.

The disease is incurable.

Chronic glaucoma with amaurosis and cataract.[1]

This is an advanced stage of the preceding form of glaucoma. The eye is now quite insensible to light, but photopsia and pains around the orbit may continue.

The pupillary margin of the iris is perhaps retroverted, and the lens, now become cataractous in its external substance and hypertrophied, protrudes through the dilated pupil into the anterior chamber, and even comes to press on the cornea. The cornea may in consequence ulcerate, and the lens be evacuated with hæmorrhage. Eventually the eye becomes atrophic and quiet.

Acute glaucoma with amaurosis.

This is identical with acute arthritic posterior internal opthalmia above described (p. 172, et seq.)

CAT'S EYE.

This term has been applied to cases of amaurosis, in which there is a reflection from the bottom of the eye similar to that in the

[1] Cataracta glaucomatosa of Beer.

cat; but the appearance is by no means characteristic of any one disease of the eye.

Beer, who introduced the term, and who describes cat's eye as the type of his second class of forms of amaurosis, viz., that characterized not only by subjective, but also by objective symptoms, mentions having met with it most frequently in old persons inclined to marasmus, but sometimes in young persons, especially cachectic adults and atrophic children; he had also seen it after injuries of the eye.

The reflection from the bottom of the eye, occurring after injuries, has been above explained (p. 219, et seq.), and appears to be quite different from the condition, whatever it may be, which gives rise to the appearance in old persons.

CHAPTER VI.

Section I.—Loss of Correspondence of the Sensations and Movements of the Two Eyes.

As an introduction to the present subject, the correspondence which naturally exists between the sensations and movements of the two eyes, requires to be taken into consideration.

Correspondence between the sensations of the two eyes.

It has been above shown (p. 329, et seq.) that the different parts of the same retina exert an influence on each other's sensations. The two retinæ, it is here to be shown, likewise exert an influence on each other's sensations, but to a much greater and more striking degree.

When the two retinæ are impressed in a similar manner at the same time, the resultant sensation is much stronger than when one eye only is employed. If the impression on one retina be indistinct, whether from suffusion of the transparent media of the eye or from impaired sensibility of the retina, the indistinctness of vision which results, is not so evident when the other eye is used at the same time, as when the affected eye alone is used.

When the two retinæ are affected in a dissimilar manner at the same time, the mind does not perceive an admixture of the two sensations, but perceives the sensation of one of the retinæ only at the same instant of time. Sometimes the one, sometimes the other. Thus, if one eye be closed, and the other be directed staringly

towards the window, for example, by-and-by it will be found that darkness will now and then momentarily overspread the open eye.

But the phenomenon is observed in a much more marked manner, when a different color is presented to each eye;[1] blue to the one, yellow to the other, for example. In this case, an admixture of the two colors, viz. green, is not seen, but either the blue alone or the yellow alone; sometimes the one, sometimes the other, or the blue in part and the yellow in part.

If the dissimilar impressions, it is to be observed, affect parts only of the two retinæ, they are perceived separately, unless the parts of the two retinæ which are simultaneously affected, be their vertices or the various parts equally situated in relation to them on the temporal side of the one retina and on the nasal side of the other, or on the upper parts or the lower parts of the two retinæ. These parts are therefore called corresponding or identical parts.

This may be illustrated by viewing two different colored wafers, thus: Place the wafers one on the right hand, the other on the left, at such a distance from each other that their centres may be about one inch and three quarters from each other. Hold a board (the board of an octavo book, for instance) between the eyes in front of the nose, and look at the wafers in such a way, that the right hand one is seen by the right eye only, and the left hand one by the left eye only. The two wafers are soon seen as if to approximate, and then to run into one or to cover the one the other. This is owing to the eyes so moving, that the images of the two wafers come to be projected on corresponding or identical parts of the two retinæ.

It thus appears that dissimilar impressions on corresponding parts of the two retinæ cannot be perceived by the mind at the same instant of time, but only the one sometimes, the other sometimes; though, if the impression on the one retina be much the stronger, it decidedly predominates over, or excludes that on the other.

Single vision with two eyes.

An object viewed with both eyes is seen single only when the optic axes intersect at some point of the object, when the centres of revolution of the two eyes coincide, and when their horizontal and vertical diameters are respectively parallel. Besides the object at which the optic axes meet, other objects to the side of it appear single, provided they are situated in, or within certain limits only, out of an imaginary circular line, or rather spherical surface, called the *horopter*, which runs from the point of intersection of the optic

[1] A different color may be presented to each eye by looking through glasses of a different color at a white object.

axes through the points of intersection of the lines of visual direction in the two eyes.

The correspondence in the direction of the axes, the coincidence of the centres of revolution, and the parallelism of the horizontal and vertical diameters of the two eyes depend on the normal action of the muscles of the eyeballs, which will be considered below.

It is in order that the images of the objects may be simultaneously projected on identical or corresponding parts of the two retinæ, that the correspondence in the direction, &c., of the two eyes is necessary; for a single visual perception from a simultaneous impression on each retina results only when that impression affects corresponding or identical parts of the two membranes (p. 349.) If other parts of the two retinæ than these be simultaneously impressed, the object is seen double.

Whether the faculty by which a single visual perception results from the simultaneous affection of certain parts of the two retinæ be connate and dependent on the organization of the optic nervous apparatus, or whether it be a mere matter of experience or association, is a question.

The former view is that which appears best grounded, but the organic condition on which the faculty depends, has not been exactly determined. In a general way, however, it may, as above observed (p. 333), be said to consist in the semi-decussation of the optic nerves, and some continuity between the fibres of the corresponding sides of the two retinæ.

The corresponding parts of the two retinæ have been commonly considered to be, or, at least, have been called *points*. As thus understood or expressed, however, the doctrine is not quite correct; for it has been shown by Mr. Wheatstone,

1st, That images, differing in magnitude within certain limits, but in other respects similar, if projected on parts of the two retinæ, as nearly correspondent as may be, coalesce and occasion a single perception.

2d, That in viewing an object of three dimensions, while the optic axes converge, obviously dissimilar pictures are necessarily projected on the two retinæ, and yet the mind perceives but a single object, though not exactly like either of the pictures on the retinæ. This fact is beautifully illustrated by Mr. Wheatstone's experiment of simultaneously presenting to each eye, instead of the object itself, its projection on a plane surface as it appears to that eye.

For this experiment Mr. Wheatstone invented an instrument which he calls a *stereoscope*. It consists of two plane mirrors, with their backs inclined to each other at an angle of ninety degrees,

near the faces of which the two monocular pictures are so disposed that their reflected images are seen by the two eyes, each looking into one of the mirrors in the same place.

The experiment may be sufficiently well made by viewing the subjoined figures—the dissimilar perspectives of a truncated four-sided pyramid, in the same manner as the experiment with the wafers above described; viz.:

Fig. 71.

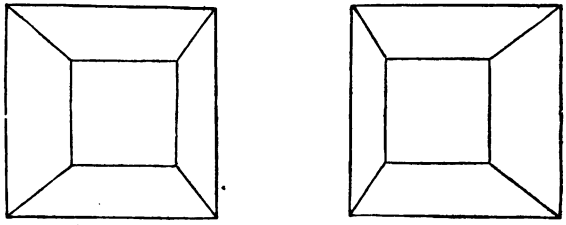

Fixing the right eye on the right hand figure, and the left eye on the left-hand figure, hold between the eyes in front of the nose the board of an octavo book. The two figures will be seen to approximate, and then run into one, representing the skeleton of a truncated four-sided pyramid in bold relief.

From this experiment Mr. Wheatstone has inferred too much, when he thinks that it overturns the doctrine of corresponding parts of the two retinæ—a doctrine which was held by Newton, Reid, Wollaston, and which is held by the best physiologists of the present day. Still it is, as above stated, not exactly in accordance with the doctrine as commonly expressed. The following observations, however, I believe, will be found to reconcile Mr. Wheatstone's experiment with the doctrine of corresponding points.

It has been above shown (p. 331, et seq.) that the degree of sensibility of the vertex or middle part of the retina is greater than that of the circumferential part; and in illustration of this, reference was made to the difference in the degree of sensibility of different parts of the skin, as demonstrated by the circumstance whether the mind distinguishes two impressions made on the skin close to each other, as two, or as one only.

In consequence of the correspondence and sympathy of the two retinæ with each other, above shown, it would be a sufficient condition for the perception of an object, if one part only—a half, for example, of its image were projected on the temporal side of one retina, the other half on the nasal side of the other retina. This shows that the two retinæ may be in a manner viewed as constituting one sensitive surface.

Hence, as in one and the same retina two impressions, affecting the vertex or middle part are still perceived by the mind to be two, though very minute and close to each other, so, unless impressions on the middle parts of the two retinæ be on corresponding points, they are perceived by the mind as two. But as in one and the same retina two impressions affecting the circumferential part may not be perceived except as one only, even though not very close to each other, so impressions on the circumferential parts of the two retinæ, though not on exactly corresponding points, are perceived by the mind as one only; and that much more readily than in the case of two impressions on the circumferential part of one and the same retina. It is to be observed, that it is not exactly either the one or the other impression which is perceived by the mind exclusively, but is in some measure a mean of the two.

Thus, though the mind perceives separate affections of neighboring non-corresponding points of the two retinæ situated in or near their vertex at the same instant of time, it does not perceive separately affections of the circumferential parts of the two retinæ, resulting from impressions on neighboring non-corresponding points. The distance between the neighboring non-corresponding points which are impressed, it is to be observed, being within certain limits.

In Mr. Wheatstone's experiment, it is that part of the object at which the optic axes intersect, the image of which is projected on the middle parts of the two retinæ. Now, of the perspectives of the objects which are projected on the two retinæ, this is the only part which is similar for the two eyes. It, therefore, falls on corresponding points, the condition necessary for a single visual perception, from an affection of the middle parts of the two retina.

It is, on the contrary, those parts of the object out of the horopter, the image of which, necessarily dissimilar for the two eyes, is projected on the circumferential parts of the retinæ—the very parts, affections of accurately corresponding points of which is not, as above seen, a necessary condition for a single visual perception.

According to this, if, when reference is made to the correspondence of the circumferential parts of the two retinæ, the expression *corresponding or identical compartments* be substituted for *corresponding or identical points*, and if the latter expression be employed only when reference is made to the correspondence of the middle parts of the two retinæ, then the doctrine of corresponding parts of the two retinæ, so far from being overturned, is confirmed and illustrated by Mr. Wheatstone's experiments.

Visual perception of the three dimensions of space.—All that can be perceived of an object of three dimensions by means of one eye may be represented on a plane surface, but it is not so in

regard to what can be seen of it by means of the two eyes with their axes in a state of convergence. In the former case, a *semblance* of solidity or depth is seen, and this is all that a picture can represent; in the latter case solidity or depth is perceived as *actually* as it may be by the touch of two fingers, and this is what a picture cannot represent. This is owing to the position of the two eyes, by which each is fitted to receive on its retina a different perspective of the object.

The mode in which this is effected by the two eyes is essentially analogous to the mode in which the third dimension is perceived by the touch. With the mere surface of the point of one finger we can take cognizance of length and breadth only, but with two fingers we can perceive thickness also. The two fingers admitting of being applied to different parts of the object, receive impressions of different perspectives, as it were, of it.

Natural double vision with two eyes.

It is to be remarked, that we do not see with the two eyes every object single; and the reason is, that the more projecting, for example, an object is, the more is some part of it out of the horopter, and therefore the more dissimilar are its perspectives to the two eyes. Now, when the pictures on the two retinæ are very dissimilar, the parts which ought to coalesce occupy places far beyond the limits at which points of the two retinæ are influenced by each other; and therefore an object such as a needle, for instance, looked at with one end directly towards us, is seen bifurcated or double.

Correspondence in the movements of the two eyeballs.[1]

A correspondence in the direction of the optic axes, coincidence of the centres of revolution, and parallelism of the vertical and horizontal diameters of the two eyes, it has been above shown, are necessary conditions, in order that the images of objects may be simultaneously projected on corresponding points and parts of the two retinæ; that they are therefore the remote conditions on which single vision with the two eyes depend. In the course of the movements of the eyeballs, these conditions must therefore be preserved.

The eyeball lies balanced, as it were, in the orbital capsule, and the movements which it is made to execute by the action of its muscles are revolutions merely around a certain point in its interior, the situation of which in the orbit, always remains the same when the movements of the eyeballs are natural.

[1] Ruete, Lehrbuch der Ophthalmologie für Aerzte und Studirende, Braunschweig. 1845.

As the eyeball revolves in all directions, it has three axes, on which it is made to revolve by its six muscles in as many different primary directions.

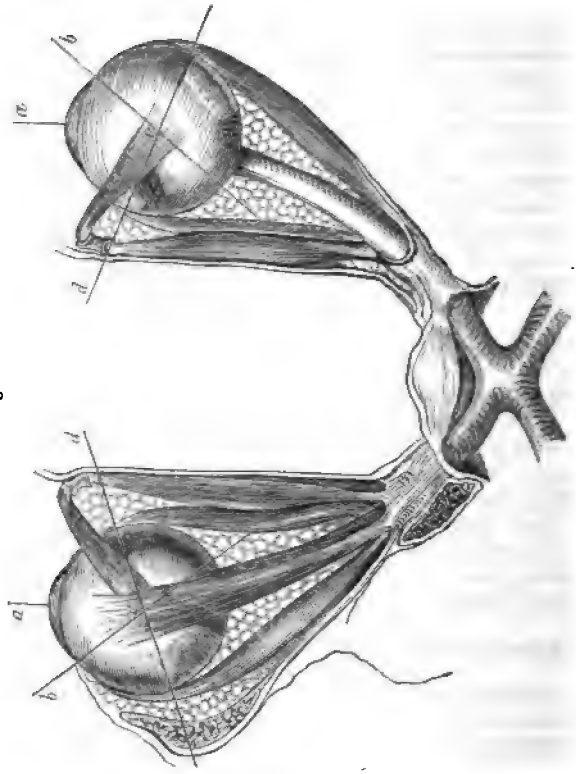

Fig. 72.

(From Ruete.)

The muscles seen from above are in a state of equilibrium; *a* the parallel optic axes; *c c* the centres of revolution; *b b* the axis of revolution for the oblique muscles; *d d* the axis of revolution for the superior and inferior recti.

Suppose the six muscles of the eyeball in a state of equilibrium by which the pupil is directed exactly forwards, and the optic axis is horizontal; then:

1st. The axis of revolution for the rectus externus and internus

is vertical, and coincides with the vertical axis of the eye. These muscles turn the pupil outwards or inwards.

2d. The axis of revolution for the rectus superior and inferior, inasmuch as these muscles proceed to the globe in the direction of the optic nerve, which intersects the optic axis at an angle of about twenty degrees, extends obliquely from before and inwards, somewhat backwards and outwards, and intersects the optic axis at an angle of about seventy degrees. The pupil is thus turned by the rectus superior upwards and somewhat inwards, by the rectus inferior downwards and somewhat inwards.

3d. The axis of revolution of the obliqui likewise extends horizontally through the eyeball, but nearly from the outer margin of the cornea backwards and inwards, and intersects the axis for the superior and inferior recti at an angle of about seventy-five degrees. Around this axis, when the optic axis is horizontal and directed forwards, the superior oblique turns the eyeball in such a way that the pupil is directed downwards and outwards, and the inferior oblique turns it in such a way that the pupil is directed upwards and outwards. The annexed figure (Fig. 72) represents these circumstances.

The oblique muscles turn the eyeball in the direction above indicated, only when the pupil is previously directed straight forwards, and all the muscles are in a state of equilibrium. But if, for example, the internal and inferior recti have previously directed the pupil downwards and inwards, then the superior oblique turns it still more inwards.

The four recti are antagonists of the two obliqui; the recti muscles pull the eyeball back, the obliqui forwards. The eyeball is in the sound state thus balanced.

If one of the four recti muscles be cut, the eyeball protrudes somewhat. When one of the oblique is cut, the eyeball sinks deeper in the orbit.

The two obliqui, with the external rectus, are antagonists of the superior, inferior, and internal recti.

By the mechanism just mentioned, assisted by the orbital capsule, the eyeball is balanced in such a way that when all the muscles are in equilibrium the optic axis is directed horizontally forwards.

The four recti rotate the eyeball in the vertical and horizontal directions. The obliqui, by rotating the eyeball on its outer or posterior axis, keep the vertical diameter of the two eyes always parallel though not vertical—one of the conditions necessary for single vision.

The internal rectus muscle of one eye, and the external rectus of the other, usually act together, so also do the superior recti of the two eyes and the inferior recti.

But when required for the purposes of vision the two internal recti act together, and so also may the two external recti in bringing the eyes from a state of strong convergence to a state of parallelism, but not of divergence.

In short, the different muscles of the two eyeballs act in various combinations, sometimes as fellows, sometimes as antagonists, according to the manner in which the eyes require to be directed to receive the images of the object looked at, on corresponding parts of the two retinæ.

LOSS OF CORRESPONDENCE IN THE SENSATIONS OF THE TWO EYES.

Diplopy, or double vision with two eyes.

The conditions on which single vision, as well as natural double vision with the two eyes depends, having been premised, we are prepared to enter upon the study of morbid double vision with two eyes.

In limine, it may be observed, that double vision with two eyes is altogether different in its nature from the double or manifold vision with a single eye above considered, the latter being owing to irregular refraction. A case of double vision with two eyes is at once distinguished by closing one eye, when objects will be seen single.

Where from any cause there is a loss of the natural correspondence of the optic axes, the coincidence of the centres of revolution, and the parallelism of the vertical and horizontal diameters of the two eyes, the parts of the two retinæ on which images of the same object are simultaneously projected, are not corresponding parts; therefore, in accordance with what has been above said, the sensations arising from the two impressions are separately perceived by the mind, and the consequence is double vision.

Double vision with two eyes is thus in itself not a disease, but the natural result of derangement of those conditions on which single vision depends. The proximate cause of the derangement alluded to, is most frequently paralysis of some one or more of the muscles of the eyeball; but it may be some morbid production in the orbit, or the like, displacing the eyeball.

The two images in diplopy are often distinguished into true and false, or real and imaginary; but such a distinction is improper, as the image perceived by the displaced eye, although it may be less distinct, is not more false or imaginary than the other, both being equally the result of sensation produced by the impression of rays of light on the retinæ.

That one of the two images is more distinct than the other, is owing to the circumstance, that in one eye the impression is made

on the central part of the retina, which is more sensible than any other; while in the opposite eye, the impression falls on a part of the retina, which according to the degree of deviation of the eye from its right direction, is more or less distant from the centre. The adjustment of that eye, moreover, which receives the impression on the centre of its retina, corresponds with the distance of the object looked at. The other eye not being so adjusted, its image, besides being indistinct, is surrounded by an iridescent halo (p. 318, 2d).

The relative position of the two images depends upon the direction and degree of the deviation of the eyes. Thus the two images are seen, side by side, at a greater or less distance from each other, when the deviation depends on paralysis of the internal or external rectus;—one above the other when the deviation depends on a non-correspondence in the action of the superior or inferior rectus;—one overlapping the other obliquely when the superior oblique is paralyzed.

As sometimes the deviation of the axes or centres and diameters of the eyes exists only when the person looks in particular directions and at certain distances, so does the double vision in such cases take place only when the patient looks in those directions, and at those distances; thus, if the abductor muscle of the right eye be palsied, the patient sees single on looking to the left, but double on looking to the right;—if the abductor, the contrary; if the superior oblique, the patient sees single when he leans his head to the opposite side.

When double vision is owing to deviation of the optic axes, the misdirection of the two eyes may exist in various degrees, from an evident squint to a scarcely perceptible cast.

When, on the contrary, double vision is owing to deviation of the vertical and horizontal diameters of the two eyeballs from parallelism, in consequence of abnormal action of one of the oblique muscles, there is no deviation of the optic axes, and consequently, no squint or cast.

The double vision from deviation of the optic axes is less perceived by the patient when this is great than when it is slighter, because in the latter case, the two retinal sensations are about equal in force, in consequence of the images of the object being projected on parts of the two retinæ, not differing much in sensibility.

As in double vision from deviation of the vertical and horizontal diameters of the two eyes, the images of the object are equally projected on the central parts of the two retinæ, so the two retinal sensations do not differ in force; hence the two sensations contend, as it were, to attract the mind's attention, the consequence of which is great confusion of perception when the two eyes are open, and

sometimes vertigo. As the person in this state can exercise vision only when he closes one eye, the affection has been named *Monoblepsis.*

When the non-correspondence of the two eyes is very slight, the two images seem partially to overlap each other. This appearance not being recognized as a phenomenon of double vision, is sometimes described under the name of *Metamorphopsy.*

The irregular or impeded action of the muscles of the eyeball, giving rise to diplopy, may be owing to an affection of the muscles themselves or of their nerves, or it may be owing to disease or injury of the brain, or to drunkenness, or fear, or to derangement of the *primæ viæ, &c.* But this is not the place to discuss those various primary affections on which the derangement of the action of the muscles of the eyeballs depends. It is enough here to explain the nature of diplopy with two eyes, in order that, as a symptom in any particular disease, it may be appreciated at its due value.

LOSS OF CORRESPONDENCE IN THE DIRECTION AND MOVEMENTS OF THE TWO EYES.

Strabismus, or Squinting, and luscitas, or immovable distortion of the eyeballs.

Strabismus and luscitas are equally characterized by loss of the natural correspondence of the optic axes; but in the former, this is owing to want of harmony in the movements of the eyes, not to loss of motive power, for the squinting eye becomes straight and capable of being directed to any object when the other eye is closed; whilst in the latter, it is owing to one eye being fixed more or less immovably in one direction, in consequence either of paralysis of the muscle moving the eyeball in the opposite direction, or of organic contraction and adhesion of the muscle, &c., of the side to which the eyeball is turned.

The following are the principal forms of strabismus:

1, *Strabismus convergens;* 2, *strabismus divergens;* 3, *strabismus sursumvergens;* 4, *strabismus deorsumvergens.*

Of these different forms, by far the most frequent is *strabismus convergens.*

Strabismus divergens, though rare, is next in frequency.

Strabismus sursumvergens and *strabismus deorsumvergens* are very rare.

It is to be remarked that the affected eye is not always turned exactly inwards, outwards, upwards, or downwards, but may be in-

clined in the intermediate directions; sometimes in a state betwixt strabismus sursumvergens and strabismus convergens, and sometimes betwixt strabismus sursumvergens and strabismus divergens.

Strabismus convergens.

Objective characters.—In convergent strabismus, the pupil of one eye is habitually more or less turned towards the nasal canthus, whilst the other eye looks straight forward, and is capable of being directed to the various objects on which the person fixes his regard. It is only when the habitually well-directed eye is closed, that the inverted eye becomes straight and falls under the command of the patient to be turned in any direction; but as soon as the former eye is again opened, the person loses all command over the other, and it falls back into its original state of inversion.

When the habitually well-directed eye is covered, it squints, while the previously squinting eye becomes properly directed.

The strabismus which passes to the previously well-directed eye when this is covered, is called *alternating strabismus convergens*, the appellation of *double strabismus convergens* being confined to cases in which both eyes are habitually more or less turned in at the same time; one cornea, perhaps being more than half hid in the inner canthus, while the other has a slight inclination inwards.

In some cases of alternating strabismus, the patient has the power, immediately and voluntarily, to direct either eye properly; but while this is done, the other falls into the state of inversion.

In other cases the habitually squinting eye becomes straight, and the opposite eye squints without the will of the patient; and while both eyes are open, there is power to direct properly one eye only.

Alternating is much more frequent than double convergent strabismus. In regard to the relative frequency with which the right or the left eye is turned in, it appears that the left eye is rather more prone to be so than the right.

Subjective symptoms.—The vision of an eye affected with convergent strabismus is usually imperfect. An early symptom is double vision, though of this the patient does not continue long sensible. It is, however, always found, that if the *vision of both eyes is tolerably good*, and the *attention is fairly fixed on their sensations*, single objects held directly before the face are seen double.

The double vision usually attending strabismus is owing to the circumstance that non-corresponding parts of the two retinæ are impressed by the rays of light proceeding from the same object (p. 356).

The image seen by the properly directed eye appears clearer than the other; which is owing not only to that eye being the stronger,

but especially to the circumstance that in it the impression is made on the central part of the retina, which is more sensible than any other; besides, that the adjustment of the properly-directed eye corresponds with the distance of the object looked at (p. 357).

The image of the affected eye is clearer, and in consequence, the diplopy more striking the less the *cast* of the eye; hence the double vision will be noticed by the patient before the misdirection of the eye attracts the attention of those about him. When the squint becomes greater, double vision ceases in many cases, because the impression on the sound eye is much more vivid than that on the distorted one; and we know by experiment, that of impressions dissimilar in force on the two eyes, the mind perceives the stronger, to the exclusion of the weaker.

Causes.—The remote causes to which strabismus is in different cases attributed, or attributable, are very various. They are such as the following:—Convulsions during infancy, difficult dentition, hooping-cough, measles, small-pox, worms, injuries and diseases of the head, fright, anger, injuries, inflammation, and other diseases of the eyes, such as opacities of the cornea, imitation, and a habit of misdirecting the eyes.

Most commonly, strabismus has its origin in early life; indeed, many of the diseases just enumerated as remote causes of the affection, are diseases of early life.

In many cases no cause at all can be assigned.

Is defective vision of one eye a cause of strabismus? In most cases the vision of the squinting eye is imperfect; but, it may be asked, is this cause or effect, or are not the defective vision and strabismus both effects of one and the same cause?

As both eyes have a tendency, the one to turn in, while the other remains straight, imperfect vision of one eye will operate as a cause of rendering the squint habitual in that eye, for the reason that, as one eye only can be directed straight at one time, it is naturally the stronger eye which is so. In this case it is to be remarked, however, that the imperfect vision is not the cause of the squint itself; it is merely the cause of determining it to one eye rather than to the other. The justness of this view is illustrated by the fact, that by binding up the stronger eye, and strengthening the weaker by exercise, the strabismus will shift from the latter to the former.

Supposing defective vision of one eye to have some causal connection with the origin of strabismus itself, it can scarcely ever be the efficient cause, as much more frequently all degrees of defective vision of one eye exist without the occurrence of strabismus; and blind eyes are not more prone to squint than sound ones.

Proximate cause.—Whatever be the remote cause of strabismus,

there can be no doubt that its proximate cause consists in some affection of the muscles of the eyeball. The question which this conclusion naturally suggests is, what is the nature of the affection of the muscles of the eyeball?

The various remote causes of strabismus which have been remarked, such as imitation, affections of the mind—anger, fear, &c.,—disease of the brain, intestinal canal, and other parts, together with the circumstance, that it may occur occasionally only, and the phenomena of strabismus in general, all point to the muscular affection being owing to perverted nervous action.

In strabismus convergens, is it the action of the adductor or abductor which is at fault? If the abductor, it must be in a state of tonic spasmodic contraction, with this peculiarity, that the spasm goes off when the other eye is closed, and immediately returns when it is again opened; and with this peculiarity, that on closing the previously well-directed eye the spasm comes on in it at the same time that it goes off in the habitually squinting one.

Is it the abductor which is at fault? The abductor is certainly not paralyzed, for on closing the habitually straight eye, it evidently exerts its proper function; but, as soon as the latter is again opened, the abductor is no longer able to support the eye in its natural direction, so that the distortion immediately returns. If the abductor be in fault it is obvious that the fault, whatever it is, is transferable from the muscle of the one eye to that of the other.

It has been inferred from the eye not always turning out to the external canthus, on the section of the internal rectus muscle, that the external rectus was paralyzed, but it appears that the action of the inner fibres of the upper and lower recti, which are advantageously inserted for the purpose, are in general sufficient to restrain the everting action of the external rectus (p. 355, 2d).

Organic change of the affected muscle, or contraction of surrounding parts, may, however, supervene; such as contraction and thickening of the conjunctiva on the side towards which the eyeball is turned, and an hypertrophied state of the muscle, as appears from *post-mortem* examination, but especially from observations made during the operation of dividing the muscle at fault. The strabismus thus merges into luscitas.

It is thus seen that there are two distinct sets of cases of convergent misdirection of the eyes, viz., strabismus and luscitas, and that in the former there is in general nothing abnormal perceptible about the organic constitution of the muscles at fault, whilst in the latter there is somewhere organic contraction. But, between cases which may be called pure convergent strabismus and cases of luscitas, there are gradations in which the patient still has more or less power to turn the eye out.

Treatment.—When convergent strabismus is of recent origin, is still purely dynamic, and if its exciting cause can be discovered, and is still in operation, this ought to be the first object of treatment.

In every recent case of strabismus in a young person, where the exciting cause is not evident, it is advisable to prescribe a calomel purge or two, and then an alterative course of mercurial chalk, with an occasional laxative, followed up by tonics.

It is scarcely necessary to say, that whatever prompts to a habit of misdirecting the eyes, whether imitation, trying to look at objects too near the eyes, or otherwise disadvantageously placed, careless employment of the eyes, and the like, must be carefully guarded against.

Exercise of the habitually misdirected eye during two or three hours daily, by covering the other eye, has often been found successful in curing squint. But it is apt to happen that whilst the habitually misdirected eye becomes straight, the previously well-directed one turns in.

When strabismus convergens has become fully established, it resists, as is well known, all treatment such as that above indicated.

Section of the internal rectus as a means of cure.—Ocular myotomy appears to have been practised by the celebrated itinerant oculist the Chevalier Taylor, as a means of curing strabismus, about a hundred years ago; but it never came into use as a regular surgical operation, and so was forgotten.

Of late years, however, it has been revived. Suggested by several different persons independently, and tried on the dead body by Stromeyer especially, the operation on the living body was first introduced into actual practice by Dieffenbach.

It has been seen that in pure strabismus there is in general nothing abnormal perceptible about the organic constitution of the muscle at fault, whilst in luscitas there is either paralysis or organic contraction. Such being the case, the attempt to remedy organic luscitas by operation, every one must admit, was justified by analogy with clubfoot; but certainly the same cannot be said for the operation in pure strabismus. It must be confessed, however, that the operation in cases of pure strabismus has proved more successful than could *a priori* have been expected.

Section of the internal rectus of the habitually misdirected eye alone may be sufficient, but section of the internal rectus of both eyes is generally necessary, as it is found that, if one eye only is operated on, it either still remains inverted, or, if it is rendered straight, the previously well-directed eye is apt to turn in.

The latter circumstance is analogous to that above pointed out, viz., that when the previously well-directed eye is covered, and

the habitually inverted one, by being thus called into exercise, becomes straight, the former turns in.

In double convergent strabismus both internal recti should in like manner be divided at the same time.

Fig. 73.

Position of the patient, assistants, and operator.—This is to be arranged as above indicated for cataract (p. 244, et seq.)

Securing of the eyelids.—For securing the eyelids specula have been much employed, but they may be dispensed with, and the eyelids secured as above recommended for cataract (p. 246, et seq.), only that this must be done wholly by the assistants, as both hands of the operator are necessarily engaged. One assistant may take charge of both eyelids if there is not a second at hand. There, should, however, be an assistant ready with small pieces of sponge to sponge away the blood, which sometimes flows after the division of the conjunctiva, and collects in the wound.

Section of the internal rectus.—The opposite eye being covered, the patient is to be directed to turn the eye to be operated on as much outwards as he can. Whilst he does this, the surgeon, with a toothed forceps held in his left hand, seizes the conjunctiva at about a quarter of an inch from the margin of the cornea on the nasal side, and raises it up in a large transverse fold, which he immediately divides with a pair of straight blunt-pointed scissors, so as to make a free vertical incision through the conjunctiva. This incision may be enlarged with the scissors upwards and downwards, if not at once long enough; but the whole length ought not to exceed one-fourth or one-third of an inch. By this division of the conjunctiva, the tendon of the internal rectus, which is inserted into the sclerotica at about one-sixth of an inch from the margin of the cornea, is exposed.

The next step is to pass a bent probe or blunt hook (Fig. 73) behind the tendon, between it and the sclerotica, from above downwards; bringing its point, when fairly passed behind the tendon, out through the lower end of the incision of the conjunctiva, by raising its handle.

The tendon of the muscle being thus raised on

the hook, the next step is its section, which is effected with the scissors, from below upwards, near its insertion.

If, after this is done, the eye does not admit of being *freely* everted, an exploration of the bottom of the wound is to be made with the hook, in order that if this be owing to any bands of cellular tissue remaining uncut, they may be raised and divided.

The immediate effect of division of the internal rectus of one eye in convergent strabismus, may be, that the axis of the eye becomes directed straight forward, and can be preserved so though the other eye is kept open. If, however, this should not be the case, but the eye still remains inverted, division of the internal rectus of the opposite eye should be forthwith performed.

That the axis of the two eyes, though they may appear to do so, do not correspond immediately after the operation, is shown by the circumstance that double vision has been in most instances an immediate result of the operation, but it has usually gone off sooner or later.

The reason of double vision occurring after, when perhaps it did not exist before, the operation, when the axis of the eyes, deviated so much more, appears to be this:—the rays of light from the object regarded by the sound eye, were either not at all received on the retina of the squinting eye, or if so, received in a place considerably removed from the most sensible part, and the impression on which, therefore was too weak to fix the attention; whereas, after the operation, the rays striking, in the eye operated on, a part of the retina nearer the centre, the sensation is strong enough to attract notice, but, the axes of the two eyes not yet quite corresponding, there is double vision.

It has sometimes been remarked that the vision of the eye became weaker after the operation, but soon improved again. More frequently, considerable improvement in the vision of the eye operated on has been, or has been fancied by the patient to have been, a result of the operation. Generally, however, there is no actual change in the retinal power, and rectification of the squint is all that is gained from the operation.

Unnatural prominence of the eyeball amounting sometimes to semi-dislocation, has been a common result of the division of the internal rectus. This is owing in some degree to the unrestrained action of the oblique muscles, and cannot be altogether avoided, but there is no doubt that it is in a greater measure owing to too free division of the conjunctiva, division of the muscle too far back, and too great detachment of its cellular connections with the eyeball.

Eversion of the eye after section of the internal rectus by the action of the external rectus has much less frequently happened

than might have been anticipated. This is owing in a great measure, as above said (p. 361), to the inverting action of the inner fibres of the superior and inferior recti.

In cases of eversion the eye may eventually turn right. If it does not, division of the external rectus must be had recourse to.

Strabismus divergens.

Strabismus in all respects analogous to convergent strabismus, except that the misdirection of the eye is outwards, is rare.

Divergent luscitas from paralysis of the muscles supplied by the third pair, must not be confounded with divergent strabismus.

The eversion which sometimes occurs after section of the internal rectus for convergent strabismus, inasmuch as the eye can still be moved somewhat from the external angle when the other eye is closed, partakes partly of the characters of strabismus and partly of those of luscitas.

Treatment.—The same general treatment and exercise of the eye, above recommended for convergent strabismus, may be tried in recent cases.

Myotomy has not been so successful in divergent as in convergent strabismus. The return of the eye from its state of eversion to a straight direction after section of the external rectus is but very gradual.

Division of the corresponding recti of both eyes at the same time is equally applicable to divergent as to convergent strabismus.

Section of the external rectus.—This is performed in essentially the same manner as that of the internal rectus, it being remembered that the insertion of the tendon of the external rectus is as much as a quarter of an inch from the margin of the cornea, and is thinner and more spread out than that of the internal.

Strabismus sursumvergens and strabismus deorsumvergens.

The turning up and turning down of eyes, comprehended under these names, appear to be rather examples of luscitas, than pure strabismus.

Cases have been met with, in which the eye having been previously directed inwards and upwards, turned right upwards, after the section of the internal rectus, and was brought back to a natural position only by section of the superior rectus.

In reference to section of the superior rectus, it is to be remembered that the insertion of its inner fibres is nearer the margin of the cornea, but that the average distance of the insertion from the margin of the cornea is about a quarter of an inch.

The insertion of the inferior rectus is similar to that of the

superior, but not quite so far from the margin of the cornea, being only about one-fifth of an inch. Section of the inferior rectus does not seem ever to be required.

Treatment and accidents after the operation of ocular myotomy.—In general, little treatment is required. It is always advisable that the patient should be kept at rest for a day or two after the operation. A cold lotion may be applied to the eye (p. 66), but if pain come on, warm fomentations will be better.

The accidents which have occurred during and after the operation, are :—The eyeball cut into and the vitreous humor evacuated. Hæmorrhage to a dangerous extent. Inflammation of the conjunctiva with chemosis. Inflammation in the orbit, ending in abscess. Panophthalmitis ending in total destruction of the eye. Convulsive movements of the eyeball. Many of these accidents, however, there can be no doubt have been owing to a rude performance of the operation.

When a return of the strabismus takes place, the operation may be repeated. Sometimes success has been obtained only after a second or third repetition.

Paralysis of the muscles supplied by the nerve of the third pair.

The result of paralysis of the muscles supplied by the nerve of the third pair, viz., the levator palpebræ, the internal, superior, and inferior recti, the inferior oblique and the sphincter fibres of the iris, is :

1st. Paralytic ptosis.
2d. Paralytic divergent luscitas..
3d. Paralytic mydriasis.

Paralytic ptosis.—This is a hanging down of the upper eyelid over the eye, in consequence of paralysis of its levator muscle permitting of the unrestrained action of the orbicularis palpebrarum. The patient can thus open his eye only by raising the eyelid with his finger.

Paralytic divergent luscitas.—When the upper eyelid is raised with the finger, the eye is seen to be turned rather outwards and sometimes downwards, in consequence of the paralysis of the internal superior and inferior recti permitting of the unrestrained action of the external rectus, and paralysis of the inferior oblique permitting of the unrestrained action of the superior. The patient is at the same time unable to move the eye upwards or downwards. From the non-correspondences of the two eyes occasioned by the eversion, the patient sees double, especially when he looks to the opposite side, and is apt to become giddy if he attempts to walk while

he holds the eye open. By looking and leaning the head to the side, the double vision ceases.

Paralytic mydriasis.—As above explained, this is persistent dilatation of the pupil, notwithstanding exposure to light, owing to the paralysis of the circular fibres of the iris permitting of the unrestrained action of the radiating ones (p. 306).

It is to be observed, that these three different states may exist separately. The ptosis without immobility of the eyeball; the immobility of the eyeball may not be accompanied by ptosis, and that both these forms of paralysis may exist without affection of the pupil. Besides the double vision, there is often more or less impairment of sight.

Causes.—Paralysis of the parts supplied by the nerve of the third pair sometimes comes on under the same circumstances as rheumatism, viz., exposure to cold and damp. Such cases are properly viewed as being of a rheumatic character.

The cause of the paralysis, however, is often congestion, extravasation, effusion, a tumor, &c., consequent sometimes to blows or falls on the head, involving the intercranial portion of the nerve. In such cases both nerves are apt to be affected.

Rheumatic paralysis of the parts supplied by the nerve of the third pair soon developes itself after the exposure. Paralysis of the same parts, owing to intercranial disease, may according to the nature of that disease come on suddenly or gradually, and be accompanied with paralysis of other parts.

When all parts supplied by the third pair are paralyzed, it is probable that the seat of the affection of the nerve is at or near its origin. When, on the contrary, certain parts only are paralyzed, the disease probably implicates only certain peripheral branches of the nerve.

Prognosis.—Rheumatic paralysis is often cured, though it may yield but slowly. The same may be said of cases apparently owing to some cerebral affection, which have come on suddenly. In slow cerebral cases the prognosis is not only unfavorable, but the paralysis under consideration may be but a comparatively unimportant part of the case.

Treatment.—The plan of treatment in the rheumatic cases is the general antiphlogistic (p. 110, et seq.), consisting of bleeding, mercurialization, and counter-irritation. According to the circumstances of the case, bleeding should be by venesection or leeches, or both; the mercurialization should be pushed to decided affection of the mouth; the counter-irritation may be made by blisters to the crown of the head or over the brow. The same plan of treatment is applicable in sudden cerebral cases. But in slow cerebral cases the alterative plan of treatment with counter-irritation is the only one admissible.

A man, æt. 41. Oct. 14. About ten days or a fortnight ago, severe pain in the left temple came on, from the temple it extended to the forehead of the same side, around the orbit, and down the side of the nose. The pain was much increased when warm in bed. Three days ago the upper eyelid of the same side became affected with paralytic ptosis, and the eyeball lost the power of being fully turned towards the nose. The pupil is not dilated and contracts on exposure to light. The skin of the forehead over the left eye is both warmer and more red than that of the opposite side. Tongue loaded—appetite bad—health generally has not been strong.

To take calomel (gr. iij.) and pulv. ipecac. comp. (gr. viij) at bedtime; and after that calomel gr. j, with opium gr. ½, twice a day. A blister to be applied behind the left ear.

16th.—To continue the pills and take a purgative draught to-morrow morning.

18th.—Feels decidedly better—raises the left upper eyelid more fully, but the eversion of the eyeball still continues, so that he still sees everything double. Quite free from pain. Mouth much affected by the mercury. Appears to move the left eyeball inwards a little more than before.

To continue the pills and repeat the blister behind the ear.

21st.—Raises the upper lid nearly to the natural degree. Turns the eyeball more freely inwards, correspondence of the two eyes is, however, not quite perfect, as he still has double vision. The two images, however, appear less widely separated.

Mouth still much affected. Blister nearly well. Bowels free.

23d.—The upper left eyelid admits of being raised nearly as well as the upper lid of the right eye, and the correspondence of the axes of the two eyes is now nearly complete, so that double vision is almost gone.

Mouth still very sore.

25th.—Continues to improve. To repeat the blister behind the ear.

28th.—He now opens the eye perfectly. The double vision is entirely gone. No pain in the head. Mouth still very sore, and strength sunken.

Nov. 6th.—Mouth a little better, but still is considerably affected. To take bark and soda powders three times a day. (Pulv. cinchonæ,—sodæ sesqui-carbonatis, āā gr. v.)

8th.—Eyes quite well. Mouth still tender. To continue the powders.

22d.—Mouth much better.

Jan. 10th.—Now quite well.

A woman, æt. 47. Ptosis on right side. Paralysis of all the

other muscles supplied by the third pair. Pupil in a middle state and sluggish. Vision rather impaired.

Came on two months ago, accompanied by violent pains in the head, and creeping sensation over the eyebrow.

Recovered under cupping, mercurialization, and counter-irritation. The power over the levator palpebræ began to be recovered soon after the commencement of the treatment, and was complete a considerable time before the patient could freely turn the eye inwards, upwards, or downwards in concert with the opposite eye.

It was three or four months before recovery was perfect.

Paralysis of the muscle supplied by the nerve of the fourth pair.

Paralysis of the superior oblique muscle, as already observed, is not manifested by loss of correspondence with direction of the two eyes, but in consequence of the resulting deviation of parallelism of the vertical and horizontal diameters of the eyeball of the affected side from those of the other eyeball, there is an obliquity in the position of the image seen by the former, so that there results a peculiar form of double vision. This is corrected on leaning the head to the opposite side, the action of the superior oblique here restoring the parallelism (p. 353, et. seq.)

Paralysis of the muscle supplied by the nerve of the sixth pair.

Paralysis of the muscle supplied by the nerve of the sixth pair, or the external rectus, is of rarer occurrence than that of the muscles supplied by the nerve of the third pair.

In this affection the eye is inclined towards the nose, and cannot be turned out (*convergens, luscitas*); and, of course, in consequence of non-correspondence of the two eyes there is double vision, which is in this case more felt as the eye continues open.

Causes.—What has been said of paralysis of the parts supplied by the nerve of the third pair, is applicable to paralysis of the external rectus. In one of the following cases it appears to have been occasioned by a blow on the temple.

Prognosis.—This palsy is more tedious of cure than that of the muscles supplied by the third pair.

Treatment.—This is illustrated by the two following cases:

A woman, æt. 41, received a blow with a fist on the left temple, close to the outer corner of the eye. The skin was broken, and bleeding took place at the time, and by-and-by the eyelids became swollen and lived.

The sight was not at first affected, but about three weeks afterwards everything suddenly appeared to the patient confused.

Shortly after this, when the patient applied for advice, the im-

mediate effects of the blow had disappeared, except some slight conjunctival ecchymosis next the outer angle.

On examination it was observed that the left eye was more prominent than the right, and that it could not be turned towards the left in concert with the right eye. The patient therefore, saw double; she was quite able to turn the left eye towards the right in concert with the right eye; in this case vision was single.

After the blow, suffered from headache, which ceased after the defect of sight supervened.

The treatment, which consisted in cupping once to about ℥viij, mercurialization, repeated blistering, and latterly quinine, was continued for about two months before any manifestation of improvement. She was then able to turn the eye towards the outer corner to some extent.

In another fortnight she was able to turn the left eye almost perfectly towards the outer corner, and was no longer disturbed with double vision.

A man, æt. 36, laboring under diplopia. When a finger is held before him he sees two images side by side. If the finger be held to the left, the images approximate until they coalesce, and one only is seen. If the finger be held to the right, on the contrary, the two images are seen wider apart.

It is the right eye which is at fault; the external rectus being paralyzed so that he cannot turn it towards the temple. Suffered pain over both eyebrows yesterday. Had gonorrhœa about three months ago.

The patient was cupped on the right temple to ℥viij, when first seen, and again a fortnight after. He took calomel and opium to the extent of affecting his mouth, and keeping it so for three or four weeks. Had an occasional laxative and was repeatedly blistered.

Under this treatment he began, in the course of three weeks, to improve, gradually gaining more and more the power to turn the eye towards the temple, whilst double vision became proportionally less, until, at last, in the course of a few weeks more he was able to move the right eye in perfect concert with the left, and double vision wholly ceased.

Oscillation and nystagmus of the eyeballs.

Oscillation of the eyeball is a to-and-fro movement of it round its antero-posterior axis, whilst nystagmus is a similar movement round its vertical axis. The former is owing to clonic convulsions of the oblique muscles, the latter to clonic convulsion of the internal and external recti.

These irregular movements are most generally met with attendant

on defective vision, from whatever cause, which has existed from birth or from an early period of life—such as congenital albinism, congenital cataract, amaurosis—or general nervous complaints, such as hysteria, epilepsy, chorea—or evident disease of the brain.

But little can be done by way of medical treatment. Ocular myotomy, which has been wantonly applied to the treatment of so many different affections of the eye, has been applied to the cases under consideration also, and it is said with success.

CHAPTER VII.

DISEASES OF THE EYELIDS.

SECTION I.—INFLAMMATIONS AND ULCERATIONS OF THE EYELIDS.

Phlegmonous inflammation of the eyelids.

IN this inflammation, which more frequently affects the upper than the lower eyelid, the cardinal symptoms, redness, swelling, heat, and pain, are well marked.

The swelling is circumscribed by the border of the eyelid on the one hand, and the margin of the orbit on the other, and may be so considerable as to prevent the eye from being opened.

If resolution does not soon take place, the inflammation goes on to suppuration. [This affection is sometimes mistaken for serious disease of the eye itself. We have met with repeated instances of this error. Dr. Hays relates a case of the kind in his edition of Lawrence, p. 130, in which the patient had been "subjected to much alarm and very unnecessarily harsh treatment."]

Causes.—Phlegmonous inflammation of the eyelids is frequently of traumatic origin; but in children, in whom it is most common, the cause is sometimes not very evident.

Prognosis and treatment.—If left to itself, the abscess usually points and bursts externally; generally at the margin of the eyelid, near the outer cornea. When the abscess is thus left to burst, the skin and cellular tissue of the eyelids are apt to be materially injured, the eventual consequence of which will be distortion of the eyelids of various kinds, shortening, eversion, &c.

The treatment best calculated to put a stop to the inflammation, and to prevent injury of the skin and cellular tissue of the eyelid, is a free incision with a lancet transversely through the middle of

the swelling. In the purely inflammatory stage, this gives issue to a considerable quantity of blood and fluid exuded into the cellular tissue, relieves tension, and promotes resolution; in the stage of suppuration, it evacuates the matter, and this is usually followed by a subsidence of the symptoms. After the incision, warm fomentations are applied.

The patient is at the same time to be purged and kept at rest.

If the patient dreads the incision, leeches may be substituted in the purely inflammatory stage; and in the stage of suppuration, pointing and bursting of the abscess are to be promoted by warm cataplasms. [It is only in these and other external inflammations of the lids alone that poultices ought ever to be allowed. In all conjunctival and more deeply-seated affections of the eye, cataplasms are generally worse than useless.]

Erysipelatous inflammation of the eyelids.

In erysipelas, the redness varies from a pale rose-tint inclining to yellow, to a bright scarlet or livid hue, is not circumscribed, and disappears on pressure, but soon returns.

The swelling is not great but diffused. Where, however, there is loose subcutaneous cellular tissue as in the eyelids, there is, in addition, considerable œdematous swelling from copious serous exudation into it.

The pain, which is superficial, and generally not severe, is of a burning character.

Constitutional symptoms.—For some days before, the patient complains of general uneasiness, headache, loss of appetite, nausea, and perhaps vomiting, all of which symptoms cease or are much relieved when the erysipelas makes its appearance.

In erysipelas of the face the eyelids are always involved, but sometimes they are the original seat of the inflammation, especially in cases arising from injury.

Besides lacrymation, there is increased Meibomian and conjunctival secretion, which, in the form of a puromucous matter collects over night along the border of the eyelids, and at the inner canthus.

Erysipelas of the eyelids usually ends in resolution, in which case the redness and swelling subside, and branny scales, consisting of exfoliated epidermis and dried exudation, are thrown off from the surface.

In consequence of serous exudation under the epidermis, vesicles or bullæ are sometimes formed. These by-and-by burst, and the matter set free becomes dried into crusts, which, with the branny scales, eventually fall off, leaving the skin in a sound state.

In more violent cases, along with severe pain in the part, and constitutional disorder, the inflammation runs on to diffuse suppuration and mortification of the subcutaneous cellular tissue.

If the erysipelas end in this manner, great distortion of the eyelids may be the result.

General treatment.—The best remedy at first is an emeto-cathartic, consisting of one or two grains of tartar emetic, and an ounce or two of Epsom salts, dissolved in two pints of water, and given in the dose of a teacupful every two hours. Whatever other general treatment may be necessary will depend much on the circumstances of the case. The alterative and tonic plan is that which is found most effectual, especially in London. Elsewhere the antiphlogistic plan is considered the best.

Local treatment.—In many cases, the erysipelas subsides without any local application.

In severer cases, it is advisable to have recourse to scarification by repeated fine punctures with the point of a lancet, encouraging the bleeding by warm fomentations. This affords great relief even in a few minutes, prevents vesication, and diminishes the risk of suppuration and mortification.

When the inflammation has gone so far that suppuration and mortification are threatened, or if they have already taken place, free transverse incisions should be made through the skin into the subjacent cellular tissue, and warm-water dressing applied.

By this practice, mischief is everted, or, if it has already begun, arrested by a free outlet being afforded for pent-up matter, and sloughy cellular tissue.

Variolous inflammation of the eyelids.

The variolous eruption on the eyelids has been noticed under the head of variolous ophthalmia (p. 178), with a reference to this place for the treatment calculated to prevent distortion of the eyelids, such as entropium, ectropium, or trichiasis, from bad cicatrices succeeding the pustules.

The plan which is usually recommended for this purpose is to endeavor to check the development of pustules at the edges of the eyelids by touching them in their early stage with lunar caustic; or if the pustules have already formed, by evacuating them by puncture and then applying the caustic.

Carbuncle and malignant pustule of the eyelids.

Carbuncle sometimes occurs in the eyelids, especially the upper. The danger is the same as when it occurs on other parts of the body, and in consequence of the loss of substance occasioned by

the sloughing, ectropium is the usual result, supposing the event of the case otherwise favorable.

The treatment is the same as when the disease occurs on other parts of the body, viz., opium to relieve suffering, wine and nourishing diet to keep up the powers of the system, and a free crucial incision into the swelling, followed by the application of emollient poultices, until the slough separates, when granulation and cicatrization are to be promoted in the usual manner, care being taken to obviate contraction as much as possible (p. 385.)

[The carbuncle may sometimes be aborted, and perhaps always materially abated, in its forming stage, by the application to its summit of the vegetable caustic, in such a manner as to induce a superficial eschar.]

Malignant pustule, which is a gangrenous inflammation of the skin and cellular tissue, most frequently produced by contagion from oxen, horses, &c., their carcasses or their hides, not much known in this country, but common on the continent, sometimes affects the eyelids.

The injury to which the eyelid is exposed from sloughing is the same as in carbuncle, but the constitutional symptoms may be still more severe, and the result is often fatal.

The first point of treatment insisted on by those who have experience of the disease is to destroy the infected part by the actual or potential cautery.

The general and local treatment is in other respects the same as in carbuncle.

Ophthalmia tarsi.

This is a chronic inflammation of the tarsal borders of the eyelids, of which there are two principal forms, viz., *catarrhal* and *scrofulous*.[1]

The former occurs in adults, and principally affects the delicate integument of the tarsal border and the adjoining conjunctiva and skin of the eyelid;—the latter occurs in children, and affects principally the glandular structures at the borders of the eyelids and the roots of the eyelashes.

Catarrhal ophthalmia tarsi.[2]

Objective symptoms.—Towards the borders of the eyelids the skin is somewhat red and swollen, the conjunctiva red and villous,

[1] These two forms of chronic inflammation of the tarsal borders are generally recognized, but there is great confusion in the names employed to designate them. Some authors employing the names *ophthalmia tarsi* exclusively to the catarrhal form; others, again, exclusively to the scrofulous form, and it is the same in regard to some of their synonymes, such as *lippitudo* and *psorophthalmy*.

[2] Chronic catarrhal ophthalmia. Blepharoblennorrhœa senilis. La mitte, or miasmatic ophthalmia of scavengers and nightmen, &c.

and the delicate integument of the border itself more or less excoriated, especially towards the outer angle.

The eyelashes are loaded with Meibomian secretion, and the eyelids become glued together by it over night.

Subjective symptoms.—These are itchiness and smarting of the borders and angles of the eyelids, and the sensation of foreign particles in the eye, with some intolerance of light, and lacrymation.

When the complaint has been of long continuance, many of the eyelashes fall out, and some become misdirected, and not unfrequently slight inversion or eversion of the borders of the eyelids takes place—the former generally from transverse shortening of the border of the eyelids, the latter from contraction of the skin, and a sarcomatous state of the conjunctiva (*Ectropium senile*).

Causes.—The disease, which may be the sequela of a common general catarrhal ophthalmia, or may, from the first, be confined to the tarsus, affects adults chiefly, whose occupation exposes them to cold and damp, to bad air and mephitic vapors, especially if addicted to intemperance in spirituous drinks; or, independent of such conditions, weakly and old persons.

Treatment.—If there be much redness and smarting at the borders of the eyelids, it will be advisable to commence the local treatment by the application of two or three leeches to the part, or scarification of the palpebral conjunctiva, if this be very red and villous, and bathing with tepid water; after that the bichloride of mercury lotion (p. 69) may be prescribed, to be used three times a day, and the weak red precipitate ointment (p. 72), at bedtime; the surgeon himself pencilling the palpebral conjunctiva every second day with the nitrate of silver solution.

If under this treatment the disease does not appear disposed to subside, it will be useful to apply blisters behind the ears, or paint the solution of iodine (p. 79) over the skin of the eyelids.

Though sometimes an opposite plan is necessary, the general treatment in general requires to be such as is calculated to support the powers of the system, viz., generous diet and tonics; but before having recourse to this, the digestive organs must be carefully regulated by the exhibition of a few alterative doses of mercury followed by mild purgatives. [The lotions should be applied with a brush.]

Sometimes morbid sensibility, from a sunk state of the system, is so great, that the above-mentioned local remedies cannot at first be borne. In this case the belladonna lotion (p. 71) only should be used, and some mild ointment to the edges of the eyelids, with counter-irritation behind the ears, until such time as by the general treatment just indicated, the powers of the system are raised, and the morbid sensibility removed, when the irritating applications may be again had recourse to. [Lead water is a useful addition to the lotion.]

Scrofulous ophthalmia tarsi.[1]

Objective symptoms.—The eyelids are at their borders somewhat red and swollen, and the eyelashes are loaded with incrustations, consisting of the secretion of the Meibomian glands, and of that of the bulbs of the eyelashes, which are poured out in increased quantity, especially over night, so that the eyelids are glued together in the morning.

The palpebral conjunctiva is found, on everting the eyelids, more or less reddened and villous, often granular.

There is occasionally a flow of tears, which fall down over the cheek and cause excoriation of it.

When the incrusted matter is removed from the eyelashes (the manner of doing which is laid down in p. 71), small vesicles or pustules, or ulcers, left by them, are discovered at the roots of the hairs.

Subjective symptoms.—Of these, great itching at the borders and angles of the eyelids is the most marked; indeed, so much so as to have given rise to the opinion, which, however, is quite unfounded, that the disease is psora or itch of the eyelids, hence the name *psorophthalmy*, which has been given to it. Besides the itching, there is heat and occasional smarting.

In an advanced stage of the disease, the eyelids are much thickened and nodulated at their borders, from hypertrophy of the tarsal cartilage, and enlargement of the glandular structures situated there (*tylosis*), the eyelashes are found scanty, many having fallen out and not been reproduced, or succeeded only by dwarfish ones (*pseudo-cilia*), and misdirected, and closely surrounded at their roots by the crusts covering the ulcers, which are now more extensive.

In old and neglected cases, the tarsal border comes to form one with the conjunctival surface in consequence of its posterior edge, which, in the natural state, forms a well-marked line of demarcation between the two, being rounded off, or obliterated, and acquires, like the conjunctiva, a red and sarcomatous appearance.

In such cases, the eyelashes have perhaps all, or mostly all, fallen out (*madarosis*) from destruction of their bulbs, and as no Meibomian secretion can be pressed out, it would seem that the Meibomian apertures are obliterated.

Along with this state of the eye, which is called *blear-eye* or *lippitudo*, there may be some degree of eversion from contraction of the excoriated skin of the eyelids.

The subjects of this form of ophthalmia tarsi, who are generally young persons, often present other evidences of the scrofulous con-

[1] Psorophthalmy, tinea ciliaris, blepharitis scrofulosa, &c.

stitution, such as disordered digestion, tumid belly, enlargements of the glands of the neck, cutaneous eruptions, sore ears.

Causes.—The disease is seldom primary, but is generally a sequela of some ophthalmia, such as exanthematous, catarrhal, scrofulo-catarrhal, or ophthalmia neonatorum, or it arises from the spread of some cutaneous eruption to the borders of the eyelids.

Impure air, damp, bad diet, want of cleanliness, and the like, at the same time that they cause or keep up the bad state of general health, aggravate the local disease, and, indeed, added to neglect or bad treatment, are the principal causes which render it inveterate.

Prognosis.—Except in cases in which the disease has attained the development above described as lippitudo, the prognosis, though on the whole not unfavorable, must be qualified by this, that the cure is likely to be protracted. The supervention of puberty has in general a beneficial effect on the complaint.

Treatment.—Being frequently connected with a faulty state of the constitution, it is of great consequence that attention should be directed to the general health.

The employment of alteratives and purgatives will be found useful preliminaries. The state of the skin must also be looked to, and antimonials employed, if necessary. Afterwards tonics, together with occasional laxatives.

The diet and regimen above recommended in phlyctenular ophthalmia (p. 142), are equally indicated here.

The first point in the local treatment is, that after removing the incrustations from the borders of the eyelids in the manner above directed, to pluck out all those eyelashes at least which are so loose as to yield to the force which can be exerted by means of the finger and thumb grasping them.

This being done, the disease will, in the great proportion of cases, subside under the use of the bichloride of mercury eye-water (p. 69), three times a day; and the application, in the manner above directed (p. 71), of the weak red precipitate salve (p. 72) to the borders of the eyelids at bedtime.

If, however, there is much tenderness and irritability, the only local application, at first, should be tepid water to bathe the eyes, and some mild ointment applied to the edges of the eyelids, whenever the incrustations are removed from the eyelashes, until the irritability be relieved by general treatment, leeches to the eyelids, and counter irritation behind the ears. [Lead water, applied with a brush, is very soothing.]

The application of a leech or two, and scarification of the palpebral conjunctiva, are indicated, whenever there appears to be much congestion at the borders of the eyelids.

In cases in which there is much ulceration at the roots of the

eyelashes, it is a good practice, after removing the crusts and plucking out as many of the eyelashes as can be done without subjecting the patient to much pain, to touch the ulcers with the lunar caustic pencil. This may require to be repeated three or four times at intervals of a few days.

After this the use of the eye-water and salve is to be resumed.

When the disease has become inveterate, any further treatment can only be palliative. It should consist of the occasional use of Janin's ointment (p. 73), and the alum lotion (p. 69); and, when circumstances require it, scarification of the conjunctiva and blisters behind the ears [Liq. plumb. subacet. more or less diluted, and applied with a brush every few minutes, affords great relief.]

If, as is often found in cases of long standing, the palpebral conjunctiva is granular, great benefit is derived from repeatedly scarifying it, and then applying the strong red precipitate ointment or nitrate of silver solution.

Hordeolum or stye.

Stye, as is well known, is a small inflammatory tumor at the edge of the eyelid, attended with more or less heat and pain, and going on to suppuration. It is of a furuncular character. When the abscess bursts, some thick matter, with a small slough, is discharged; the swelling then subsides, and the part heals.

Stye, according to some, is abscess of the Meibomian glands; according to others, it has its seat in the cellular tissue at the margin of the eyelid. Again, it has been suggested that it has its seat in the capsule and glands of the roots of the eyelashes.

Abscess of the Meibomain glands does occur, and gives rise to an external tumor on the edge of the eyelid like a stye, but on everting the eyelid, the affected Meibomian gland is seen distended with matter, which is not the case in stye. There can be no doubt that the roots of the eyelashes are involved in stye, because the hairs at the part affected fall out, and when we pluck them out, matter oozes from the orifice.

As above stated (p. 133), erysipelatous ophthalmia sometimes occurs along with stye.

Causes.—Those most subject to stye are generally of a scrofulous constitution. Derangement of the stomach is a common exciting cause.

Treatment.—At the very commencement, the disease may sometimes be arrested by an emetic, followed by a laxative, and cold applications to the eye, or by touching the inflammatory swelling with caustic. If, however, the disease has already made progress, warm applications to promote suppuration are to be had recourse to. It is in general better to allow the abscess to burst of itself,

but when it is mature, and occasions much uneasiness, relief will be obtained from puncturing it.

Dr. Zeis, who is the author of the opinion that the proper seat of stye is the capsule and glands of the roots of the eyelashes, recommends plucking out the eyelashes at once at the part affected. By this practice the disease is arrested or much mitigated. As the eyelashes fall out at any rate, there can be no objection on the score of saving the eyelashes; besides they are speedily reproduced.

To prevent the recurrence of the disease, attention must of course be directed to that state of general health and those occasional influences on which it appears to depend.

Inflammation and abscess of the Meibomian glands.

Inflammation and abscess of the Meibomian glands simulate, as already said, the appearance of stye externally; but the disease is of rarer occurrence, and its nature is recognized on everting the eyelid, when the affected gland or glands are seen, through the conjunctiva, turgid with yellow matter, which, perhaps, may be made by pressure to ooze out of the corresponding apertures at the border of the eyelid.

By a touch with the point of the lancet, the turgid gland is opened and the matter evacuated.

Syphilitic affections of the eyelids.

Syphilitic ulceration, sometimes primary, more commonly secondary, sometimes affects the eyelids either at their border or on their external or internal surface; in the one case, going on to destroy the whole thickness of the lid, in the other case producing a deep and foul excavation.

As in such cases the ulceration goes on in spite of ordinary local applications, it is of importance to distinguish their nature, in order that by the timely employment of the general treatment for the syphilis, the progress of the ulceration may be arrested.

This being effected, the next point in the treatment is, so to direct the cicatrization, that deformity of the eyelid may be as far as possible prevented.

A man, æt. 28. Admitted Aug. 30. Contracted syphilis four years ago, for which he was treated and dismissed as cured seven months since.

About three weeks ago a small painful swelling formed on the lower eyelid (right side) towards the inner corner.

At present there is ulceration all along the edge of the lower eyelid where the eyelashes are implanted. The upper eyelid is not ulcerated, but both it and the lower are very œdematous and red. The conjunctiva of both eyelids is very red and much thickened,—

that of the lower eyelid especially so. There is some serous effusion under the ocular conjunctiva at the lower part.

To take iodide of potassium (gr. iij) in decoction of sarsaparilla.

Sept. 2d.—Œdema of the lower eyelid gone, that of the upper eyelid less. Ulceration of the lower eyelid much the same.

To continue the iodide. Solution of the nitrate of silver, gr. iv–ʒj, dropped into the eye. The red precipitate ointment (gr. iii–ʒj), to be applied to the ulcerated edge of the eyelid at bedtime.

4th.—The ulceration along the edge of the lower eyelid has began to cicatrize. Œdema of the tarsal edge of upper eyelid continues. Repeated the nitrate of silver drops. To continue the iodide.

9th.—Cicatrization all along the edge of the lower eyelid almost complete. Conjunctiva of lower eyelid still red and spongy-looking. Still some œdema of upper eyelid. To continue the iodide and sarsaparilla.

21st.—Has not been here since last report, and has therefore had no medicine for some days.

The lower eyelid is now quite healed. The upper eyelid is still œdematous, and on examining its conjunctival surface there is seen a large ulcerated spot, covered with yellow puro-lymph. Applied the nitrate of silver solution to this. To continue the mixture.

28th.—The ulcer on the conjunctiva of the upper eyelid much less. Repeated the application of the nitrate of silver solution. To continue the mixture.

Nov. 4th.—The ulcer on the inner surface of the upper eyelid has almost disappeared. To continue the iodide and sarsaparilla.

A woman, æt. 28.—About fourteen months ago had an eruption of red spots all over the body, and two months after that, an ulcer broke out on the left leg, a little below the knee; this continued for four months. About the end of the following December, a small tumor appeared on the upper eyelid, like a stye; shortly after this the ulcer of the leg healed, and ulceration of both eyelids extended itself. At present there is some swelling and ulceration of the upper eyelid towards the outer angle. The whole tarsal edge of the lower eyelid from near the punctum to the outer corner is destroyed by ulceration. The skin of the lower eyelid for about one-twentieth to one-tenth of an inch from what remains of the tarsal edge of the lid is ulcerated. Three grains of the iodide of potassium, with decoction of sarsaparilla, were ordered to be taken three times a day, and the four grain nitrate of silver solution to be dropped into the eye, and applied to the ulcerated surface occasionally. After a month's continuance of this treatment, cicatri-

zation along the edge of the eyelid was completed. The patient no longer experienced any distress from the eye in moving it, as she used to do. The mixture was continued, and the weak red precipitate ointment ordered to be applied to the eyelids. In another month the eye was quite well, and the patient was discharged cured.

In the cases of infants affected with syphilis, above referred to (p. 41), in which the eyelids and other parts of the face and body are covered with an eruption of flat broad pustules, which break, scab, and spread, the *general treatment* should consist of minute doses of calomel, one half grain, or hydrargyrum cum creta one or two grains, three times a day; and the *local treatment* in the application to the edges of the eyelids, of the weak red precipitate ointment.

SECTION II.—ABNORMAL POSITION OF THE EYELIDS, MISDIRECTION OF THE EYELASHES, IRREGULARITY AND LOSS OF MOVEMENTS OF THE EYELIDS, ETC.

ECTROPIUM OR EVERSION OF THE EYELIDS.

In ectropium the eyelid is drawn away from the eyeball, its conjunctival surface turned out, and its ciliary margin displaced. The eyeball, being thus deprived of the protection of the eyelid, is exposed to constant irritation, by which a chronic conjunctivitis is kept up, weakening the eye and giving rise to specks and vascularity of the cornea; in some bad cases, repeated attacks of acute inflammation lead at last to destruction of the eyeball. The conjunctiva of the everted eyelid presents more or less of a villous or sarcomatous appearance; and when it is the lower eyelid which is the seat of the disease, there is usually stillicidium lacrymarum. To these accompaniments of ectropium are to be added a distressing sensation of cold in the eye, and very disagreeable disfigurement.

Ectropium occurs in different degrees, and depends on different causes. It more frequently affects the lower than the upper eyelid. Sometimes both are everted.

Ectropium from excoriation and contraction of the skin of the eyelid, together with a thickened and sarcomatous state of the conjunctiva.

It is almost always the lower eyelid which is the seat of this, the simplest and most common form of ectropium. The disease is

usually the result of some chronic inflammation of the conjunctiva, or ophthalmia tarsi, in which the skin of the eyelid and cheek becomes excoriated and contracted by the attendant discharge on the one hand, and the conjunctiva, thickened and sarcomatous, on the other. The displacement from the contraction of the skin, and the detrusion of the thickened and sarcomatous conjunctiva, is favored by a general relaxed state of the tarsus.

In old persons, the relaxation of the tarsus and the thickened and sarcomatous state of the conjunctiva, seem to operate more frequently in the production of eversion than any contraction of the skin. In consequence of chronic catarrhal ophthalmia, the angles of the eyelids being eroded, the tarsus relaxed, and the conjunctiva at the same time rendered thickened and sarcomatous, the eyelid falls away from the eyeball and becomes everted; and while the contraction of the orbicularis muscle tends to augment the eversion, this becomes more and more confirmed, principally by the increase of the thickened and sarcomatous state of the conjunctiva, and by the gradual accommodation of the eyelid to its changed position.

By long exposure, the epithelium of the everted conjunctiva assumes in a great degree the characters of cuticle; so that the conjunctiva becomes callous, and can now bear, without inconvenience, the contact of external bodies, which before caused irritation and even gave rise to bleeding.

Treatment.—As in the form of ectropium just described, there is no actual loss of the skin of the eyelid, as the contraction of it is in general not very considerable, and as the sarcomatous state of the conjunctiva, together with the relaxation of the tarsus of the affected lid, have a large share in keeping up the eversion, means calculated to produce contraction of the conjunctiva, either alone or in combination with means calculated to shorten the transversely elongated tarsus, will in general be found sufficient to restore the eyelid to its natural position.

To produce contraction of the morbid conjunctiva, the repeated application to its surface of the lunar caustic pencil is the most convenient method. The eyelid being everted still more by traction on the neighboring skin, the caustic is to be pencilled on the conjunctiva in a direction from one angle of the eye to the other, parallel to, but at a little distance from, the ciliary margin of the eyelid. After the application of the caustic, the part is to be wiped with a bit of lint, and then pencilled with sweet oil. It is often advantageous to scarify the conjunctiva before applying the caustic. The cauterization may be repeated in the course of three or four days. Instead of lunar caustic, strong sulphuric acid has been recommended for the cauterization of the conjunctiva. It is ap-

plied by means of a pencil of wood or bone, care being had in dipping the pencil into the acid that it do not take up so much as to form a drop hanging at its point. The lunar caustic, however, deserves the preference in general; and when it is found insufficient to effect the desired object, it is better to have recourse to the *excision of an elliptical shaped piece of the thickened and sarcomatous conjunctiva parallel to the ciliary margin of the eyelid.*

To effect this, the eyelid being drawn as much as possible away from the eyeball by traction on the neighboring skin, the diseased conjunctiva is to be pinched up with a forceps, and the piece snipped off with curved scissors. The piece removed must be of such a breadth as appears sufficient, in order that when cicatrization is complete, the contraction of the conjunctiva may be neither so much as to invert the eyelid, nor so little as still to leave some degree of eversion.

After cauterization or excision of the conjunctiva, it is well to keep the lid in its proper place by means of strips of plaster and a compress and bandage.

When there is evident transverse elongation of the tarsus, *the excision of a wedge-shaped piece out of the whole substance of the eyelid,* as first practised by Sir William Adams, may, either alone, or in combination with one or other of the means above mentioned, be necessary to restore the eyelid to its natural position. The base of the wedge-shaped piece excised corresponds to the ciliary margin of the eyelid, and must be of such a breadth as will restore that margin to its proper length. The excision should be performed rather towards the external canthus than in the middle of the eyelid.

Fig. 74.

The breadth of the piece necessary to be excised being duly calculated, the eyelid is to be seized hold of at the place with a for-

ceps, and drawn from the eyeball. Then with a pair of strong straight scissors, the surgeon cuts out the piece at two strokes, the first being made on the left hand side of the forceps, and the second on the right hand side. After the excision of the piece, the eyelid is to be restored to its proper position, and the edges of the wound united by the harelip suture.

The pins are to be inserted and brought out at some distance, about one-tenth of an inch, from the edges of the wound, and must not implicate the conjunctiva. The first pin introduced should be

Fig. 75.

close to the ciliary margin of the lid, in order to insure evenness at this place. Lastly, the eyelid is to be supported by strips of plaster and a compress and bandage.

The following operation, proposed by Dieffenbach, is applicable only to the cases of ectropium under consideration. It is to be remarked, however, that it is not better calculated to restore the lid to its natural position than the less complicated methods above described.

The everted eyelid being raised up as far as possible into its place, the surgeon makes a semilunar incision through the skin, corresponding in direction to the curve of the edge of the orbit, and at the distance of about one-third of an inch from the ciliary margin of the eyelid. The extremities of the incision should not extend quite so far towards the nose or temple, as to be opposite the angles of the eye. The flap of skin comprehended by this semilunar incision being dissected up along with the part of the orbicularis muscle corresponding to it, the conjunctiva, the adherent surface of which is now exposed, is to be slit through along the orbital margin of the tarsal cartilage and in the direction of the external wound. With a forceps the upper cut edge of the conjunctiva along with the orbital margin of the tarsal cartilage is then to be drawn out through the external wound, with the edges of which it is to be united by means of the twisted suture, after the mucous

surface of its included part has been rendered raw. By this means the ciliary margin of the eyelid is restored to its natural position.

Ectropium from contraction of the skin in consequence of cicatrices, &c.

Ectropium from the contraction of the skin which takes place in consequence of cicatrization, as often affects the one eyelid as the other, and sometimes both, they being equally exposed to the wounds, burns, abscesses, and ulcerations, by which the skin and subcutaneous cellular tissue of the eyelids are liable to be destroyed to a greater or less extent. In cases in which the injury of the skin by burn, wound, or other cause, has been at the outer angle, this, together with the outer part of both eyelids, is everted.

In the form of ectropium, now under consideration, the eversion is generally very complete, sometimes indeed to so great a degree that the ciliary border of the eyelid, very much elongated, is drawn down upon the cheek or up to the eyebrow, as the case may be. Ectropium of the upper eyelid it is obvious leaves the eyeball much more exposed than ectropium of the lower eyelid.

Treatment.—This form of ectropium has exercised the operative ingenuity of surgeons from a very early period, but it is recently only that much success has been obtained. Beer, writing so late as 1817, discusses this form of ectropium in a section entitled, "*Of the incurable diseases consequent to the ophthalmiæ.*"

The operation described by Celsus for lagophthalmus or shortening of the upper eyelid consisted in making a semilunar incision through the contracted integuments of the eyelid "paulum infra supercilium . . . . . cornubus ejus deorsum spectantibus." The eyelid being set free by the incision, was brought into its natural position, and an attempt made to heal the wound thus left by a broad cicatrice. For ectropium of the lower eyelid, he recommends a similar operation, "plagæ tantum," he says, "cornua ad maxillas, non ad oculum convertenda sunt."

This operation, which indeed Celsus recommends only when the loss of skin is inconsiderable,[1] has been performed over and over again, but it has always been found that the cicatrice gradually contracted until the eversion was as bad or worse than before.

Professor Chelius of Heidelberg has somewhat modified the above operation, and says the results he has thereby obtained have been, even in cases of very considerable shortening of the skin of the eyelid, successful beyond expectation.

Chelius's operation.—An incision is made along the whole breadth

[1] He acknowledges that when "nimium palpebræ deest, nulla id restituere curatio potest."

of the eyelid, and as near its tarsal edge as possible, through the skin. The edges of the wound are to be dissected from the cellular tissue, so far that all tension of the skin may be removed, and the eyelid admit of being readily brought into its natural position. The fibres of the orbicularis are then to be divided by several vertical incisions. When the replacement of the eyelid is opposed by a considerable tumefaction of the conjunctiva, a portion of this membrane is to be removed by the scissors and knife, and the external commissure of the eyelids slit up, to the extent of some lines, in a horizontal direction. After this, two loops of thread are to be drawn through the skin by means of curved needles, near the tarsal edge of the eyelid, but without wounding the tarsus. These threads are to be fastened by sticking-plaster to the cheek, if the upper eyelid be the subject of operation, to the forehead in the contrary case, so that the eyelid operated on may be retained in its natural position. The wound of the eyelid, and the wound at the angle of the eye, are covered with charpie, which is to be retained in position by strips of plaster, without any other dressing. In the course of the after-treatment, nothing but charpie, dry or smeared with some mild cerate, is to be applied. The touching of the parts with lunar caustic, even when the granulations rise above the edges of the wound, is to be specially avoided, as contraction of the cicatrice is thereby very much promoted.

To the separation of unnatural adhesions or divisions of the contracted skin, and the extirpation of a portion of the everted and sarcomatous conjunctiva, as described in the preceding method, may be added, when there is much transverse elongation of the tarsus, Adam's excision of a wedge-shaped portion of the whole thickness of the eyelid, as above described. Here it may be remarked, that as, in the cases under consideration, the skin is much shortened, it is necessary in performing the excision to make use of a small scalpel instead of scissors.

Transplantation of a flap of skin from the temple or cheek.—When, after the separation of unnatural adhesions, the extirpation of a cicatrice, or the division of the simply contracted skin, the gap left by the reinstatement of the eyelid in its natural position is very considerable, attempts have been made to transplant a portion of skin from some neighboring part into it. The flap of skin to be transplanted is usually taken from the temple when the upper eyelid is the subject of operation,—from the cheek in the case of the lower eyelid, and is made of a form corresponding with the gap, but of a size nearly twice as great, in order to allow for the contraction which subsequently takes place. The flap, previously measured and traced in outline, is raised by dissection, along with as much of the subjacent cellular tissue as possible, but is still left in

connection with the body by a slip as broad at least as itself. After all bleeding has ceased, and after removing any clotted blood that may be in the gap in the eyelid, or adhering to the flap, the latter is to be so transposed that it may be adjusted to the former, with

Fig. 76.

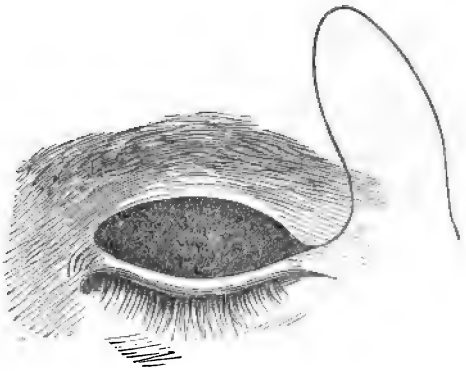

the edges of which it is to be fixed by stitches, strips of plaster, and bandage. The wound in the temple or cheek whence the flap was removed, is to be closed by bringing its edges together with stitches if possible, if not, it is to be allowed to granulate and heal in the ordinary way.

The operation by transplantation of the skin has, in the hands of the late Dr. Fricke, of Hamburg, who first performed it, Dr. Mackenzie, and others, been crowned with success, but in several cases it has failed.

The Author's operation.—The following operation I performed with success in eversion and shortening of the upper eyelid, from contraction of the skin consequent to a burn. The peculiarity of the plan consists in the following particulars: The eyelid is set free by incisions made in such a way, that when the eyelid is brought back into its natural position, the gap which is left may be closed by bringing its edges together by suture, and thus obtaining immediate union. Unlike the Celsian operation, the narrower the cicatrice the more secure the result. The flap of skin embraced by the incisions is not separated from the subjacent parts; but advantage being taken of the looseness of the subcutaneous cellular tissue, the flap is pressed downwards, and thus the eyelid is set free. The success of the operation depends very much on the looseness of the cellular tissue. For some days before the operation, therefore, the skin should be moved up and down in order to render the cellular tissue more yielding.

A description of the operation is comprehended in the following

case:—A woman, aged twenty-four, had her face much scarred. Both eyeballs were exposed on account of shortening and eversion of the upper eyelids. On the left side the eversion of the upper eyelid was not so great as on the right. On this side the ciliary margin of the tarsal cartilage corresponded to the edge of the orbit, and the opposite margin of the cartilage occupied the usual position of the ciliary margin; so that when an attempt was made to close the right eye, it was the orbital margin of the tarsal cartilage which was pressed down. There was some degree of shortening and eversion of the left lower eyelid. The patient saw very well with the right eye; but with the left, on account of opacity of the cornea, she did not see well enough to recognize a person. At the age of one year and three months she fell into the fire, and had her face severely burned, which was the cause of the state above described.

Two years before coming under my care, she had an operation performed on the left eye, and derived advantage from it. It is probable, however, that the eversion only had been lessened by the operation, for the shortening of the upper eyelid was still very great.

On the 22d of February, 1836, I operated on the *left* upper eyelid. Two converging incisions were made through the skin, from over the angles of the eye upwards to a point where they met, somewhat more than an inch from the adherent ciliary margin of the eyelid. By pressing down the triangular flap thus made, and cutting all opposing bridles of cellular tissue, but without separating the flap from the subjacent parts, I was able to bring down the eyelid nearly into its natural situation, by the mere stretching of the subjacent cellular tissue. A piece of the everted conjunctiva was snipped off. The edges of the gap left by the drawing down of the flap, were now brought together by suture, and the eyelid was retained in its proper place by plasters, compress, and bandage.

During the healing of the wound, a small piece of the apex of the flap, which had been somewhat separated from the subjacent parts, sloughed. By the 1st of April healing had taken place, and the eversion completely cured. The cicatrice where the part had sloughed was pretty broad. When the bandages were first left off, the eyelid was so elongated, that if the lower eyelid had not also been shortened, the eye would have been entirely covered. After leaving off the bandages some shortening took place, from contraction, not of the cicatrice, but of the skin. Being no longer on the stretch, the skin assumed, as it contracted, more of its natural appearance.

About the middle of March, the *right* upper eyelid was operated upon. The incisions were made in a similar way (Fig. 77, next page), except that they did not meet in a point, a space being left

between their extremities to the extent of about one-sixth of an inch, which was divided by a transverse cut.

Fig. 77.

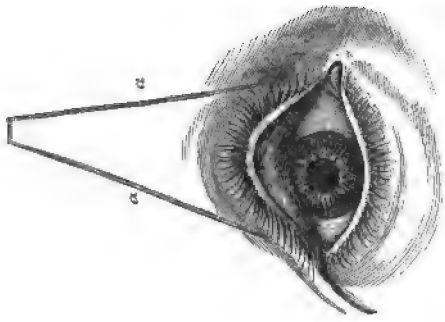

Fig. 78.

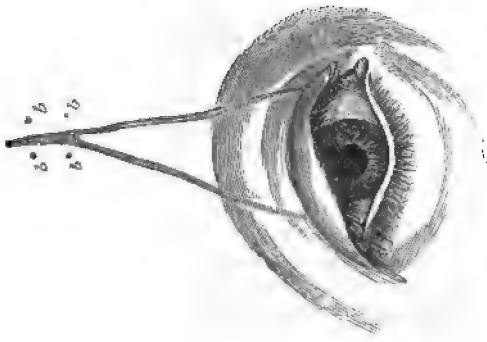

Fig. 78 shows the right eye after the parts had healed, the cicatrice where the gap was, and the marks of the sutures.

By the stretching of the subjacent cellular tissue, I succeeded in drawing down the flap, and thus elongated the eyelid so much that it covered the eye entirely; but in consequence of the long-continued displacement of the tarsal cartilage, the ciliary margin of it did not come into contact with the eyeball. I did not interfere

with this state of parts by attempting any transverse shortening of the lid, but a piece of the everted conjunctiva was removed, and with it a bit of the tarsal cartilage. From the surface of this wound there sprang out a small soft fungus, which was cut off with the scissors, and the root touched with the lunar caustic pencil.

The above operation was repeated by M. A. Bérard, in 1837, without success, and by M. Velpeau, in 1838, successfully in one case, and unsuccessfully in another, in which erysipelas came on.

Dieffenbach's operation.—Fig. 79.—This is commenced by extirpating the cicatrice and degenerated skin, the incisions being made so that a triangular wound may be left, having the base to-

Fig. 79.

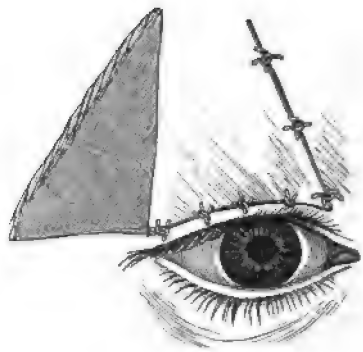

wards the margin of the eyelid. The tarsus, if present, is to be carefully preserved; but if the whole eyelid is gone, whatever of the conjunctiva remains is to be detached from the margin of the orbit, and dissected up a little towards the eyeball, in order that it may afterwards be adapted as a lining to the new eyelid. From the outer extremity of the base of the triangular wound an incision through the skin is to be carried towards the temple or cheek, according as the upper or lower eyelid is to be repaired; the length of which incision must be somewhat greater than that of the base of the triangular wound of the eyelid. Beginning at the temporal extremity of this horizontal incision, another is to be made—downwards, if it is the lower eyelid which is to be restored—upward, if the upper eyelid. This second incision is to run not quite parallel with the outer edge of the triangular wound, but slightly approximating to its apex, on a level with which it is to terminate.

The flap of the skin thus circumscribed is to be raised up by dissection, along with its subjacent layer of fat and cellular tissue.

After the bleeding has ceased, the flap and the triangular wound are to be carefully freed from coagula, and the former so transposed that it may fill up the latter. The flap is now to be secured in its new situation, first by a stitch at the inner angle of the eye. Its palpebral edge is then to be united by four stitches to the tarsus, if present; or, if this has been lost, with the conjunctiva, at its cut margin. Lastly, the inner edge of the flap is united to the skin, forming the inner boundary of the triangular wound by means of the twisted suture. The wound in the temple or cheek, left by the removal of the flap of skin, is to be dressed with charpie; and, over the whole, several strips of adhesive plaster are laid, in order to keep the transposed flap accurately adjusted in its new situation. Cold water dressings are then to be applied.

This method of operating has been successfully followed by Lisfranc, Ammon, Eckström, Blasius, and Fricke.

Instead of taking the flap wholly from one side, a part may be taken from one side, and a part from the other. The two parts are then to be united in the middle by the hare-lip suture. This is said to be the manner in which Dieffenbach ordinarily performs the operation for ectropium of the lower eyelid.

The above plans of operating may be modified and combined in different ways, according to the circumstances of any particular case.

It has been mentioned, that it sometimes happens that, from bad cicatrices, the skin of the temple is much contracted, and the external commissure, together with the outer parts of the lids, everted in consequence. In such a case Walther excised the tarsal edges of both eyelids where they were everted, together with the commissure and a triangular piece of the neighboring integument of the

Fig. 80.

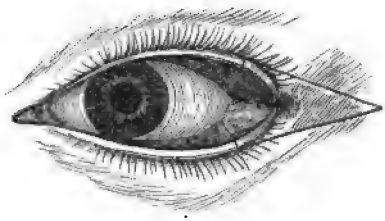

temple, the base being towards the eye, and the apex towards the ear (Fig. 80). He then united the edges of the wound by two sutures; and the eversion was by this *tarsoraphia* cured. (Fig. 81.)

In similar cases, but more complete eversion of both eyelids, Dieffenbach has made to the above proceeding of Walther the following additions. After the excision of the triangular piece from

Fig. 81.

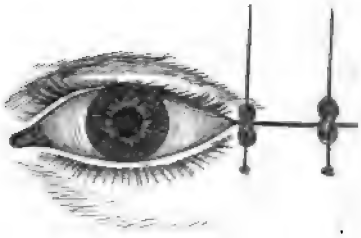

the outer canthus, a curved incision is carried above the supra-orbital arch; and another, below the lower margin of the orbit, and towards the nose. The two crescentic flaps are then raised; and, after closing the wound in the temple, they are adapted as new lids to the remaining conjunctiva.

Ectropium from caries of the orbit.

When ectropium is complicated with caries of the margin of the orbit, nothing in the way of operation in reference to the ectropium should be attempted, until the disease of the bone is cured. Then,

Fig. 82.

it will generally be necessary, on account of the extent to which the skin of the eyelid has suffered from the carious suppuration and ulceration, to have recourse to the transplantation or transposi-

tion of the neighboring skin, according to some one of the operations above described. It, however, sometimes happens, that, though the eversion is considerable, a very small part of the skin only is drawn into the cicatrice, whilst the surrounding skin, still pretty healthy, is puckered. In a case of this kind, Dr. Ammon surrounded the adherent part of the skin by an incision; left it adherent to the bone; detached the neighboring integuments all round, to such an extent, that the lid was set at liberty, and the patient could shut the eye. He then closed the external wound over the

Fig. 83.

old cicatrice. The lid was in this way elongated, a scarcely observable scar remained, and the disagreeable depression at the edge of the orbit was no longer in view.

ENTROPIUM OR INVERSION OF THE EYELIDS.

Entropium is the converse of ectropium. The free margin of the eyelid with the eyelashes is turned in against the eyeball, which they keep in a state of great irritation by the friction they exert upon it.

The margin of the eyelid may be inverted in part of its extent only, constituting *partial* entropium; more commonly the entropium is *total*. One eyelid only may be affected, or both eyelids together of one eye. Sometimes one eyelid of one eye, and one eyelid of the other; sometimes again both eyelids of both eyes are turned in.

The distress occasioned by the friction of the margin of the eyelid and the eyelashes against the eyeball when an attempt is made to use the eye, together with the intolerance of light which is usually present in a greater or less degree, forces the patient to keep the eye always closed, or half closed, and as much as possible at rest.

In consequence of the constant irritation which attends en-

tropium, chronic conjunctivitis with vascularity of the cornea is kept up.

Entropium is to be distinguished from *trichiasis*, which is attended by the same distressing irritation. In trichiasis, the margin of the eyelid retains its proper position, whilst the eyelashes only are inverted. Entropium and trichiasis, however, not unfrequently coexist.

There are different forms of entropium depending on different morbid conditions of parts, and therefore requiring different modes of treatment.

Entropium may be owing to—1. Relaxation of the integuments of the eyelid, and spasmodic contraction of the orbicularis palpebrarum muscle when long continued. 2. A contracted and deformed state of the tarsal cartilage.

Entropium from relaxation of the integuments of the eyelid, and spasmodic contraction of the orbicularis palpebrarum muscle.

In consequence of the firmness and breadth of its tarsal cartilage and the existence of the levator palpebræ muscle, simple relaxation of the integuments of the upper eyelid seldom produces entropium; it merely hinders the eyelid from being freely raised, constituting one form of ptosis. It is the lower eyelid which is most generally the seat of entropium from relaxation.

In this form of entropium, the margin of the eyelid and the eyelashes are in other respects perfectly natural, and the tarsal cartilage appears to be healthy. The eyelid is simply rolled back upon itself, sometimes, so much round that the margin with the cilia lies in the inferior palpebral sinus of the conjunctiva. If the finger be applied to the outside of the eyelid and the skin pressed down a little, the margin of the lid with its eyelashes readily starts into its place, and will continue so of itself until the patient winks, when it will fall back with a jerk into its former state of inversion.

A relaxed and superabundant state of the integuments of the eyelid, does not appear to be of itself the essential cause of the entropium; it appears merely to favor its development at first, and to allow of its continuance afterwards. The displacement inwards of the margin of the eyelid, will usually be found to have taken its rise in the following manner. During an attack of ophthalmia attended by a swollen or œdematous state of the eyelids, these being long kept closed or even spasmodically contracted, the edge, overbalanced by the puffy state of the orbital portion of the lid, is pressed or turned inwards by the ciliary portion of the orbicularis muscle.

A wrong direction having been thus acquired, it continues even after the subsidence of all swelling or œdema. The form of entropium just described, is most frequently met with in old persons, hence named *Entropium senile.*

Fig. 84.

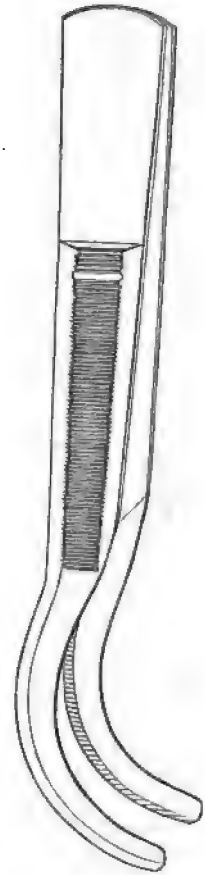

When no relaxed and superabundant state of the integuments of the eyelid exists, entropium may be produced by the spasmodic contraction of the orbicularis muscle, during an acute attack of inflammation with intolerance of light, and a swollen state of the eyelids; but it will cease on the subsidence of the ophthalmia, especially if care be taken to keep the eyelid in its proper place, by some mechanical contrivance. A layer of collodion, renewed every second or third day, will sometimes answer, but the most efficient and convenient contrivance for this purpose is a bit of firm wire so twisted and bent, as to fit on the back of the head by its middle, and press by its rounded extremities against the orbital portion of the lower eyelid.

Treatment.—This consists in the excision, or the destruction by caustic of a portion of the relaxed integuments.

Excision.—The portion of integument removed should be of an elliptical shape, and of such a breadth, that when the edges of the gap which is left are brought together, the eyelid will be retained in its proper position. Though the piece of integument ought to be removed as near as possible to the margin of the eyelid, a sufficient breadth of skin must still be left at the margin for the insertion of stitches.

To effect the removal of the piece of integument in the form of an ellipse, a transverse fold, of a size sufficient to bring the eyelid into its proper place, is to be taken hold of with the entropium forceps (Fig. 84,), and snipped off with a pair of scissors. After the excision of the fold, the edges of the wound are to be brought together by two stitches. It is frequently advisable to add to the transverse excision of the fold of skin a perpendicular incision through the whole thickness of the border of the lid near the outer canthus, as described below in

cases of entropium of the lower eyelid from transversely contracted tarsus.

[It is better, especially in bad cases, to remove a portion of the fibres of the orbicularis muscle as well as the integumentary fold. This portion should be as near as practicable to the ciliary margin. Mr. H. Walton, who attributes this form of entropium mainly to inordinate contraction of the ciliary muscle, recommends an operation with the scalpel, by which these fibres are more effectually dissected off along with the superjacent skin. We have found this to succeed admirably, although more difficult, tedious, and painful than the forceps method. See Haynes Walton, Am. Ed. p. 136.]

This excision of a transverse fold of integument may in some cases be advantageously followed up by the excision of a vertical fold, as has been done by Dzondi. A mode of operation practised by Janson of Lyons consists in the excision of vertical folds of skin alone, extending to near the free edge of the eyelid.

Cauterization.—The escharotic most commonly used for this purpose is concentrated sulphuric acid. [Nitric acid answers equally well.] By means of a pencil of wood, the acid is to be rubbed over an oval portion of the integuments of a length corresponding to the inversion, and about one quarter of an inch broad in the middle. After a few minutes the eyelid is to be dried with a bit of lint and the application of the acid repeated, and this again and again, until a sufficient contraction of the skin is produced, so as to bring the eyelid into its proper position. It may be necessary after a time to repeat the application of the acid. Caustic potash I have found more manageable than the sulphuric acid.

Cauterization is not admissible in cases where the skin is very superabundant. It is best adapted for slight and recent cases, or cases in which after excision there is still some tendency to turn in.

Entropium from a contracted and deformed state of the tarsal cartilage.

The upper eyelid is as liable to this form of entropium as the lower; very often both are affected together.

In long-continued ophthalmia tarsi, or catarrhal or scrofulous conjunctivitis, the tarsal cartilage suffers. It becomes indurated and contracted on its inner surface, whilst it is shortened transversely, or from canthus to canthus; the effect of which is, that the margin of the eyelid is turned in right against the eyeball, and cannot by any traction on the integuments be brought back into its proper position, as in entropium from relaxation. The edge of the eyelid may indeed be drawn from contact with the eyeball, but it still remains curved inwards.

In this form of entropium, the margin of the eyelid is often thickened and irregular from hypertrophy of the tarsal cartilage, while the eyelashes are also inverted, constituting trichiasis in addition to entropium.

Allied to the above form of entropium, is that which is sometimes produced by injury of the conjunctiva and cartilage, from the intrusion of lime and other caustic substances into the eye. The contraction attendant on the cicatrization gives rise to inversion of the eyelid, which is often conjoined with symblepharon.

Treatment.—Ware's operation.—As in this form of entropium, the inversion is owing in a great degree to the transverse shortening of the tarsus, Mr. Ware, in order to remedy this, recommended a perpendicular incision to be made through the whole substance of the lid at its temporal extremity or in its middle. In addition to the perpendicular incision, it is sometimes necessary to excise a fold of the integument with the scissors. The perpendicular section of the lid is immediately followed by a separation of the edges of the wound; and it presents an outline similar to that of the letter V; wide at the ciliary margin, and terminating in an acute point in the opposite direction. This wound is gradually filled up by granulation.

Crampton's operation modified.—Supposing the upper eyelid to be the subject of this operation, two perpendicular incisions through its whole substance are made, one near the external canthus, the other near the inner canthus.[1]

The lid being thus set free, a transverse fold of its skin is then to be removed from near its ciliary margin, and the edges of the gap thus produced brought together by two or three stitches. The threads forming the stitches are to be left long. The eyelid is now to be everted and turned up, and kept in this position for a few days by means of the threads fixed to the forehead by strips of plaster. The perpendicular incisions are thus prevented from uniting by the first intention. They are permitted to heal only by granulations. After the removal of the ligatures, the eyelid is, by the cicatrization of the perpendicular wound which ensues, gradually drawn into its natural position without being again inverted. During the time the eyelid is kept everted and turned up, it is to be covered with a piece of linen spread with simple cerate.

In cases of entropium of the lower eyelid from transversely contracted tarsus, I have performed the operation in the following manner with perfect success. An incision through the whole thickness of the lid being made perpendicular to its edge near the outer

[1] The first incision will necessarily wound the lower mass of the lacrymal gland, together with some of the lacrymal ducts; but in the cases in which I have performed the operation, I have not observed any lacrymal fistula or other bad consequence follow. The incision near the inner canthus ought always to be on the temporal side of the punctum, in order to avoid cutting the canaliculc.

canthus, a piece of the skin of the lid is excised, and then the lid kept in the everted position by fixing on the cheek the end of the thread forming the suture, which unites the edges of the wound left by the excision of the piece of skin.

When, as often happens, in inveterate cases of the form of entropium under consideration, the operations just described prove ineffectual, recourse must be had to extirpation of the bulbs of the eyelashes as in trichiasis, or amputation of the whole tarsal margin.

Trichiasis and distichiasis.

Trichiasis is a growing in of eyelashes against the eyeball, the border of the eyelid remaining in its proper position, which circumstance constitutes the distinction between trichiasis and entropium (p. 394).

Distichiasis, again, is merely a variety of trichiasis, in which the misdirected eyelashes are disposed, though not very regularly, in a row distinct from the others, which remain properly directed.

The faulty eyelashes in trichiasis and distichiasis are generally the natural hairs which have been made to take a wrong direction, in consequence of cicatrices, &c., of the border of the eyelid. Sometimes, however, they appear to be in part at least of new development.

Fig. 85.

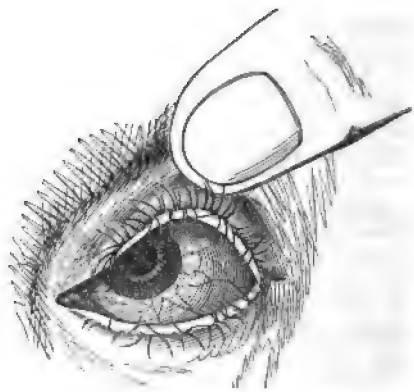

Trichiasis may be *partial* or *total*. In the one case, the misdirected eyelashes are confined to a part only of the border of the eyelid; in the other, they spring from it along its whole extent.

The eyelashes of either eyelid separately may be turned in against the eyeball, or the eyelashes of both eyelids may be turned in at

the same time. It is not uncommon to find trichiasis or distichiasis affecting the eyelids of both eyes.

The misdirected eyelashes are sometimes very few in number, and so pale and fine, that they are apt to escape notice, and the inflammation of the eye which they occasion, attributed to some other cause, unless an exploration of the borders of the eyelids and state of the eyelashes be carefully made as above indicated (p. 42).

The effects on the eye, both *objective* and *subjective*, from the irritation of the misdirected eyelashes in trichiasis, are the same as those above mentioned in entropium (pp. 393, 394.)

Causes.—Trichiasis and distichiasis are sequelæ of chronic conjunctivitis, and especially those inflammations of the borders of the eyelids which are attended by abscesses and ulcers at the roots of the eyelashes, such as variolous inflammation of the eyelids and ophthalmia tarsi in both its forms.

The coexistence of entropium and trichiasis, and the causes on which it depends, have been noticed (p. 394).

Treatment.—Trichiasis or distichiasis admits of being relieved only by operation.

Evulsion of the misdirected eyelashes.—The mode of performing this operation, and the instrument used, are described in p. 79. It requires to be repeated from time to time as the eyelashes are reproduced. Unless, therefore, the misdirected eyelashes be few in number, this mode of treatment becomes very troublesome.

Excision or cauterization of the skin of the eyelid as in entropium.—Either of these operations may be had recourse to with some advantage in those cases of trichiasis, sometimes met with, in which the eyelashes, for a considerable extent along the edge of either lid, instead of being curved upwards in the upper eyelid, and downwards in the lower, are directed perpendicularly, so as readily to cling to the surface of the eyeball.

Extirpation of the roots of the eyelashes.—In inveterate cases of trichiasis, as well as of entropium, or of trichiasis and entropium combined, there is no other resource but destruction of the eyelashes by extirpation of their roots.

In reference to this operation, it is important to call to mind the following anatomical points:—The eyelashes spring from the anterior edge of the free borders of the eyelids, and are inserted three or four deep, especially in the middle. The capsules of the bulbs of the eyelashes lie close on the tarsal cartilage under the ciliaris muscle and skin, extending to the depth of about one-eighth of an inch.

The lid to be operated on is to be raised and stretched on the horn spatula-like instrument, represented in Fig. 85, introduced behind it, and held steadily by an assistant, who at the same time

retains the eyelid from slipping away by pressing the eyelashes against the horn spatula with the thumb-nail of the hand holding it.

The surgeon, then, with a small scalpel, makes an incision, parallel to the border of the eyelid, and about one-eighth or one-sixth of an inch from the edge whence the eyelashes issue, through the skin, cellular tissue, and ciliaris muscle, down to the tarsal cartilage. According as it is along the whole border of the eyelid, or along a part only, that the trichiasis extends, and consequently that the extirpation of the roots of the eyelashes requires to be carried, so of course must be the length of the incision. From each end of the incision now made, a short one is to be carried at right angles to the edge of the eyelid.

Fig. 86.



The long narrow flap of skin thus marked out is now, together with the subjacent cellular tissue, ciliaris muscle, and the bulbs of the eyelashes, to be laid hold of with a toothed or good holding common forceps, and dissected clean from off the tarsal cartilage towards the margin of the eyelid. The surface of the tarsal cartilage may even be shaved off.

It is scarcely necessary to say that in this dissection injury of the lacrymal point and canalicule must be carefully avoided.

The detached flap, comprising skin, cellular tissue, muscular fibres, and bulbs of eyelashes, is now to be cut away with the scissors along the margin of the eyelid, leaving a strip, however, about one-thirtieth of an inch broad, for the insertion of sutures, if thought necessary.

During the operation, the blood, which oozes out in very considerable quantity, requires to be assiduously taken up with a sponge by an assistant, in order that the operator may see that no bulbs are left unremoved.

If any bulbs still remain they will present themselves as black points, and thus be readily discovered. They are to be laid hold of with the forceps and removed with the scissors. After this, to insure still more the removal of all the bulbs, the bottom of the wound should be pencilled with the nitrate of silver or other caustic, and left to suppurate.

The eyelashes, which are now loose, may be plucked away with the finger and thumb.

If the bulbs have not been all removed or destroyed, it will be found that the part has scarcely healed, when a hair or two will be found here and there sprouting out again.

If the case be one of entropium and trichiasis combined, it is advisable to commence the operation by making two perpendicular incisions through the whole thickness of the border of the eyelid, as in Crampton's operation for entropium (p. 397). Indeed this might always be done, as thereby the supply of blood to the part operated on is in a great measure cut off, and the hindrance to the successful dissecting out of the bulbs of the eyelashes from the oozing of blood much diminished.

When the tarsal cartilage is much thickened and indurated, it should be shaved down with a fine sharp scalpel to the natural degree of thickness.

Lagophthalmos.[1]

This name is given to a constant open state of the eyelids, the consequence of which is, that the eye is, as in ectropium, exposed to the entrance of foreign particles and other causes of irritation.

There are three principal forms of lagophthalmos, depending on very different causes, viz.:

1st. Paralysis of the orbicularis muscle, allowing of the unrestrained action of the levator palpebræ.

2d. Organic contraction or adhesions of the eyelids.

3d. Congenital imperfect development of the eyelids.

Lagophthalmos from paralysis of the orbicularis palpebrarum.

This is one merely of several symptoms of paralysis of the portio dura of the seventh pair. The paralysis of the orbicularis may be so complete that the upper eyelid is immovably retracted; but in general, it is not so complete, the eyelids still admitting of being approximated, though not accurately closed.

Besides the retraction of the upper eyelid, the border of the lower is somewhat fallen away from the eyeball, the lacrymal papillæ and puncta being thus no longer duly directed to the lacus lacrymalis, the tears are not absorbed and drawn off into the nose, but fall down over the cheek.

Causes of paralysis of the portio dura.—Paralysis of the portio dura may be owing to cerebral disease, or to some affection of the nerve itself, either in its passage through the aqueduct of Fallopius, or at its exit from the stylo-mastoid foramen.

Affection of the nerve in its passage through the aqueduct of

[1] Oculus leporinus or hare's eye, so called from its having been supposed that hares sleep with their eyes open.

Fallopius usually depends on caries of the osseous walls of the tympanum.[1]

The affection of the nerve at its exit from the stylomastoid foramen may consist in pressure on the nerve by an enlarged lymphatic gland or other tumor.

Sometimes the affection of the nerve would appear to be of a rheumatic nature, like what is sometimes the case with paralysis of the nerve of the third pair (p. 367).

Treatment.—This resolves itself into the treatment of the cerebral disease, diseases of the ear, or enlarged lymphatic gland or tumor. In cases in which the paralysis of the nerve seems to have arisen from cold, and is altogether uncomplicated with disease of the ear or swelling at the angle of the jaw, the plan of treatment above indicated for rheumatic paralysis of the nerve of the third pair is equally applicable (p. 367).

A woman, æt. 33, has for the last ten months been subject to throbbing pain across the forehead, and especially in the temples. Health otherwise good during that time.

A month last Saturday night, stood for an hour and a half in the street in the cold. When she rose next morning, felt a twitching and quivering of the upper lip on the right side, which continued at intervals for three days.

Some days after that the right eye became weak and watery.

Last Saturday morning, she found that on attempting to blow away dust or the like, she was unable to do so. She at the same time felt her mouth drawn to the left side.

On examination the right cheek was observed to be collapsed, the mouth drawn to the left side, especially in speaking. She can shut the right eyelids, but not closely, and feels herself unable to compress the eyeball with the eyelids. The edges of the right eyelids somewhat red, and the palpebral conjunctiva injected. The right eye watery from the puncta lacrymalia not being duly diverted towards the lacus lacrymalis.

Lagophthalmos from organic contraction or adhesions of the eyelids.

The organic shortening or retraction of the eyelids producing lagophthalmos, usually depends, like that producing ectropium, on the contraction attendant on cicatrization of a burn or other injury; or on the skin of the eyelid being drawn into adhesion with the edge of the orbit in consequence of carious ulceration.

Treatment.—This form of lagophthalmos can only be remedied by one or other of the operations above described for ectropium, the

[1] See article—Ear and Hearing, Diseases of, in the Cyclopædia of Practical Surgery.

choice of the operation being determined by the circumstances of the case.

Of course, when the retraction of the eyelid depends on caries of the edge of the orbit, no operation should be had recourse to till this is cured.

Congenital lagophthalmos.

Congenital lagophthalmos is usually a part merely of general *microphthalmos.*

Ptosis or falling down of the upper eyelid.[1]

Ptosis is the opposite of lagophthalmos, the upper eyelid hanging down over the eye, and not admitting of being raised for the exercise of vision.

There are four principal forms of ptosis.

1st. Ptosis from paralysis of the nerve of the third pair.

2d. Ptosis from injury of the levator palpebræ muscle.

3d. Ptosis from extension and relaxation of the skin or of the whole substance of the eyelid.

4th. Congenital ptosis.

Ptosis from paralysis of the nerve of the third pair.

The nature of this form of ptosis has been already noticed (p. 366.)

Treatment.—If the paralysis of the nerve of the third pair be confined to one side, and resist the treatment above indicated, nothing more can be done; if, however, the nerve on both sides be affected, and double ptosis therefore exists, the application of a strip of plaster, or some such contrivance, must be had recourse to, to retain the upper eyelid on one side open, in order that the person may see to move about. A degree of ptosis comes on naturally from sleepiness. A woman affected with incomplete paralytic ptosis was always unable to open her eyes after a bad night's rest. Being subject to sleeplessness, she was much benefited by soporifics.

Ptosis from injury of the levator palpebræ muscle.

In wounds of the upper eyelid, the levator muscle may be divided, or otherwise so injured, as to be rendered unfit to exercise its function; the result of which is ptosis.

After healing of the wound, the function of the muscle may become re-established by reunion, in which case the ptosis disappears.

[1] Blepharoptosis.

This may, however, not take place, especially if the muscle be much torn.

For the rectification of ptosis thus occasioned, an operation has been performed by Mr. Hunt, of Manchester, which consisted in the removal of a transverse fold of integument from the eyelid, of such an extent and from such a place, that when the edges of the wound became united, the eyelid was attached to that portion of the skin of the eyebrow upon which the occipito-frontalis acts; so that the action of this muscle was substituted for that of the levator palpebræ.

Ptosis from extension and relaxation of the skin, or of the whole substance of the eyelid.

Extension and relaxation of the skin of the eyelid occasioning ptosis may be the result of long-continued œdematous swelling of the parts, and the like, but it sometimes occurs in old persons without any evident cause.

This form of ptosis may in general be remedied by the excision of an elliptical piece of skin as above directed for entropium (p. 395, et seq.)

Ptosis from extension and relaxation of the whole substance of the eyelids, I have seen as a sequela of purulent ophthalmia, in which bluestone and other caustics had been much abused in the attempt to remove the granulated state of the conjunctiva.

In such a case the excision of a wedge-shaped piece of the eyelid has been recommended, in order to diminish its length transversely. To this, if necessary, might be added the excision of an elliptical piece of skin, as above directed, in order to shorten the lid vertically. But such an operation should of course not be had recourse to unless the eye has otherwise pretty well recovered.

Congenital ptosis.

Ptosis sometimes occurs congenitally, owing usually to an imperfectly developed state of the levator palpebræ muscle, and therefore incurable, but in some cases merely to relaxation of the skin of the eyelid, and therefore admitting of relief from the operation above indicated.

Epicanthus.

This name has been coined to designate a congenital peculiarity, which consists of a fold of skin extending from the side of the root of the nose over the inner canthus of the eye. The free edge of the fold is crescentic, and its extremities are lost in the skin of the upper and lower eyelids. Dr. Ammon, to whom we are indebted

for the name, has performed an operation for the obliteration of the folds, which consists in the vertical excision of an elliptical piece of skin from over the root of the nose on a level with the epicanthus, and then bringing the edges of the wound together by suture. It is seldom, however, that epicanthus impedes the movements of the eyelids so much as to render any operation necessary. The folds, moreover, usually disappear as the child's nose increases in prominence.

Epicanthus has been imagined to dispose to squinting, and this has been considered a reason for operating. I have seen cases in which the child squinted, but also many in which there was no squint.

I have in short never seen any necessity for operating.

Section III.—Morbid Connections of the Eyelids.

Anchyloblepharon.

This, which is not of very common occurrence, is an adhesion of the eyelids to each other by their borders.

Anchyloblepharon is distinguished into *mediate* and *immediate*, according as the adhesion is through the medium of a false membrane, or without any intervening substance; and into *partial* and *total*, according as the borders of the eyelids are united in part only, or in their whole extent.

In partial anchyloblepharon the adhesion is usually towards the outer angle. In total anchyloblepharon, the edges of the secondary fissure at the inner canthus are seldom or never adherent, so that there is an opening at the inner angle leading into the oculo-palpebral space of the conjunctiva.

Anchyloblepharon is either congenital or acquired.

Congenital anchyloblepharon is generally total,[1] and either mediate or immediate, and often coexists with imperfect development of the eyeball.

Acquired anchyloblepharon is generally the consequence of excoriations by burns or escharotics, in which case it is often complicated with symblepharon, or adhesion of the lids to the eyeball, or of such inflammations as are attended with excoriation and ulceration of the tarsal borders, and generally only partial.

Partial anchyloblepharon is to be distinguished from *phimosis palpebrarum*, which is properly contraction of the palpebral fissure from transverse shortening of the borders of the eyelids, accompanied by contraction (pp. 187, 407).

[1] An opening at the inner canthus commonly exists; sometimes an opening at the outer canthus has been met with; in other cases no opening at either canthus, but one in the the middle.

Supposing the eye otherwise sound, the effect of anchyloblepharon is of course to impede or wholly prevent the exercise of vision, according as it is partial or total; but very often, anchyloblepharon is complicated with symblepharon, or adhesion of the eyelid to the eyeball, or with some other defect of the latter, viz., such as may arise from the same injury or inflammation which gave occasion to the adhesion of the eyelids, or, in the case of congenital anchyloblepharon, imperfect development of the eyeball.

Prognosis and treatment.—The treatment consists in separation of the adhesion with the knife; but in cases of total anchyloblepharon, it is necessary before proceeding to operate, to direct attention to the state of the eyeball as regards prominence and firmness, and whether or not the case is complicated with symblepharon, or adhesion of the eyelid to the eyeball. The degree of sensibility to light ought also to be had regard to as an indication of the condition of the eyeball.

To determine whether or not the case is complicated with symblepharon, or adhesion of the eyelid to the eyeball, the united eyelids are to be pinched up into a fold, and the patient desired to move the eyeball about and to make efforts as if to open and shut the eye. During this, the attention of the surgeon is to be directed as to whether the eyeball moves freely or not behind the eyelids. The point may be also ascertained by passing a probe through the opening at the inner or outer angle, if such exist, and observing whether or not it can be freely moved up and down in the oculo-palpebral space.

The operation for partial anchyloblepharon is performed by passing a director behind the part where the borders of the eyelids adhere, whilst an assistant stretches the upper eyelid upwards, and the lower downwards, and separating them with a scalpel, taking care, in case of immediate union, not to cut the proper substance of the tarsus either of the one or other eyelid. If the anchyloblepharon be mediate, the false membrane is to be detached first from the border of the lower eyelid, and then from that of the upper, a scalpel or scissors being the instrument employed, according to the thickness and connections of the false membrane.

In the case of total anchyloblepharon, if there is an opening at the inner angle, a director or probe is to be passed through it behind the united eyelids, and their separation effected in a manner similar to that just indicated. If, however, there is no opening, the united eyelids are to be pinched up into a vertical fold and drawn from the eyeball, the assistant taking charge of the upper eyelid, the surgeon himself the lower, and the united edges separated at the part. Through the opening thus made the director is passed, and run along, first to the inner angle, and the adhesion

divided in that direction, and then to the outer angle, and the adhesion divided in that direction.

The operation which has now been described, it will be observed, is of comparatively easy performance, but the tendency to re-adhesion constitutes the great obstacle to a successful issue, especially in cases in which the anchyloblepharon has arisen from burns and the action of escharotics.

To prevent reunion, the eyelids should be frequently drawn from each other after the operation, and the raw borders smeared with tutty ointment, until cicatrization takes place. What is very likely to prove useful, is to promote union between the skin and conjunctiva at the external angle, by means of a suture.

Symblepharon.

This is adhesion of the conjunctival surface of one or both eyelids to that of the eyeball. The cornea is generally more or less involved in the adhesion. It may be either *mediate* or *immediate*, *total* or *partial*, and may exist in complication with anchyloblepharon.

Symblepharon is usually the consequence of injury of the conjunctiva from the action of escharotics intruded into the eye (p. 91).

The contraction of the conjunctiva, with obliteration of the palpebral sinuses, above referred to under the head of Xerophthalmia (p. 187), has been called *symblepharon posterius*, but it differs from the symblepharon under consideration as essentially as phimosis palpebrarum, with which it generally coexists, does from anchyloblepharon (p. 405).

Prognosis and treatment.—The morbid adhesion between the eyelid and the eyeball may be readily separated by the knife, but re-establishment of the adhesion is as prone to take place as in anchyloblepharon, or more so. Even in partial mediate symblepharon, the bands or frœna have been generally found to be reproduced.

In some cases of this sort, better success might perhaps be obtained by first cutting the band or frœnum at its connection with the eyeball, and uniting the wound of the conjunctiva with a few stitches of fine thread, the band or frœnum being left in connection with the eyelid, and only removed, if necessary, after the union of the wound of the conjunctiva, supposing it to take place.

Section IV.—Tumors, Cancer, etc., of the Eyelids and Eyebrows.

Phlyctenulæ on the borders of the eyelids, from obstruction of the Meibomian apertures and retention of the secretion.

This state, which has been above noticed (p. 42), gives rise to some uneasiness in the part, especially when the eyelids are moved. The film which forms the walls of the phlyctenula will give way of itself, and the accumulated secretion be allowed to escape; but removal may be at once effected by lacerating the phlyctenula with the point of a pin.

Meibomian calculus.

Small calcareous concretions sometimes form apparently in the Meibomian glands, and are seen shining through the palpebral conjunctiva on everting the eyelid. Sometimes they project on the surface of the conjunctiva, acting thus as a cause of irritation to the eye. The removal of such a calculus becomes necessary. It is effected by dividing the conjunctiva over it, with the point of a lancet and turning it out with a Daviel's spoon.

Enlargement and induration of the Meibomian glands.

When the Meibomian glands are thus affected, they are felt under the skin like strings, besides forming prominences towards the borders of the eyelids.

Alteratives and tonics generally, and friction with camphorated mercurial ointment locally, constitute the only admissible treatment.

Abnormal occurrence of a sebaceous gland in the palpebral conjunctiva of the upper eyelid.

I have been twice applied to by patients complaining of a feeling as if some foreign body were in the eye, and on examination have discovered a small mass of sebaceous matter, like what may be squeezed out from one of the sebaceous glands of the nose, only somewhat firmer and clearer, contained in a follicle in the conjunctiva over the tarsal cartilage and protruding at the surface. This sebaceous mass, like the contents of a sebaceous gland of the skin, was readily pressed out.

Vesicles or phlyctenulæ on the cutaneous surface of the eyelid near its margin.

Vesicles or phlyctenulæ, containing a watery fluid, are sometimes met with, single or several together, and of a size from that of a mustard seed to the size of a pea. The evacuation of the fluid by

a puncture with a lancet is sometimes sufficient for the removal of these vesicles; if not, the vesicle is to be snipped off with scissors.

Warts on the eyelids.

Warts are not uncommon on the cutaneous surface of the eyelids or on their border.

If pedunculated, it is best to remove them by ligature, or at once to snip them off with the scissors, and then to touch the root with strong acetic acid or lunar caustic. If they have a broad base, their removal may be effected by the escharotics alone.

Horny-like excrescences connected with the skin of the eyelids.

One of the minute sebaceous follicles of the skin of the eyelids, especially of the lower, may become enlarged, and give out a morbid secretion, which, hardening as it is produced, does not fall away on being thrust out by successive additions, but forms the horny-like excrescences under consideration. The portion of skin in which the excrescence has its root, is to be snipped off in a fold with the scissors.

Milium.

A small white pearly-looking tumor, of about the size of a pin's head, called *milium*, often presents itself in greater or less numbers in the skin of the cheeks and eyelids, situated apparently immediately underneath the epidermis, which they raise up and through which they shine.

Composed of a comparatively thick capsule without opening, in which is contained a sebaceous-looking matter, milia are quite different from enlargements of the common sebaceous follicles produced by accumulated secretion.

The bodies in question are in their natural course thrown off by the giving way of the epidermis covering them, and may be succeeded by new ones. They thus appear to be of the same nature as dehiscent glandular cells of the simplest kind.

Their removal, when required, is best effected by carefully scratching through the epidermis covering them with any fine-pointed instrument, taking care not to scratch so deep as to cut the capsule, and squeezing the body out of its nidus between the thumb nails. If the capsule be wounded, it may remain while its contents only escape. The body, when turned out whole, exactly resembles a minute pearl.

Thickwalled encysted tumors.[1]

Large tumors—of the size of a horse-bean, or even greater—but apparently of the same nature as the miliary ones just described, are sometimes met with, especially in children, imbedded in the skin and subcutaneous cellular tissue of the eyelids.

The capsule part of the tumor is white, very thick, sometimes of considerable, almost gristly consistence, and rough and tuberculated on its surface.

The removal of such a tumor is most easily effected by dividing it, as well as the investing integument, with a stroke of a lancet, and then by pressure squeezing out the halves of the thick cyst from their nidus. The wound left quickly heals.

These tumors sometimes occur in a considerable number, and of different sizes, in the eyelids, eyebrows, forehead, and cheek.

Chalazion,[2] *or tarsal tumor.*

This tumor is situated in the substance of the tarsal cartilage, usually some little way from the margin of the eyelid, and tends more to its inner than its outer suface. It does not in general cause any great elevation of the skin of the eyelid, or other marked appearance externally. On everting the eyelid, the conjunctiva at the place is observed to be livid red, and elevated, but sometimes depressed in the middle. As the tumor increases, the conjunctiva becomes thin, and at last gives way, when a small fungus-like substance rises from the opening. Suppuration may take place in the tumor around its nucleus.

The tumor consists of a gelatiniform fibrinous matter, not encysted, but simply contained in a cavity it has formed for itself by accumulating in the substance of the tarsal cartilage.

Treatment.—If, as is frequently the case, the patient be dyspeptic, by improving the state of the digestive organs, the tumor may be arrested in its progress and even altogether dispersed. Locally friction with camphorated mercurial ointment may be employed.

If the tumor, however, has already become large, and presses disagreeably on the eyeball, it ought to be removed. The operation consists in everting the eyelid, making a free incision into the tumor, and pressing out its contents so far as they admit of it; what remains is to be broken up by means of Daviel's spoon introduced through the wound. [It is well to increase the irritation by introducing nitrate of silver or the point of a silver probe, previously dipped in nitric acid, into the wound, as the tumor is apt to return.]

[1] Albuminous tumor;—Molluscum contagiosum;—Glandiform tumor.
[2] Fibrinous tumor, Mackenzie.

When more prominent externally than internally the incision may be made through the skin over the tumor parallel to the margin of the eyelid.

It may happen that two tumors lie close together, and one only be evacuated by the incision. Should this prove to be the case, the incision is to be extended to the second tumor, and its contents pressed out. Of two tumors, one may be more prominent internally, the other externally.

A chalazion giving way, a fungus-like excrescence, as above mentioned, arises from its bottom. This may continue without farther trace of the chalazion.

An incision being made on each side of its base, it is to be cut out by the root with a pair of curved scissors.

Encysted tumor.

Encysted tumors, sometimes congenital, are occasionally met with in the eyelids, especially the upper, towards the temporal side. They are situated under the orbicularis palpebrarum, and are often adherent to the periosteum of the margin of the orbit. The cyst is thin but firm, and the contents, a fatty or glairy matter, sometimes mixed with hairs.

For the removal of such tumors, the following general directions only can be given:

1st. The external incision should be free, and in the direction of the orbicularis palpebrarum.

2d. The cyst should be dissected out entire, if possible. At any rate, it must all be extirpated. If any part of it is left, which without care might happen in regard to that part of it adhering to the bone, the wound will not heal, and disease and exfoliation of the bone may take place.

Hydatids in the cellular substance of the eyelids.

Dr. Mackenzie mentions a case of swelling over the temple and zygoma, from which, by puncture from within the mouth, a glairy fluid and a number of hydatids were discharged. After this an abscess formed in the upper lid, in the pus evacuated from which there were contained several hydatids.

Nævus maternus and aneurism by anastomosis of the region of the eyelids.

The skin of this region, as well as that of any other part of the body, is occasionally found to be the seat of that form of nævus, called *mole*, in which a circumscribed part of the skin is thickened, of a brown color, and covered with hair.

Nævus or aneurism by anastomosis also sometimes implicates the eyelids.

The various methods of treating nævi or aneurism by anastomosis which have been adopted, are:—pressure—cautery, actual or potential—vaccination—escharotic and irritant injections into the tumor—incision of the vessels within the tumor—seton—ligature—excision—ligature of the carotid.

The details of these various plans of treatment belong to general surgery.

Scirrhoid callosity of the eyelids.

A hard, tuberculated, warty-like degeneration of the whole thickness of the eyelid, commonly the lower, at the tarsal border to a greater or less extent, traversed by varicose vessels, and ending in ulceration, sometimes occurs, especially in old people. Though resembling, it is not of the nature of scirrhus.

If not irritated, it may remain stationary. Sometimes, however, it causes so much irritation to the eye, and produces so much deformity, that the patient seeks for its removal by operation.

The operation consists simply in the amputation of the diseased part.

Cancer of the eyelids.

Cancer commences more commonly in the lower eyelid than in the upper, and first manifests itself as a small indurated tubercle, at the edge of the eyelid, or towards one or other angle, over which the skin may be otherwise natural, except that it is pervaded by varicose vessels, and which is little or not at all painful. This tubercle is followed by others.

This stage of the disease—*the stage of induration*—after remaining for an indefinite time, is succeeded by *ulceration*. The ulcer is smooth and destitute of granulations, and the discharge from it is not unhealthy-looking. The edges of the ulcer are knotted and irregular, but the surrounding skin is natural. The ulceration may be arrested for a time, and again proceed, or while it stops at one part it goes on at another.

Though the ulceration may eventually eat away not only the whole eyelids, but also the neighboring parts, it does so very slowly, perhaps only in the course of years.

In the progress of the disease, the eyeball may be destroyed by ulceration and bursting of the cornea with evacuation of the humors, but this appears to be sometimes the effect rather of common inflammation of the eyeball, from the exposure to which it is subjected by the loss of its protecting parts, than of extension of the cancerous disease.

Inconsiderable suffering in general attends the stage of ulceration,

but when nerves are exposed, or when the eyeball bursts, there is severe pain.

The neighboring lymphatic glands do not become contaminated, and the general health does not suffer.

Cancer of the eyelids, which is an uncommon disease, does not occur before the middle period of life.

From syphilitic ulceration of the eyelids above described, cancerous ulceration may be distinguished by the slowness of its progress, and the natural state of the surrounding integuments, together with the history of the case.

Treatment.—While the disease is yet confined to the eyelids, the only effectual treatment is removal of the affected parts with the knife, together with a portion of the healthy structure immediately around.

It is to be observed, that though a very large portion of the eyelids is removed, the eyeball may, after recovery, be still pretty well protected by the elongation of what remains, and that even though the lacrymal papillæ and canalicules be cut away, no stillicidium lacrymarum ensues.

Though the disease has already extended its ravages so far as to have destroyed the eyelids and neighboring parts, antiphlogistic and anodyne remedies will still be found useful, not only in palliating symptoms, but even in retarding the progress of the disease.

The eyelids and conjunctiva are sometimes implicated in melanosis, but it is not necessary to go particularly into the subject.

Phtheiriasis of the eyebrows and eyelashes.

Pediculi on the eyebrows or edges of the eyelids keep up a state of chronic inflammation, and cause intolerable itching.

Treatment.—After as many of the eyelashes have been plucked out as are loose enough to yield to the force exerted by means of the finger and thumb, the eyebrows, and edges of the eyelids, are to be smeared with some mercurial salve, such as the strong red precipitate or citrine, twice a day. After which an attempt is to be made to dislodge the insects from the eyebrows by means of a fine comb; from the eyelashes, by means of a small spatula or forceps.

CHAPTER VIII.

Section I.—Diseases of the Conjunctiva.

Pterygium.[1]

This is a vascular and thickened state of a circumscribed portion of the conjunctiva of a triangular form, the apex corresponding to the cornea, on which it encroaches to a greater or less extent; the base corresponding to the circumference of the eyeball. The connection between the portion of conjunctiva implicated and the subjacent sclerotica, continues as loose as in the natural state.

Fig. 87.

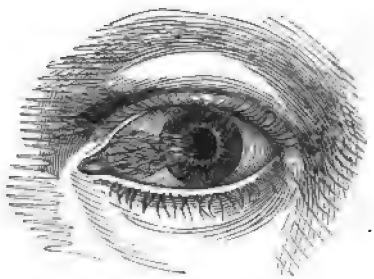

Pterygium has its seat generally on the nasal side of the eye, in which case its base corresponds to, and is incorporated with, the semilunar fold, but that it is not in its nature an extension of that fold of conjunctiva is proved by the circumstance, that pterygium sometimes occurs on the temporal side, and even, though more rarely, on the upper or lower side of the eye.

Moreover, in many cases, if not in all, the disease appears to begin by the formation of what ultimately forms its apex, close to the edge of the cornea, before any thickening or unnatural vascularity of the conjunctiva is observable.

The disease is of consequence only when it implicates the conjunctiva corneæ so far that the vascularity and thickening extend to the middle of the cornea and obstruct the pupil.

Both the nasal and temporal sides of the same eye are sometimes the seat of pterygium. Cases have been met with in which ptery-

[1] Web.

gium existed not only on the nasal and temporal, but also on the upper and lower sides of the same eye.

Two degrees of pterygium are met with, viz., *pterygium tenue vel membranosum*, and *pterygium crassum vel musculosum*; the former thin and semi-transparent, the latter thick and fleshy-looking.

Causes.—Nothing certain has been made out on this head. The subjects of it are generally old persons. It sometimes takes its origin in chronic inflammation of the conjunctiva. The affection has been most frequently met with in laborers whose work exposed them to the entrance of mortar and stone dust into the eye, and in persons who have been long resident in hot climates. Dr. Mackenzie mentions that he has seen a particle of gunpowder, which had been lodged for years under the conjunctiva, at last cause pterygium.

Diagnosis.—Partial mediate symblepharon is apt to be confounded with pterygium. Indeed, many of the cases which have been described and delineated as examples of superior and inferior pterygium, appear to be examples rather of partial mediate symblepharon.

Prognosis.—The morbid state of the conjunctiva under consideration, is not disposed to disappear spontaneously, but it may remain stationary or be long before it extends so far on the cornea as to interfere with vision. If mistreated, it may degenerate into a fungous excrescence covering the whole cornea.

Treatment.—Pterygium may sometimes be removed by frequently touching it with the nitrate of silver solution or with vinum opii. If, however, it does not yield to this treatment, and if it has extended so far on the cornea as to obstruct vision, its removal by operation becomes necessary.

Operation for the removal of pterygium.—The patient being seated as for the operation for cataract, and both eyelids secured by an assistant, the surgeon, while the patient turns the eye outward, if the pterygium be on the nasal side, with a hooked forceps seizes the pterygium about its middle, and, whilst keeping it raised from the surface of the sclerotica, he passes a cataract or iris knife with the edge towards the cornea, and one of the flat surfaces of the blade towards the sclerotica, behind it, and detaches it from the sclerotica by cutting inwards as far as the margin of the cornea, where the knife is to be made to cut itself out. Still keeping hold of the pterygium with the forceps, he now with the same knife, or with a pair of curved scissors, separates the pterygium towards its base, where it is to be cut away without encroaching too near the semilunar fold, if it be an internal pterygium.

After the operation cold applications are made to the eye.

Pinguecula.[1]

This is a small whitish-yellow tumor, from the size of a pin's head to that of a small pea, in the sclerotic conjunctiva and subjacent cellular tissue, close to the margin of the cornea on its nasal or temporal side. It is so called from its being supposed to be a deposition of fat, though erroneously, as shown by Weller, who found it to be of an albuminous nature. One or two of the rectal vessels, enlarged and varicose, usually run into it.

Pinguecula, which is of very common occurrence towards the middle period of life, can scarcely be viewed as morbid, inasmuch as it occasions no inconvenience of any kind. When its removal is required, it is only for the sake of appearance. Being seized with a hooked forceps, and raised, the tumor and a small portion of the surrounding conjunctiva are to be snipped off transversely with a pair of curved scissors.

In a case of large pinguecula, I observed that it was pinched up between the edges of the eyelids when the latter closed. This led me to examine other cases, when I found that the pinguecula always ocupies that part of the conjunctiva which, when loose, it apt to be pinched between the borders of the eyelids. It is probable, therefore, that pinguecula owes its origin to the constant slight irritation thereby occasioned.

Trichosis bulbi.

This is a small congenital tumor with hairs growing from it, analogous to those of the skin called *moles*, occasionally met with on the white of the eye, close to the margin of the cornea, on

Fig. 88.

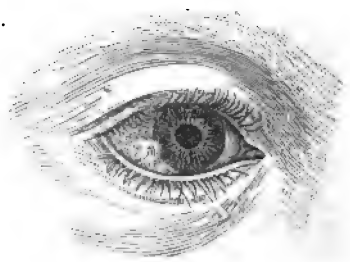

which it perhaps slightly encroaches. The tumor here delineated, which I removed, was composed of pretty dense tissue, similar to

[1] Pterygium pingue.

that of the sclerotica, with which indeed it was incorporated, covered with conjunctiva, in which the hairs had their roots. It is said that such tumors are sometimes fatty. Similar tumors, but without hairs growing from them, are met with. In a case mentioned by Mr. Wardrop, hairs did not appear until the time of puberty.

The tumor being not only a blemish, but sooner or later a source of irritation, its removal is desired, and may be readily effected by seizing it with the hooked forceps, whilst an assistant holds the eyelids asunder, and either transfixing it at its base with a knife, detaching it on the side next the cornea, and then completing its removal with the same knife, or with scissors, in the manner above recommended for pterygium, or at once snipping it off in a transverse direction close to its root, with a pair of sharp curved scissors.

Abnormal development or hypertrophy of the conjunctiva corneæ.

An extension of membrane like sclerotic conjunctiva, over a part of the cornea, is sometimes met with.

Fungous excrescence of the conjunctiva corneæ.

The whole cornea may be covered with a fungous excrescence, tuberculated on the surface, and of a red or livid color.

Various kinds of tumors of the conjunctiva.

Polypi and warts, pedunculated or sessile, may be met with growing from any part of the conjunctiva. They should be removed by excision with the curved scissors.

Small hard vesicular tumors, of the size of pins' heads, are sometimes presented by the sclerotic conjunctiva. If seized and crushed with a hooked forceps they will disappear. They may, however, be at once snipped off with the scissors.

Hydatids in the cellular tissue under the sclerotic conjunctiva.

Acephalocysts and cysticerci have been occasionally met with under the sclerotic conjunctiva. They give rise to a vesicular tumor about the size of a pea in general unaccompanied by inflammation or any other inconvenience. On dividing the conjunctiva, the hydatid readily escapes.

A gentleman, between 50 and 60, consulted me about a small vesicular tumor under the conjunctiva, between the semilunar fold

and the inner margin of the cornea. On examination, I found it could be made to slide in the subconjunctival cellular tissue. With a fine hooked forceps, I raised the conjunctiva in a fold and snipped it across with scissors, whereupon the vesicle slipped out and was received upon the edge of the lower eyelid. It was of the shape of an egg, and about a quarter of an inch in the long diameter, whitish. Though like a cysticercus, it proved on close examination to be an acephalocyst.

I saw the patient again a fortnight after, when I found the wound of the conjunctiva healed, but some slight fulness of the vessels and increased Meibomian discharge, for which I prescribed an eye-water and salve.

The following case occurred to Mr. Canton, who kindly afforded me an opportunity of examining the cysticercus:

Wm. S——, aged two years and seven months, a child of strumous diathesis, was brought as a patient to the Royal Westminster Ophthalmic Hospital. Seven months ago, its right eye was touched accidentally by the point of an umbrella, without giving rise, however, to any unpleasant symptom. A week or two afterwards, the father, on depressing the lower eyelid, observed, for the first time, a tumor attached to the eyeball, about the size of a small pea, and which the lid had entirely concealed from view. The tumor has, from that period to the present, been slowly and steadily on the increase, without producing any inconvenience.

The lower eyelid was now noticed to be slightly bulged forwards, near the inner canthus, and, upon depressing it, an oval tumor projected, the seat of which was the cellular tissue between the sclerotica and conjunctiva. Its size was that of the little finger nail, and it had so encroached upon the inferior palpebral sinus, that when the lids were even widely apart, it was completely concealed from view. Its consistence was that of soft jelly, and the color, so far as it could be judged of through the rather vascular conjunctiva stretched over it, was yellowish. Vision was perfect, and the general appearance of the eye healthy, with the exception of the slight congestion just alluded to. The tumor did not appear to cause the child any annoyance, or to interfere with the movements of the eyeball or lids, but the father wishing to have it removed, I depressed the lower lid as far as possible, and with a curved pair of scissors cut away an elliptical piece of conjunctiva from the most prominent part of the swelling. A small quantity of thin, yellowish fluid, issued, together with a cysticercus—the two having composed the bulk of the little tumor. The edges of the wound were, at the end of two or three days, fully united.

The entozoon was perfect, about the size of a large garden pea.[1]

[1] The Lancet, July 22, 1848.

Filaria medinensis, or Guinea worm.

Cases of the Guinea worm under the conjunctiva are on record.

Section II.—Diseases of the Semilunar Fold and Lacrymal Caruncle.

The *lacrymal caruncle* consists of a mass of fibrous tissue similar to that of the tarsal cartilages, in which are imbedded follicles secreting a fluid of the same nature as that of the Meibomian glands, and pouring it out by twelve or fifteen excretory orifices on its surface, which is invested by the conjunctiva.[1] In the healthy state the lacrymal caruncle is of a yellowish-red color, slightly tuberculated on the surface, which, in addition to the excretory orifices, is beset with very delicate scarcely visible hairs.

The *semilunar fold of conjunctiva*, which encloses at its free edge a minute portion of fibrous tissue, similar in nature to the tarsal cartilages, is distinguished from the ocular portion of the conjunctiva by its reddish color and greater thickness.

Inflammation of the semilunar fold and lacrymal caruncle.[2]

In the puromucous ophthalmiæ the semilunar fold and lacrymal caruncle are always very much affected,[3] but they are sometimes found the principal seat of inflammation; and this, especially as regards the lacrymal caruncle, occurs under two forms, viz., what may be called catarrhal, and what may be called phlegmonous.

Catarrhal inflammation of the semilunar fold and lacrymal caruncle.

The conjunctiva forming the semilunar fold, and investing the lacrymal caruncle is the principal seat of this inflammation, which is in its nature very analogous to catarrhal ophthalmia tarsi (p. 374, et seq.)

Symptoms.—The semilunar fold and lacrymal caruncle are very red and much swollen, as also the neighboring parts more or less, and puriform mucus by-and-by collects in considerable quantity at

[1] Anciently the lacrymal caruncle was thought to be the secreting organ of the tears, and the lacrymal points the excretory orifices.

[2] Encanthis inflammatoria.

[3] The semilunar fold may be so much enlarged in purulent ophthalmia, as to resemble the membrana nictitans of quadrupeds, of which it is naturally the miniature analogue. In this state of enlargement, I have seen a surgeon cut a considerable piece of it away, under the erroneous impression that it was an excrescence from the conjunctiva.

the inner angle, the result of increased secretion from the conjunctiva and from the follicles of the caruncle.

There is a sensation as if a foreign body were lodged at the inner angle of the eye, and considerable lancinating pain, especially when the eyelids are moved.

In consequence of the displacement of the lacrymal papillæ and puncta, as well as their implication in the inflammation, the tears which collect in the lacus lacrymalis are not duly absorbed, and therefore drop down over the cheek.

Causes.—After cold, the irritation of inverted eyelashes and of foreign bodies appears to be the most common cause. The foreign bodies may be lodged behind the semilunar fold. A loose eyelash has sometimes been found to have accidentally entered one of the puncta by one end, and by its free end pointed against and irritating the semilunar fold and caruncle, to be the source of the irritation which has excited and which keeps up the inflammation.

Treatment.—All causes of irritation, if any still exist, being removed, the inflammation will sometimes subside under the use of fomentations with tepid water, rest to the eye, attention to diet, and a little laxative medicine. If not, the local applications recommended in catarrhal ophthalmia will be necessary (p. 120), with perhaps a leech or two to the skin at the inner angle.

Inflammation and abscess of the lacrymal caruncle.

This is altogether analogous to abscess of the Meibomian glands. The symptoms are at first similar to those of catarrhal inflammation of the semilunar fold and lacrymal caruncle, but as suppuration takes place, the pain becomes throbbing, the redness darker, and the swelling greater, until it presents a yellow point, usually between the caruncle and semilunar fold. This point bursting, or being opened with the lancet, the abscess is evacuated; whereupon the symptoms subside, and the part heals. As a consequence of the suppuration, atrophy of the caruncle sometimes takes place.

Treatment.—When suppuration is threatened, warm fomentations are to be applied to the inner angle, and as soon as fluctuation is perceptible, or a yellow point presents itself, the abscess is to be opened with a lancet.

Chronic enlargement of the lacrymal caruncle and semilunar fold.[1]

Chronic enlargement of the lacrymal caruncle and semilunar fold sometimes occurs, and presents itself in the form of a red, soft tumor, tuberculated on the surface, bleeding readily on being touched,

[1] Encanthis fungosa, Encanthis benigna.

without pain, and of a size sometimes as great, it is alleged, as that of a nut, from which the semilunar fold in the form of wing-like processes extends behind the upper and lower eyelids.

Treatment.—As reduction of the tumor is sometimes eventually effected by simply pencilling it with the solution of the nitrate of silver or sulphate of copper, or with vinum opii, the surgeon must not proceed hurriedly to excise any part of the enlarged caruncle before giving these remedies a full and fair trial. If a portion of it should be removed, the caruncle, supposing it afterwards recovered its healthy condition, would be so much reduced in size, that it would no longer support the lacrymal papillæ and puncta in their proper adjustment to the lacus lacrymalis, the consequence of which would be incurable stillicidium lacrymarum.

If, notwithstanding perseverance in the treatment indicated, the enlargement of the caruncle persists, its reduction must be attempted by means either of caustic or excision.

Cauterization.—The solid nitrate of silver is the caustic employed, and the manner of applying it is the same as is recommended in cases of enlarged tonsils, viz., to hold the point of the caustic pencil on the tumor until a small eschar has formed. This is done on different parts of the tumor, and repeated as the eschars fall away.

Excision.—A portion of the enlarged caruncle—one-half, or even two-thirds of it—may be excised, as is done in the case of enlarged tonsils. The eyelids being properly secured by an assistant, the excision is readily effected with the curved scissors, the surgeon first seizing the tumor by means of the hooked forceps.

Polypous and fungous excrescences of the lacrymal caruncle and semilunar fluid.

Polypous and fungous excrescences occasionally grow from the semilunar fold, or lacrymal caruncle, or between the two, inflammation having, or having not, previously existed. They may be sessile, and no larger than a pin's head, or they may be pedunculated, and of considerable size.

Small sessile excrescences I have seen cease to grow and eventually disappear without any interference. When this is not the case, and if they are large and cause inconvenience, they should be touched with the nitrate of silver in solution or substance; or if pedunculated and large, they are first to be snipped off with the scissors, and their root touched with the caustic.

Cancer of the lacrymal caruncle.[1]

Some authors speak of cancerous disease primarily affecting the lacrymal caruncle, but this either does not occur at all, or is very rare. Implication of the lacrymal caruncle, however, in cancer commencing in neighboring parts, sometimes occurs.

CHAPTER IX.

DISEASES OF THE LACRYMAL ORGANS.

SECTION I.—DISEASES OF THE SECRETING LACRYMAL ORGANS.

Disordered states of the lacrymal secretion.

The secretion of the lacrymal gland may be suppressed, or, on the contrary, it may be poured out in too great abundance. These disordered states of the lacrymal secretion, it is well known, are frequently the result of mental affections. Suppression of the secretion is more common in old age, excess of secretion in youth.

In all cases these states are to be viewed in the light rather of symptoms than of diseases in themselves. They may both of them present themselves indeed in different stages of one and the same disease.

Suppression of the lacrymal secretion.[2]

Dryness of the eye from suppression of the secretion of the lacrymal gland, has been distinguished from dryness of the eye depending on defective secretion of mucus by the conjunctiva; but it may be questioned whether a suppression of the secretion of the lacrymal gland, independently of any disturbance of the conjunctival secretion, is a cause of dryness of the eye, for in cases in which the lacrymal gland has been extirpated, the eye has continued to be sufficiently moistened by the conjunctival secretion, which in fact is the ordinary means of moistening the eye.

The dryness of the eye which sometimes attends amaurosis, appears to be owing to a disturbance in the secretory action as well of the conjunctiva as of the lacrymal gland.

Obliteration of the excretory ducts of the lacrymal gland is spoken of as a cause of lacrymal xerophthalmia, but such a condition appears to be, as I have above expressed my belief, rather assumed than unequivocally established by any direct observation.

[1] Encanthis maligna. [2] Lacrymal Xeroma.

The fact appears to be, that as above stated (p. 187, et seq.), xerophthalmia is always conjunctival, depending on a cuticular state of conjunctiva, and that the secretion of the lacrymal gland may or may not be suppressed.[1]

Epiphora, or watery eye.

This is superabundant secretion of tears, and most commonly presents itself as a symptom of irritation of the conjunctiva. This irritation may be owing to inflammation, especially scrofulous inflammation of the membrane, or, as is well known, to the action of chemical or mechanical agents—cold winds, acrid vapors, or foreign particles in the oculo-palpebral space, inverted eyelashes, &c.

Epiphora, as above pointed out (p. 46), is to be distinguished from *stillicidium lacrymarum*, another form of watery eye, the latter arising not from superabundant secretion, but from a morbid state of the derivative lacrymal organs, whereby they are unable to draw off into the nose the fluid which is always collecting in the lacus lacrymalis at the inner corner of the eye. But as the morbid state of the derivative lacrymal organs is frequently accompanied by an irritable state of the conjunctiva, epiphora may exist at the same time with stillicidium lacrymarum.[2]

Treatment.—The treatment is, of course, the removal of the cause, whether inflammation, of whatever kind it may be, or chemical or mechanical irritants of the conjunctiva, &c.

Inflammation of the lacrymal gland.

Inflammation of the lacrymal gland is not of common occurrence; and although acute and chronic forms of it have been described, there are no very certain marks by which they may be distinguished, beyond pain and fulness in the situation of the lacrymal gland accompanying suppression of the lacrymal secretion in the acute form, but increased secretion in the chronic, with displacement of the eyeball downwards and inwards.

The obvious treatment in such cases is the application of leeches and fomentations to the part, and the usual general remedies.

Inflammation going on to suppuration sometimes occurs in the situation of the lacrymal gland, generally in consequence of blows. In such cases the abscess is probably in the cellular tissue in or around the gland, and may present all the severe symptoms and displacement of the eyeball, attending orbital abscess, into which,

[1] Obliteration of some of the ducts of the lacrymal gland has been alleged to be the condition of another disease, viz., dacryops, or lacrymal tumor of the upper eyelid.

[2] Some authors employ stillicidium lacrymarum in the sense in which epiphora is above used.

indeed, it may merge. It may become complicated with disease of the bone. In the latter case, after the abscess has burst or been opened, there remains a fistula, which cannot heal until the diseased portion of bone has exfoliated; but besides that, the skin around becomes diseased, and is so drawn in or contracted by cicatrices at the fistulous opening, that ectropium or lagophthalmos is produced.

The bad results which may follow an abscess in, or in the situation of the lacrymal gland, should induce the surgeon to be particularly circumspect in the management of such a case. If it is found resolution cannot be effected, as soon as the accumulation of matter is distinctly recognized, an issue is to be given to it, by an incision through the skin parallel to the margin of the orbit. In dressing the part afterwards, great attention must be paid to prevent the skin from being drawn in and contracted in a bad cicatrice.

Should the bone be found diseased, of course no attempt need be made to promote cicatrization until exfoliation of the diseased portion, which is always a tedious process; but even then the neighboring skin is generally in so diseased a state, that contraction and bad cicatrization, with consequent lagophthalmos and ectropium, can scarcely be prevented.

Fistula of the lacrymal gland or true lacrymal fistula.

A minute fistulous opening, situated on the upper eyelid, towards the outer canthus, and under the margin of the orbit in the situation of the lacrymal gland, and from which a clear fluid discharges, has been said by Beer and others occasionally to remain after injury, or the bursting of an acute abscess in the lacrymal gland. In one such case Beer effected a cure, by thrusting into the fistula, which was about a quarter of an inch deep, a knitting-needle made red hot.

Extirpation of tumors in the neighborhood of the lacrymal gland, or of the diseased gland itself.

Tumors sometimes occur in the neighborhood of the lacrymal gland without this being itself diseased, but the appearance externally may be such as to lead to the supposition that it is the gland itself which is enlarged and diseased. This should always be kept in mind in proceeding to the extirpation of what may be considered a diseased gland, and the operation proceeded in with great circumspection.

After the exposure of the tumor by incision of the skin, careful examination should be made to determine whether or not the tumor

be really the lacrymal gland diseased, or simply a growth developed close by it. A case has occurred in which the operator removed by mistake a healthy lacrymal gland along with a steatomatous tumor.

The disease of the lacrymal gland, for which its extirpation has been undertaken, is enlargement and induration, but whether of a really cancerous nature or not there is a difference of opinion.

Before any enlargement is observed externally, the patient may have suffered from pain in the situation of the lacrymal gland and epiphora. When a tumor becomes perceptible it is hard and knotty. As it increases in size, it forces the eyeball downwards, inwards, and forwards; the consequence is at first double vision from the displacement of the axis of the eye, and subsequently dimness of sight and loss of vision, from the action of the pressure on the retina.

Under these circumstances, extirpation of the diseased gland is indicated, as discutient treatment has usually proved of no avail.

The operation is performed by making an incision through the skin over the tumor parallel to the edge of the orbit, and of a length sufficient fully to lay bare the anterior part of the tumor. This being done, the surgeon will discover on examination of the size and connections of the tumor, if he had not been able to determine before, whether this single incision will suffice, or whether it will be necessary to carry another from its middle, and perpendicular to it upwards, through the skin of the eyebrow. The exposed gland is now to be seized with a hook or hooked forceps, drawn forwards, and separated from its connections with the scalpel.

The tumor being removed, the cavity in which it was seated is to be carefully explored by means of the finger, to ascertain if none of the indurated mass still remains. When the bleeding has ceased, the wound is to be freed from adhering clots, and its edges brought together by suture. A compress and bandage will promote the return of the eyeball to its natural position, and by this the sides of the cavity left by the removal of the tumor will be in a great measure approximated.

It has been recommended in extirpating the eyeball, to extirpate the lacrymal gland also, whether diseased or not. In support of this recommendation, M. Velpeau mentions a case of extirpation of the eyeball, in which the surgeon was forced, six months after, to remove the lacrymal gland which he had left in the orbit, in consequence of the abundant lacrymation which was kept up.

After extirpation of the lacrymal gland, it has been found that the conjunctival surfaces continue to be moist as usual; this appears to depend on their own secretion, and is a proof that xerophthalmia cannot be owing to suppression of the lacrymal secretion alone, but to an accompanying suppression of the conjunctival secretion. In-

deed, it has been above seen that the dryness of eye in *cuticular conjunctiva* exists although there may be no suppression of the lacrymal secretion.

Section II.—Diseases of the Derivative Lacrymal Passages.

Obstruction in some part of the course of these passages is generally an accompaniment of their diseases, and the most marked and troublesome symptom attending it is *stillicidium lacrymarum*, or, as it has been improperly called, *fistula lacrymalis*. It is a dropping of tears from the eye over the cheek, in consequence of the obstruction in the derivative passages preventing their being drawn off into the nose in the natural manner.

Dryness of the nostril of the affected side sometimes attends obstruction of the derivative lacrymal passages. This has been attributed to the non-arrival of the tears into the nose. But if, on the one hand, we take into consideration the quantity of fluid which is received from the eye by the nose, and the small extent of surface in the nose over which that fluid can be dispersed; and on the other the copious secretion of mucus of which the whole lining membrane of the nose is naturally the seat, it will be perceived that the presence or absence of the fluid from the eye can have little if any—I should rather say no, influence on the state of the lining mucous membrane of the nose, as regards dryness or moisture. Dryness of the nostril, it is to be observed, does not always accompany obstruction of the derivative lacrymal passages, and when it does occur, it appears to be owing to diminution or suppression of its own mucous secretion from concomitant inflammation in the part.

The smell, like that of dust, which is sometimes perceived, appears to be a subjective sensation, depending on dryness of the nostril.

Inflammatory swelling, abscess, or sinuous ulcer in the region over the lacrymal sac.

Inflammation of the skin and subjacent cellular tissue in the region over the lacrymal sac sometimes occurs.

Symptoms.—There is at first diffused erysipelatous-like redness and swelling, with pain in the region over the lacrymal sac. The eyelids, conjunctiva, and lacrymal passages are apt to be more or less affected sympathetically, the Meibomian and conjunctival secretions are therefore poured out in increased quantity, whilst the tears, not duly drawn off into the nose, drop over the cheek.

The inflammation in general runs on to the formation of diffuse abscess, *Anchilops* of the older surgeons, the redness at the same time becoming darker, the surrounding œdema greater, and the pain pulsating and severe.

Left to itself, the abscess usually bursts externally, and gives out matter mixed with blood and sloughy cellular tissue, leaving a sinuous ulcer (called by the older surgeons *Ægilops*).

At the same time that a sinuous ulcer is established, the ulceration may extend inwards, perforating the wall of the lacrymal sac, thus giving origin to what is called spurious fistula of the lacrymal sac.

The inflammation under consideration is of the same nature as scrofulous abscess.

The following case will illustrate the progress and treatment of a severe form of this disease:

A girl, æt. 7, has for some time past suffered from inflammation and repeated small abscesses in the region over the lacrymal sac. When she came under my observation I found a small abscess, and the skin livid around.

The matter was evacuated by an incision with a lancet.

After this the affected skin was pencilled with solid caustic at intervals of two days.

A week after, the external swelling was much diminished in size. On pressure over the sac, some tears mixed with flakes of mucus flowed out by the puncta.

The pencilling with the caustic repeated, and iodide of potassium, with decoction of sarsa ordered.

This treatment was continued for about three weeks. Improvement going on slowly, and sometimes interrupted by increased discharge of matter.

After this, the girl was put on a course of cod-liver oil, and had blisters applied occasionally behind the ears. The weaker mercurial ointment was rubbed in over the affected part.

Under this treatment, continued for two or three months, the redness and swelling of the skin at last subsided, and the ulceration healed to a small fistulous opening, through which tears escaped.

Through this opening I subsequently passed a fine probe into the lacrymal sac and nasal duct. This probe I exchanged for a thicker and a thicker at intervals of two days, until a small style could be introduced, which was then left.

Catarrhal inflammation of the derivative lacrymal passages.

In nasal catarrh, the inflammation and tumefaction which affects the pituitary membrane may implicate the mucous membrane of the

derivative lacrymal passages also, so that the transit of the tears to the nose is somewhat obstructed.

A consequence of this is the swimming of the eye in tears, which so often accompanies nasal catarrh. This swimming of the eye is also in part due to an increased discharge of tears from the lacrymal gland occasioned by the catarrhal state in which the conjunctiva also is more or less in such cases.

As the cold in the head subsides, the free passage of the tears is restored. But it may happen that a repetition of such attacks, especially in scrofulous constitutions, shall leave the passages in a chronic blennorrhœal state.

Acute inflammation of the derivative lacrymal passages.[1]

The derivative lacrymal passages are sometimes, though not very often, the seat of idiopathic acute inflammation. The disease is at first characterized by a hard circumscribed swelling, of the size and shape of a horse-bean,[2] in the situation of the lacrymal sac, with great œdema of the eyelids.

The swelling over the sac is red and extremely painful to the slightest touch. The conjunctiva, semilunar fold, caruncle and Meibomian glands are sympathetically affected. There is *stillicidium lacrymarum*. The pain radiates in all directions, and is accompanied by throbbing. To these local symptoms may be superadded inflammatory fever, with sometimes delirium at night.

The inflammation sometimes terminates in resolution, more frequently in abscess. In the latter case, along with increase of the throbbing pain, the swelling enlarges, and becomes darker red, and at last soft, and fluctuating. The œdema of the eyelids and neighboring parts is at the same time much increased.

The canaliculi and nasal duct having been closed by tumefaction of their lining membrane, in an early stage of the attack, the matter accumulates in the sac, which thus appears to be the focus of the disease.

Left to itself, the abscess points and bursts, usually below, though sometimes above, the tendon of the orbicularis palpebrarum. From the closure of the canalicules and nasal duct, there is no escape for the matter through them.

The evacuation of the abscess is followed by great relief; and in favorable cases, the inflammation subsides; the canalicules again become pervious, and allow the passage of the tears into the sac, so that what is now discharged through the fistulous opening is puri-

[1] Acute dacryocystitis, or acute inflammation of the lacrymal sac.

[2] The bean shape of the swelling is owing to the lacrymal sac being somewhat bound down about the middle by the tendon of the orbicularis palpebrarum, whilst above and below it has freer scope to swell.

form mucus mixed with tears. By-and-by the fistulous opening into the sac contracts and closes, while the lining membrane of the latter and of the nasal duct returns to its natural state, and a free passage for the tears into the nose is re-established.

Acute inflammation of the derivative lacrymal passages may not terminate so favorably. The lining membrane of the sac and nasal duct may remain thickened, and in a blennorrhœal state, and the fistulous opening, perhaps, continues, constituting what is called a *fistula of the lacrymal sac.*

Treatment.—In the early stage of the disease, leeches should be applied around the inner angle of the eye, and also to the entrance of the corresponding nostril [or to the temple of the affected side]. In the robust adult, it may be advisable, if the pain be very severe, to abstract blood by venesection. Fomentations are to be applied to the part, rest and abstinence enjoined, and the bowels and skin acted on by laxatives and diaphoretics.

If by these means suppuration should not be averted, the sac is to be opened as soon as it becomes soft and fluctuating, and issue given to its contents. The opening of the sac is effected by thrusting the lancet, held with its flat surfaces parallel to the margin of the orbit, perpendicularly into the part of the distended sac below the tendon of the orbicularis palpebrarum, and, in withdrawing the instrument, enlarging the opening inwards and a little upwards.

After the incision of the sac, the fomentations are to be continued. There should be no sounding with probes; nothing done directly to the parts for the next day or two after the opening of the sac.

When everything has become quiet, and before permitting the opening into the sac to close, the surgeon must satisfy himself of the perviousness of the canaliculi and nasal duct. The absence of stillicidium lacrymarum, and the presence of tears in the sac, will show that the puncta and canalicules are doing their duty; and the entrance into the nose of water, injected into the sac, will show that there is perviousness in that quarter.

If any doubt should remain as to the perfect freedom of the nasal duct, an exploration is to be made by sounding it with a probe.

Chronic inflammation of the derivative lacrymal passages.[1]

Chronic inflammation of the derivative lacrymal passages is usually accompanied by a chronic inflammation of the palpebral conjunctiva, and of the ocular conjunctiva at the inner corner of the eye, so that at first sight the case might be taken for one of catarrhal ophthalmia. But on closer examination, a fulness and perhaps

[1] Chronic dacryocystitis,—Blennorrhœa of the lacrymal sac.

redness, will be perceived in the situation of the sac, and on making pressure at the place, tears, mixed with streaks of puriform mucus, will escape by the puncta, and perhaps also by the nose.

The mucous membrane of the passage is thickened and secretes a puriform mucus. This thickening of the mucous membrane tells most on the perviousness of the nasal duct; for being surrounded by unyielding bony walls, the tumefaction tends inwards, so that the canal becomes so obstructed that the tears can no longer pass. As, however, the puncta and canaliculi generally continue to perform their office of transmitting the tears, the latter accumulate in, and distend the sac, from whence, by pressure on it, they are regurgitated through the puncta, mixed with flakes of the puriform secretion of the diseased mucous membrane, as already mentioned. The regurgitation is sometimes occasioned by the mere pressure exerted by the orbicularis muscle on the distended sac, during the movements of the eyelids.

After the sac has been emptied through the puncta, the eye remains free from stillicidium until the sac again becomes filled, and can no longer receive any more tears.

Chronic inflammation of the derivative lacrymal passages may come on quite imperceptibly, the watering of the eye being the symptom which first attracts the patient's attention. It may succeed to an attack of acute inflammation of the passages, or to an inflammation of the skin and cellular tissue over the sac, or, as is frequently the case, it is a sequela of one of the exanthemata (pp. 178, 179).

Besides the affection of the conjunctiva already mentioned, the disease of the lacrymal passages may be complicated with a similar state of the mucous membrane of the nose.

In warm dry weather all the symptoms are much relieved or disappear altogether; but in cold and wet weather they become aggravated.

This disease is usually connected with a faulty state of health. It most frequently occurs in scrofulous constitutions.

In cases of chronic inflammation of the derivative lacrymal passages, an acute attack with abscess may supervene from exposure to cold, &c. If not timely opened, great pain is suffered while the distension of the sac goes on increasing: at length it bursts, and the severity of the symptoms is relieved.

Should the opening in the sac, whether made by the knife, or produced by the spontaneous bursting of the abscess, again close without the passages being first restored to a healthy state, the same process of acute inflammation and abscess may take place over again from any new exposure.

In some cases, repeated attacks of this kind will be found con-

nected with caries of the surrounding bones, especially the lacrymal and inferior spongy.

General treatment.—As the digestive organs are very commonly disordered, particular attention must be directed to them, if this has not been already done, irrespective of the local disease. A mild nourishing diet, a course of some gentle mercurial, such as hydrargyrum cum creta and laxatives, followed by disulphate of quinine or other tonic, will be found beneficial in many cases. Iodide of potassium is a remedy under the use of which alone cures have been effected. As the skin is often in an unhealthy state, attention should be directed to it. Daily friction of it should always be practised.

Local treatment.—Counter-irritation behind the ears is to be used, premised, if need be, by the application of leeches over the sac, and to the entrance of the nostrils. [It is safer, and more agreeable, and equally useful, to draw blood from the temples.] Besides these, the eye should be bathed three times a day with some eyewater (such as that of hydr. bichlorid. (p. 69), and weak red precipitate ointment (p. 72)), applied to the edges of the eyelids at bedtime. These remedies act by subduing the attendant conjunctivitis, and if care be taken to keep the lacus lacrymalis filled for some minutes with the eyewater each time it is used, the sac having been previously emptied by pressure, some of it will be absorbed by the puncta and conveyed along the canaliculi into the sac, and will be thus brought into direct contact with the mucous membrane, which is the seat of the disease, and will act on it as beneficially as on the conjunctiva. There is scarcely ever any occasion to use Anel's syringe for the purpose. Friction with mercurial ointment over the sac and side of the nose is useful. [Ointment of the iodide of lead, Goulard's cerate and ointment of the carbonate of lead (ʒij to the ounce of lard), have been severally extolled. Tincture of iodine is resorted to as a local irritant in some cases, and Dixon recommends the application of a small blister over the tumor as one of the most effectual remedies with him.]

If the above treatment prove unavailing in removing the chronic inflammation and restoring the free passage of the tears to the nose, the propriety of operative interference for the purpose of opening the sac and introducing a style into the nasal duct will come to be considered.

Atony or relaxation of the lacrymal sac.[1]

In some cases of chronic inflammation of the derivative lacrymal passages, the sac becomes much dilated and relaxed, its wall

[1] Hernia of the lacrymal sac.

being at the same time thickened, so that the tears and mucus accumulate in it in very considerable quantity, even although the nasal duct be not obstructed. The swelling at the inner corner of the eye, produced by this state of the sac, is soft and without pain; and the skin is in general not at all discolored.

By pressure on the sac, the accumulated tears and mucus may be expelled both through the puncta into the eye, and through the nasal duct into the nose. By holding the face down while the pressure is made on the sac, a considerable quantity of fluid will sometimes drop from the nose.

Treatment.—The first object in the treatment is to improve the state of the mucous membrane of the derivative lacrymal passages, and this is to be attempted by the use of astringent lotions dropped into the lacus lacrymalis to be absorbed or injected at once into the passages through the puncta by means of Anel's syringe.

Frequent and continued pressure over the sac is of great use. The patient, if properly instructed, may effect this himself with his finger, in a manner superior to what can be done by any of the *compressoria* which have been invented for the purpose.

Should the state of the mucous membrane not be improved by the treatment, and should, on the contrary, the nasal duct come to give passage to the tears less readily, then it will be proper to consider the propriety of opening the sac by incision, in order to operate directly on the nasal duct, in the manner to be treated of below.

Mucocele.[1]

Mucocele is a swelling of variable size, sometimes livid, generally elastic, in the situation of the lacrymal sac, not at first, though it may come at last to be very painful to the touch.

When pressure is applied, there is no escape of any matter, either by the puncta or by the nasal duct.

This disease appears to depend on the slow accumulation and inspissation of the mucous secretion of the sac itself.

A mucocele may exist for a long time—for years—without discoloration of the skin, without pain, elastic, and with an indistinct fluctuation, but may become enlarged, hard, livid, and painful, from an attack of inflammation in the part.

The contents of the distended sac are fluid in the earlier stage, but of a gluey consistence from inspissation in one more advanced.

Treatment.—The treatment consists in first laying open the tumor with a knife, evacuating the contents of the sac, and then injecting tepid water to clear it out completely. If the contents are consis-

[1] Dropsy of the lacrymal sac.

tent and gluey, it will be necessary to scoop out the mass before injecting the water.

The sac having been cleared out, the next business is to examine the state of the canaliculi and nasal duct, and to treat them in the manner to be described below.

Exostosis of the inner and posterior wall of the lacrymal fossa.

This gives rise to a projection in the region of the lacrymal sac, resembling the swelling of a mucocele.

Fistula of the lacrymal sac.

After the evacuation of an abscess of the lacrymal sac by bursting or incision, if the lining membrane still continue unhealthy, and the nasal duct obstructed, the opening into the sac, though it contracts, may not entirely close, but remain in a fistulous state with callous edges.

The fistulous opening in the skin may correspond with that of the sac, or the communication between the two openings may be through a sinus. There may be more than one opening in the skin with a corresponding number of sinuses.

Sinuses of this description are to be distinguished from sinuses in the same situation not communicating with the sac (p. 427). Sinuses thus arising, we have seen, however, sometimes penetrate inwards by ulceration of the wall of the sac.

True fistula of the lacrymal sac is to be closed only after restoration of the passages to a healthy state, if that is possible; if not, the palliative treatment described below must be had recourse to.

Atony or relaxation of the papillæ with a dilated state of the puncta.

The puncta may be found dilated, with the papillæ relaxed, and not properly directed towards the lacus lacrymalis. This state is usually found connected with some chronic inflammation of the conjunctiva of the blennorrhœal kind. There may also be present defective action of the tensor tarsi muscle and of the orbicularis.

Treatment.—The application to the parts of the drops of the nitrate of silver, or of the lapis divinus with vinum opii (p. 70).

Shrunk papillæ and contracted state of the puncta.

When the lacrymal puncta are contracted, the first object should be to endeavor to dilate them, and for this purpose a common pin, of a proper thickness, rendered blunt and smooth at the point by rubbing on a whetstone is a very good instrument.

Lower punctum.—The patient being seated before a window, the surgeon holds the edge of the lower eyelid, towards the inner angle, a little depressed and everted, with one hand, so as to bring into view the punctum, while with the other he introduces the point of the pin, with a rotary movement between his thumb and forefinger, into the lower punctum downwards in the direction of the vertical portion of the corresponding canaliculi into which he passes it a little way. [Upturning of the eye facilitates the exposure of the punctum. See Dr. Hays' directions in Lawrence, p. 921, 1854.]

Upper punctum.—The operation on the upper punctum is the counterpart of this, but not quite so simple. The upper eyelid towards the inner angle being held raised and everted, so as to expose the punctum, the blunt-pointed pin is introduced into it, and pushed with a rotatory movement upwards in the direction of the axis of the vertical portion of the corresponding canaliculi.

The operation is to be repeated with thicker and thicker pins if necessary, until the puncta are sufficiently dilated to admit easily a moderately-sized Anelian probe for the exploration of the canaliculi.

Obliteration or obstruction of the lacrymal puncta or canaliculi.[1]

Exploration of the canaliculi.—The instrument employed is a slender gold probe, commonly called Anel's probe. The first steps in the operation are the same as in that of the introduction of the blunt-pointed pin into the puncta just described.

Lower canalicule.—Having entered the probe, held lightly between the thumb and forefinger, into the punctum, and pushed it downwards to the dilated bottom of the vertical part of the canalicule, that is, to the depth of about one-tenth of an inch, withdraw it a little and change the vertical direction of the probe downwards for a horizontal one inwards, or rather for one deviating from the horizontal inwards, so as to be slightly oblique from below upwards, which is the direction of the second part of the canalicule. At the same time that the direction of the probe is thus altered, the inner part of the lower eyelid is to be stretched, by the finger holding it, towards the temple, and pressed slightly more downwards, in order as much as possible to undo the curvature of the canalicule.

Upper canalicule.—Having pushed the probe upwards to the dilated bottom of the vertical portion of the canalicule, and then withdrawn it a little as above directed for the lower canalicule, the change of the vertical direction of the probe upwards is to be made for one deviating so far only from the horizontal inwards, as to be slightly oblique from above downwards. At the same time that this is being done, the inner part of the upper eyelid is

[1] Atresia punctorum lacrymalium.

to be stretched towards the temple, and somewhat more upwards, with the same view as that for which the analogous proceeding in the case of operation on the lower canalicule is directed.

The manœuvre just described being performed, whether in the case of the lower or upper canalicule,—and it is the work of a second or two only—the probe is pushed on towards the lacrymal sac.

If there be actual obliteration of the canalicule in some parts of its course, the probe will be arrested in its progress towards the lacrymal sac. But it must not be too hastily inferred that obliteration exists, when the probe is so arrested. Often by delicate manipulation and rotation of the instrument, it is at last made to pass on into the sac, showing that, though there is stricture or obstruction from tumefaction from the lining membrane, there is no obliteration.

Obliteration, when it exists, is generally the result of a wound or burn, which has implicated the canalicule, and of which the scar may be still observable. If one canalicule only be obliterated, the tears may continue to pass without interruption by the other; hence, no surgical interference will be required. Obliteration of both canalicules gives rise to stillicidium lacrymarum.

Obstruction of the canaliculs from inflammatory tumefaction may exist independently of a similar affection of the derivative lacrymal passages in general, though most frequently it is a part merely of a general affection of those passages. But, on the other hand, it is to be remarked that the canalicules may be, and very frequently are, little or not at all affected when the lacrymal sac and nasal duct are much affected.

This is shown by what is ordinarily the case in chronic inflammation of the passages, viz., that the tears are taken up and conveyed into the sac, and not having a passage to the nose on account of the obstruction of the nasal duct, accumulate there, and, intermixed with streaks of puriform mucus, may be readily regurgitated through the puncta, by pressing on the sac (p. 430).

Although, in obstruction of the canalicules from tumefaction of the mucous membrane, a probe might be made to pass, the swollen membrane would, when the probe was withdrawn, again fill up the canal. In such a case, therefore, the introduction of a probe would be useless, if not positively hurtful. The obstruction is to be overcome only by removing the inflammatory and thickened state of the membrane on which it depends.

Treatment when both canalicules are obliterated.—Between the place of obliteration and the sac, the canalicule is to be opened from within, by removing, along with a fold of the conjunctiva, as it is passing into the skin, a portion of its inner wall with the curved scissors, and an attempt made to maintain the opening next the sac patent, by keeping a probe more or less constantly in it during cicatrization.

Jungken[1] appears to have succeeded by such an operation as this, in curing a young man in whom a burn of the inner corner of the eye with a hot iron, by which he was struck, had occasioned obliteration of the canaliculi, with adhesions between the internal commissure of the eyelids, the lacrymal caruncle, and the semilunar fold.

Velpeau mentions that he has seen in two persons who had the canalicules accidentally cut during some other operation, that the tears were taken up by the accidental opening, so that no inconvenience resulted.

If the operation has not succeeded, or if it cannot be performed on account of proximity of the obliteration to the sac, it has been proposed to make an opening into the sac from within the lower eyelid through the conjunctiva, and endeavor by catgut bougies, to keep it permanently open.

The lower eyelid being held everted, the sac is opened by thrusting the knife into it from the groove between the caruncle and lower eyelid.

If this also is unsuccessful, the case, as far as regards the transmission of the tears to the nose, is incurable.

Exploration of the nasal duct to determine whether it is obstructed or obliterated.

In obstruction to the transmission of the tears from the eye into the nose, attending any of the affections of the derivative lacrymal passages above described, if we have satisfied ourselves that the puncta and canaliculi are not in fault, we naturally direct our attention to the nasal duct.

The nasal duct is much more frequently obstructed or wholly impervious than any other part of the derivative lacrymal passages. This, as above mentioned (p. 430), appears to depend, in a great measure, on the circumstance, that when its lining mucous membrane is tumefied or thickened, the space necessarily required for the increase of bulk is taken at the expense of the calibre of the duct itself, no distension outwards being permitted by its bony walls. Lymph being thrown out in this state, either within or without, permanent obliteration results.

Exploration of the nasal duct may be made in three different ways, viz. :—1. By an Anelian probe introduced through the upper punctum [or lower punctum] and canalicule into the sac, and thence down into the nasal duct. 2. By the introduction of a probe, properly curved for the purpose, from the nose. 3. By the introduction of a probe through an opening into the sac, either already existing,

[1] Motherly, Diss. de atresia punctorum lacrymalium. Berolini, 1834.

or made for the purpose, below the tendon of the orbicularis palpebrarum.

Exploration of the nasal duct by an Anelian probe introduced through the upper punctum and canalicule into the sac, and thence down the nasal duct.—Having, in the manner above described (p. 434), passed the probe through the upper punctum along the canalicule as far as the sac, it is to be raised to a direction deviating from the vertical only by the point of the instrument being inclined backwards and slightly outwards, which is the direction of the nasal duct. By now pushing the probe down with a rotatory movement between the fingers, it will, if the duct be not closed or very much obstructed by fungous granulations, come to strike in the floor of the nostril. [We agree with Dr. Hays in preferring the *lower* punctum. Op. cit. p. 921.]

In regard to the direction just given to incline the point of the probe backwards and slightly outwards, it is to be observed, that the backward inclination of the point will generally without any care on the part of the surgeon be determined by the prominence of the eyebrow.

Exploration of the nasal duct by the introduction of a probe from the nose.—Gensoul's sound, the instrument for the performance of the operation, is a probe bent, but not abruptly, at nearly a right angle, at the distance of about nine-tenths of an inch from the point. Close to this bend there is in the handle part of the probe a slight lateral one, to the right or left according to the nostril operated on, in order that the instrument may be accommodated to the projection of the nasal process of the superior maxillary bone.

It is to be remembered that the lower orifice of the nasal duct is in the anterior and upper part of the lowest meatus, at the lateral wall of the nasal cavity, and about one inch from the entrance of the nostril; that it is overhung by the lower spongy bone, and that it is of the form of an oblique fissure looking downwards and inwards.

The instrument is introduced into the nostril with its point and first concavity directed downwards and outwards. In this position the point is run along the floor of the nostril as far as the first bend. It is then to be elevated and grazed along the outer wall of the nostril towards the orifice of the duct; in executing this manœuvre, the handle of the instrument is with great delicacy to be carried from its original direction, outwards and somewhat downwards, to a horizontal direction, forwards, and this by slightly rotating the handle of the instrument between the fingers, and executing a curved sweep from below upwards. If there is no obstruction, the instrument is thus made to slip into the duct, and its end may be felt by applying the finger over the sac.

Exploration of the nasal duct by the introduction of a probe through an opening into the sac.—An opening into the lacrymal sac is made by incision of its anterior and outer wall, below the tendon of the orbicularis palpebrarum.

Fig. 89.



Instrument.—Perhaps the best instrument for the purpose is a small scalpel, with its back bevelled on either side, and running into a sharp edge at the point for the extent of about one-fifth of an inch. (Fig. 89.)

Incision of the sac.—Preparatory to the operation, the sac is to be allowed to become distended with fluid. The patient being seated opposite a window, the assistant, who stands behind holding the head, is to press the skin at the outer angle of the eye towards the temple, in order to stretch the skin over the sac, and thus to bring prominently into view the tendon of the orbicularis palpebrarum to serve as a guide. (Fig. 90.)

The surgeon having touched and felt the part over the sac with his finger, takes the knife between his thumb and fore and middle finger, and proceeds to the penetration of the sac. The point of the knife is directed perpendicularly to the surface of the skin, *i. e.* backwards and inwards, over the wall of the sac below the tendon of the orbicularis, its edge being directed outwards and somewhat downwards. The knife in this position having been made to penetrate the sac, which is known by the escape of fluid and cessation of resistance, its handle is to be raised, and then the point pushed down a little way within the sac in the direction of the nasal duct. By the increasing breadth of the knife, a sufficiently large opening is made obliquely across the sac parallel to the margin of the orbit, but in withdrawing the knife, the external incision may be enlarged a little outwards and downwards.

Introduction of the probe.—Direct the point of the probe (a whalebone one is the best), held nearly horizontally backwards and inwards through the opening in the sac until it strikes upon its opposite wall. Then withdrawing the probe slightly, direct its point downwards to the nasal duct, remembering that its direction is downwards, backwards, and outwards, and also slightly curved, the convexity being forwards. If the probe does

not readily pass, it should not be forced down, but by moving about the point and rotating the instrument between the fingers and thumb, at the same time that pressure downwards is gently made,

Fig. 90.

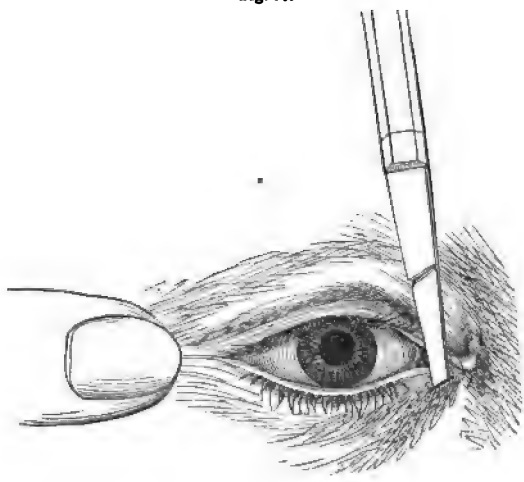

it will probably at last pass. If not, a tent is to be left in the opening into the sac, and the trial repeated next day. A whalebone probe is to be employed in the first instance, a silver one in the second.

Procedure when a fistulous opening already exists in the sac.—If a fistulous opening leading directly into the sac already exists, and if of sufficient size, the probe may be at once introduced through it into the nasal duct. Or if very small, it may be dilated by a succession of thicker probes.

If the opening in the skin does not correspond with that in the sac, a small director should be introduced through the former into the sinus. This being laid open to its bottom, the director is introduced into the opening in the sac, for the purpose of enlarging it by incision, as just directed.

Appreciation of the three different ways above described of exploring the nasal duct.—All that can be ascertained by means of Anel's probes introduced through the puncta, canalicules, and sac, into the nasal duct, is that this canal is or is not permeable to a probe necessarily very much smaller than its own diameter. But in consequence of the winding form of the canal along which the small probe is passed, there cannot be, except in very practised

hands, much certainty whether an impediment which the probe may encounter be owing really to an obstruction in the nasal duct, or merely to the circumstance, that the small point of the probe has been caught in a fold of the lining membrane. Again, though the probe pass, there may, nevertheless, be obstruction sufficient effectually to prevent the passage of the tears into the nose. For these reasons, and for the violence done to the punctum and canalicule, this mode of exploration is not to be recommended.

As little is the operation to be recommended as a means of removing the obstruction. Such a small probe must be totally inefficient as a means of dilatation, or as a means of removing any obstruction that would continue to oppose the passage of the tears. And the few cases in which it is alleged benefit was obtained from the practice, were of a slight nature, and most likely would have been benefited without recourse to any such measure. [See the last edition of Lawrence, for a much more encouraging, and practical account of the use of the probes, by Dr. Hays (p. 919, et seq.), in which he strongly recommends them for removing obstructions, and for gradual dilatation, as well as for exploration, and describes the best mode of employing them.]

In regard to the exploration of the nasal duct by the introduction of a probe from the nose, it is to be observed that the lower orifice of the duct is not always readily hit upon by the point of the probe. It is, therefore, in most hands an uncertain mode of exploration, and not well adapted as a means of removing obstruction of such a nature as that which affects the nasal duct. Besides, the introduction of the instrument is very painful.

According to the concurrent testimony of practical men, the best plan, as well for the exploration of the nasal duct as for the application of means calculated to remove or palliate obstruction of it, is to operate through an opening made into the sac from without, as first suggested by Petit.

When in the exploration of the nasal duct above described, the whalebone probe can be pushed down into the nose without any marked opposition, the surgeon merely feeling as if the probe were closely grasped by the walls of the passage, it may be inferred that the obstruction to the passage of the tears is owing to a general tumefaction or a somewhat fungous state of the lining membrane.

When considerable manipulation and rotation require to be made before the probe passes, or when it is only after repeated attempts on successive days that the probe is made to pass at all, thickening of the mucous membrane with fungosities and granular growths must exist to a very considerable degree.

When the probe cannot be made to pass at all into the nose, ob-

literation of the duct is of course to be inferred. The place of obliteration will be ascertained by the extent to which the probe can be made to pass.

It is to be remembered that in some cases complete obliteration of the lacrymal sac or nasal duct has been found to depend on exostosis of the surrounding bone. The lacrymal sac, on being opened has been found filled up with a polypus, which was the cause of the tumor. In this case, which is related by Walther, on the removal of the polypus the nasal duct was on exploration found obstructed, but was rendered permeable by the treatment.

Obstruction of the nasal duct and the different operative methods adopted with a view to remove it and to restore a passage to the tears.

The introduction of catguts and styles, are the means by which dilatation of the nasal duct is attempted.

The catgut as a means of dilating the nasal duct.—An opening into the sac to operate from, is to be made, if not already existing, and a piece of catgut provided, of proper thickness and sufficient length—say one and a half inch—having one end rounded and slightly softened, by being moistened, and bent abruptly at about a quarter of an inch from the other end (Fig. 91). By the rounded and softened end the catgut is introduced in the same way as a style or probe, through the opening of the sac into the duct, and pushed down in it to the nostril. The bent end is left sticking out from the opening in the sac, and by a thread attached to it and fixed to the side of the nose by court plaster, is secured from slipping in through the opening into the sac.

The catgut is much less convenient than the style, and it is to be recommended only when it is desired to exert gradually increasing pressure on the walls of the duct from within. When introduced dry, and of a thickness readily admitted by the duct, the catgut gradually swells by absorbing moisture, and produces the pressure. If the catgut, when dry, is so thick as to be admitted by the duct, and no more, the pressure from within which ensues, on the distension of the catgut by moisture, may be so great as to cause very considerable pain. This will be avoided by so regulating the thickness of the dry catgut to the width of the duct that the former shall be readily admitted by the latter.

The catgut is to be removed every day or two and a new bit introduced, and of greater thickness, if necessary. When withdrawn, the swollen catgut presents a more or less distinct cast of the nasal duct, and from it something may be learned as to the seat and form of any stricture or fungosity which may exist. It is to be remem-

bered, that it will always be constricted at the places which correspond to where the sac joins the duct, and where the latter opens into the nose.

Fig. 91. Fig. 92. Fig. 93.



The style as a means of dilating the nasal duct.—The form and size of the style are well known (Fig. 92). It is usually made of lead or silver. One may be easily made for an occasion, by taking a bit of lead wire of the proper length and thickness, smoothing its surface, rounding one end, and bending the other, thus:—(Fig. 93.)

A thinner style is to be followed by a succession of thicker ones, until one of a moderate thickness can be borne; or the duct may be first prepared for the reception of a moderately thick style by the previous use of catguts, as above described.

The patient soon learns to manage the metallic style himself—a great advantage, considering the length of time the employment of means for dilating the nasal duct requires to be persisted in.

Whatever be the means employed for dilating the nasal duct—catgut or metallic style—the passage is to be cleansed on every re-application by injections of tepid water. After which some stringent lotion is to be thrown in, or the dilating body may be employed as the vehicle of some medicament, in the form of salve, with which, when about to be introduced, it is to be smeared. The bichloride of mercury collyrium, and the red precipitate ointment, are perhaps the best applications, in general, that can be made to the diseased mucous membrane of the duct. The nitrate of silver, in the form of solution or ointment, will be found advantageous when used occasionally.

When by the above described mode of treatment, which must be persevered in for at least three months in any case, but often for a much longer time, the nasal duct is dilated to its natural width, and it is believed that its lining mucous membrane is restored to some-

thing like a healthy state, the use of the dilating bodies is to be discontinued. If the transmission of the tears into the nose should now go on naturally, the opening in the sac is to be left to close; for this purpose the edges are to be touched with caustic, and when rendered raw by the separation of the eschar, closure will generally take place, provided the tears pass freely.

If the tears do not continue to be freely transmitted, the treatment will require to be resumed, and if it is found, after several trials, that the employment of the style, &c., cannot be abandoned without recurrence of the obstruction, then the patient must make up his mind to wear the style habitually in the nasal duct, or to have a gold tube inserted into it. The latter plan admits of the opening into the sac being closed, but possesses no other advantage over the style,—in fact, is in all other respects less advantageous. The inconvenience and deformity attending the habitual use of the style are small in comparison with the great benefit obtained from it.

Although the style may occupy the whole calibre of the duct when first inserted, a sufficient space is always left between it and the wall of the duct, as the mucous membrane does not tend to grasp the style as the gum grasps a tooth, but rather tends to widen around it. This shows that it is unnecessary to have the style grooved to serve as a channel for the tears, as some have recommended.

Insertion of a gold tube into the nasal duct and lower part of the sac.—As it is with the intention of its being left permanently in the nasal duct that the tube is introduced, the opening into the sac is closed over it.

Fig. 94. Fig. 95.

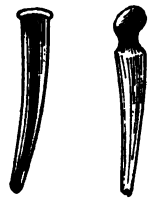

Tube.—The tube which has been principally used of late years, since Dupuytren revived the practice of Foubert and Wathen, is of the form and size represented in the annexed cut (Fig. 94). The tube originally used by Wathen is here represented (Fig. 95); and from its appearance it may readily be understood that it would require much force to fix it properly in its place; the projection below the cup or head being of greater diameter than the duct itself; and how that in pressing the intrument into its place, the force employed breaks the os unguis.

Dupuytren's tube is certainly the best. It is about an inch or so long; at one end, one-sixth of an inch wide, and provided with a rim, intended to be caught by the contraction between the sac and duct; at the other end, about one-twelfth of an inch wide, and cut obliquely. For the purpose of being introduced, it is slid on the styliform part (*a*, Fig. 96, p. 444) of the conductor or handle

here represented, which fits into it so loosely, that when the tube is fixed in the duct, the conductor or handle may be withdrawn without bringing the tube along with it. The curvature of the styliform part of the conductor necessarily determines the proper direction of the tube as regards its curvature when inserted into the duct.

Mode of introducing the tube.—Having enlarged the opening in the sac by incision, the tube, mounted on its conductor, is to be

Fig. 96.

passed into the sac, and thence slid down into the duct, its wide end remaining in the lower part of the sac, and the concavity of its curvature directed backwards. The tube is thick in proportion to the duct, as in order to be retained in its place it requires to be wedged in, and for this some force is necessary. The tube being thus fixed, the conducting handle is withdrawn from within it. The edges of the incision into the sac are then brought together by a bit of plaster.

The tears are immediately freely transmitted into the nose, and in a day or two the opening into the sac will have closed, even where there had previously been a fistulous opening. In general no further inconvenience is felt; no deformity is seen, and so the patient is dismissed cured, and may continue in the belief that he is so for years.

Thus does the insertion of a tube into the nasal duct appear a speedy and elegant mode of effecting a cure, without deformity, or the inconveniences attending obstruction of the nasal duct. But it has often happened that, sooner or later, the tube has been pressed up out of its place, caused irritation, or so much aggravated irritation, excited by other causes, that its extraction became necessary; or the bony structures around the duct having become carious, the

tube has dropt out by the nose. A silver tube, it is to be observed, is liable, in the course of time, to be so acted on by the secretions passing along it, that it becomes decomposed and brittle, and falls out of the nose in black fragments.

As a provision for the removal of the tube in case of necessity, the rim at the wide end should form a slight ledge towards the interior as it does towards the exterior, in order that it may be caught by a hook and drawn out through an opening into the sac made for the purpose. In the absence of any such provision, the extraction may in general be made by means of a dissecting forceps.

Obliteration of the nasal duct.

When on exploration it is found that the nasal duct is quite closed, but to a small extent only, a cautious attempt may be made to perforate the obliterated part by means of a stylet introduced through the opening in the sac down to the place of obliteration. If perforation be successfully effected, a style is to be inserted into the duct as above directed.

If the obliteration be to any extent, which is rare, there is not much chance of successfully perforating it; the only thing that could now be had recourse to, is the old operation of perforating the os unguis, and trying to establish a communication between the sac and middle meatus of the nose, were it not that success seldom or never crowns the attempt.

Perhaps the best palliative measure that can be adopted is to make an opening into the sac above or below the tendon and maintain it permanently. Through this opening the tears and matter accumulated in the sac may be occasionally pressed out, and thus the irritation to the eye avoided which would result from regurgitating them by the puncta.

It was the practice of the older surgeons, who did not understand the anatomy, physiology, and pathology of the lacrymal organs, to attempt the obliteration of the whole lacrymal passages, on the principal of striking at the root of the disease by removing its seat.

Lacrymal calculi.[1]

Calculous concretions deposited from the tears have been met with, in some cases, lodged in the sinuses of the oculo-palpebral space of the conjunctiva, in other cases in the derivative lacrymal passages.

[1] Dacryolites.

CHAPTER X.

DISEASES OF THE ORBIT.

SECTION I.—INFLAMMATIONS, ETC., OF THE ORBIT

Inflammations of the orbital cellular tissue.

THIS inflammation occurs in an acute or chronic form.

In the *acute* form, the *symptoms, objective, subjective,* and *constitutional,* are very much the same as those of phlegmonous panophthalmitis above described (p. 175, et seq.), but the eyeball is more protruded from the orbit, in consequence of the greater exudation into the orbital cellular tissue, and either presents no evidence of inflammation of its proper tunics, or comparatively slight ones.

In the *chronic* form, protrusion of the eyeball may have been preceded by no other symptom, or at the most, by inconsiderable and partial pain in the orbit, during motion of the eyeball.

Inflammation of the orbital cellular tissue has a great tendency to run into suppuration. This, however, does not always take place; the inflammatory action may subside, the exuded matter be absorbed, and the eyeball return to its place; or the cellular tissue may be left in a state of induration, the eyeball, perhaps, become amaurotic from pressure, continuing protruded and motionless.

In the *acute* form, when suppuration takes place, the subjective symptoms are also much the same as in the suppurative stage of panophthalmitis, but, as may be inferred from the difference in the seat of the matter, the objective differ. The eyeball is still more protruded, but perhaps not otherwise much changed in appearance. The matter having made its way forwards, points of fluctuation present themselves either behind the conjunctiva, or behind the skin of the eyelids, or in both situations at the same time.

In the *chronic* form, that suppuration has taken place may be inferred, if the patient has experienced shiverings, &c., though suppuration may not be ushered in by any marked symptoms. As matter accumulates, the protrusion of the eyeball increases; the eyelids, red and œdematous, are distended over it, and besides diminishing vision with photopsy and diplopy, the patient complains of a feeling of traction in the orbit. At length, more or less obscure fluctuation is felt at some point between the eyeball and margin of the orbit.

Causes.—Inflammation of the cellular tisue of the orbit, which is a rare disease, is sometimes of traumatic origin. More fre-

quently it appears to arise from cold in persons laboring under a bad state of health or constitution. In erysipelas of the eyelids, the inflammation is apt to spread to the cellular tissue of the orbit, and terminate either in induration or in diffuse abscess. In many cases the inflammation occurs without any very evident cause.

Prognosis.—Whether the inflammation proceed to suppuration or not, recovery with preservation of vision may take place, but on the other hand, it sometimes happens that amaurosis is occasioned by the pressure to which the eyeball has been subjected. In the acute form there is additional risk of injury to the eye from implication of its proper tunics in the inflammation, but a still more formidable event is the extension of the inflammation to the brain or its membranes, which may prove fatal.

Treatment.—The same active antiphlogistic treatment above indicated for phlegmonous panophthalmitis (p. 176) in its first stage, is called for in the acute form of inflammation in the orbital cellular tissue.

In the chronic form the alterative plan of treatment is indicated.

In the second stage of the inflammation, when abscess has formed, the matter is to be evacuated by incision at the point of fluctuation.

If, as may happen in the chronic form, there is no fluctuation, but from the protrusion of the eye, and other symptoms, there is reason to fear that accumulation of matter in the cellular tissue of the orbit exists, an incision should be cautiously made into the orbit through the skin, between the margin of the orbit and the eyeball, in the situation where it appears most likely matter is collected. It may be necessary to extend the incision to a considerable depth—as much as an inch—before the matter is reached.

After the abscess has been opened, matter may continue to be discharged for a considerable time, though there be no disease of the bone.

The following case, of which the celebrated Austrian general, Marshal Radetzky, was the subject, is a good illustration of chronic inflammation and abscess in the orbit, and is at the same time interesting, inasmuch as the disease was given out as a fungoid tumor of the orbit cured by homœopathic treatment.

Oct. 9, 1840.—After great fatigue on this day, the marshal, then about sixty-nine years old, was suddenly seized with violent fever, accompanied by severe pain in the forehead and temples. Inflammation of the right eye and surrounding soft parts at the same time manifested itself, with considerable protrusion of the eyeball. The pains were very severe, but in the course of the night

they diminished, so that the next day after the patient was able to attend a military parade.

Although the inflammation of the eye, the fever, and the pains disappeared, there continued redness of the eyelids and a swollen state of the conjunctiva, whilst a tumor, appreciable by the sight and touch, appeared at the outer angle, and caused the eyeball to protrude.

In the course of the following three months, during which time the patient was treated homœopathically,[1] the eyeball became more and more protruded, with recurrence of the congestion and pain from time to time.

The above is an abstract of the account given of the case by Marshal Radetzsky's ordinary medical attendant, a homœopathist, to Professor Jaeger of Vienna, who subsequently saw the patient at Milan along with Professor Flarer, in consultation with the marshal's homœopathic physician.

Professor Jaeger found the right eye healthy in all its parts, completely pushed out of its socket by a tumor. Touched through the eyelids, this tumor was felt to be as hard as stone and irregular. Pressure on it caused pain. The eyelids stretched on this tumor were swollen and immovable, pervaded by varicose vessels and of a dark blue color, as also the neighboring parts of the face. The conjunctiva was of a dull red, being also pervaded by varicose vessels, and secreted a sanious puro-mucus. The lacrymal gland was displaced. The lacrymal caruncle and sac were prodigiously swollen, hard and painful to the touch.

The general health of the patient was good.

The conclusion agreed to at the consultation as to the nature of the malady was, that it consisted of a *scirrhous degeneration* of the soft parts of the orbit, threatening to pass into cancer.

Professor Jaeger, however, expressed himself strongly inclined to consider the case rather one of *periorbitis rheumatica;* and thought that inflammation of the tumor would probably soon increase with aggravation of the pain, that suppuration would supervene, and terminate in recovery.

This was in fact what did take place, but the homœopathic physician maintained that the disease was a fungoid tumor which he had cured by his infinitesimal doses.

The marshal would not submit to any other but homœopathic treatment.

[1] "The remedies administered were in the following order:—
"1. Aconit.; 2. Baryt. carbon.; 3. Zincum metall.; 4. Anacardium orient.; 5. Calc. carbon; 6. Euphrasia; 7. Mercurius Hahnemannii; 8. Merc. sublim. corros.; 9. Antimon. crud.; 10. Digitalis. All administered in the highest degree of dilution according to homœopathic principles, and with the greatest precaution, in consequence of the great irritability of the patient."

Inflammation of the periorbita and bones of the orbit.

This inflammation sometimes occurs in an acute form, but more frequently in a chronic, and may present itself as a primary affection, or as a consequence of inflammation of the orbital cellular tissue.

The symptoms are in general similar to those of inflammation of the orbital cellular tissue, but vary somewhat according to the part of the orbit affected, which may be the exterior margin, just within the cavity, the lacrymal fossa, the middle part of one of the walls, or the apex, and suppuration is equally prone to take place. The inflammation may, however, terminate in resolution, or, in the chronic form especially, its event may be thickening of the periorbita and bones.

When suppuration takes place, and the abscess has been opened, either by spontaneous bursting or the knife, the opening does not close, but becomes fistulous, and surrounded by fungous granulations, and on examination with the probe, the bone is felt to be in a state of caries or necrosis.

Causes.—The inflammation may be traumatic, but generally it is owing to a scrofulous or syphilitic taint of the constitution, or both at the same time.

Prognosis.—When the bones of the orbit have become diseased, exfoliation may after a time take place, and allow of the external opening closing, but the skin, already, perhaps, drawn in towards it, becomes still more so, and the eyelid retracted and incapable of being drawn over the eye (*lagophthalmos*, p. 402), or both retracted and everted (*ectropium*, p. 392).

Treatment.—The treatment of the acute and chronic forms of inflammation of the periorbita, and of the bones of the orbit, should be the same as that recommended respectively for the acute and chronic forms of inflammation of the orbital cellular tissue, in the purely inflammatory stage, and in the stage of abscess.

In the stage of fistula, the indication is to promote exfoliation of the bone, according to general surgical principles, and this being effected, the next point is to prevent distortion of the eyelids, or, if this has already taken place, to remove it by some one of the operative procedures described under the heads of *ectropium* and *lagophthalmos*.

Section II.—Orbital Growths and Tumors.

The symptoms and effects of orbital growths and tumors, are:—1. Protrusion of the eyeball in various degrees (*exophthalmus*). 2.

Misdirection and displacement. 3. Impaired mobility to a greater or less extent. 4. Sometimes little or no pain, but a feeling merely of fulness, tension, and traction. Sometimes, however, more or less pain. 5. Besides diplopy, as the necessary effect of misdirection of the eyeball, impairment of vision, with photopsy, even to amaurosis, from the pressure. 6. Œdema of the eyelids, with more or less distension of the upper and eversion of the lower. 7. Sometimes eventual inflammation and disorganization of the eyeball (*exophthalmia*). 8. Dilatation of the orbital cavity, and destruction of its walls, and consequent fatal pressure on the brain, the eyeball, perhaps, continuing to resist the pressure.

Orbital growths and tumors may have their seat in the walls of the orbit or in its cavity. The growths and tumors seated in the walls of the orbit, are *node*, or *periostosis*, thickening of the bone, or *hyperostosis*, bony tumor, or *exostosis*, and cancer, or *osteosarcoma*. Those which occur in the cavity of the orbit are:—sarcomatous, encysted, hydatidgenous, medullary, melanotic, and aneurismal.

Both walls and cavity of the orbit may be encroached on by tumors having their origin in adjoining cavities—the nostril, frontal sinus, maxillary sinus, sphenoid sinus, cavity of the cranium.

The tumors which it is intended to consider here, are those only which form in the cavity of the orbit.

Causes.—The causes of orbital tumors, in general, are obscure. In many cases they appear to have formed after blows, &c., on the margin of the orbit, but often they cannot be attributed to any cause.

Treatment.—The diagnosis of orbital tumors is often very obscure. Under such circumstances, the alterative mode of treatment is the only one indicated. When the tumor has become so far developed that its nature can be ascertained, what further treatment may be called for will admit of being determined.

Infiltration of the orbital cellular tissue.

Simple exophthalmus or prominent eye occurs, depending apparently on some infiltration of the orbital cellular tissue. Such cases I have met with in leucophlegmatic anæmic young women, who were affected at the same time with goitre. In one case both the exophthalmus and goitre appeared after an injury to the middle finger of the right hand—the exophthalmus in a week and the goitre in three months. There was puffiness of the skin all around the eyes. The sight continued perfectly good for both near and distant objects.

Any connection between the injury and the exophthalmus and goitre in this case was not very evident.

Other cases of prominent eye with anæmia and goitre have been of late years recorded.

Treatment.—Iron has been found useful in such cases.

Locally, the spirituous solution of iodine (p. 79) is to be painted over the puffy skin around the eye, and also over the goitre.

Sarcomatous tumors in the orbit.

When, in the case of a sarcomatous tumor, swelling presents externally, it is felt to the touch solid and resisting.

Sarcomatous tumors grow slowly, and do not in general attain any great size. They may form in any part of the orbit.

A tumor of the kind which I extirpated, had, to the naked eye, the appearance of fat, but was much firmer and more consistent to the touch, and presented microscopical characters altogether different.

Treatment.—The only treatment applicable to such tumors is total extirpation.

Encysted tumors in the orbit.

When these tumors, which may originate in any part of the orbit, present themselves externally, they form between the eyeball and margins of the orbit, a rounded, equal, elastic swelling, more or less distinctly fluctuating, and yielding to pressure, so as to retire within the orbit.

The cyst of the tumor is in some cases thin and serous, in others thick and fibrous, with cartilaginiform and even ossiform depositions. The contents may be watery (*hygroma*), like suet (*steatoma*), like pap (*atheroma*), or like honey (*meliceris*). Hairs, and in one case a tooth, have been found among the contents of orbital tumors, similar to what is of more frequent occurrence in ovarian tumors.

Treatment.—Total extirpation when, from the situation and connections of the tumor, it can be effected; if not, partial extirpation, in the hope that, by exciting inflammation on filling the cavity with charpie, the remains of the cyst may be eventually destroyed, or separated and thrown off by the suppuration. In some cases simple puncture of the encysted tumor and evacuation of its contents have been performed with success, but it is not a practice deserving of much confidence.

Operation of extirpating sarcomatous and encysted orbital tumors.

The possibility of extirpating orbital tumors with safety to the eyeball and neighboring parts, will depend on the situation, connec-

tions, and size of the tumor. If the tumor is so connected that it cannot be wholly extirpated without the eyeball, this also must be removed, if the necessity for operation is imminent.

According to the situation and size of the tumor, so must be the situation—whether through the skin or conjunctiva—direction, and extent of the external incision, and the necessity of dividing one or other eyelid vertically, or the external commissure. If the tumor be seated in the upper part of the orbit, and appears on examination by the touch, whilst the upper eyelid is moved, to be on the orbital side of the levator palpebræ, the incision should be through the skin; but if on the ocular side, through the conjunctiva.

The external incision being cautiously but freely made, and the tumor duly exposed, it is to be seized with a hook or hooked forceps, drawn forwards, and its separation effected by careful dissection with the knife, assisted by the handle, the finger, and curved scissors, whilst the blood is assiduously removed by an assistant.

The surgeon having satisfied himself by examination with the finger that the whole tumor has been removed, allows the bleeding to stop, and then proceeds to dress the wound.

The wound is first to be carefully cleansed from clotted blood, and then if it admits of being filled when the eyeball is gently pressed back into the orbit, the edges of the wound are to be united by suture or plaster, or both, according to necessity. If there is a large cavity which cannot thus be filled, the wound must be kept open, but not stuffed with charpie.

Great care is required in the after-treatment. It has sometimes happened that inflammation of the orbital cellular tissue has supervened, and, extending to the brain, has proved fatal.

Hydatidgenous cysts in the orbit.

Cysts containing hydatids have been met with in the orbit. They presented the characters of encysted orbital tumors. On making an opening into the prominent part of the tumor, fluid was evacuated, followed immediately in one case by a large hydatid, in another case, after two or three days, by half a teacupful.

Medullary tumor in the orbit.

Medullary tumors are developed sometimes slowly, sometimes quickly, with more or less pain, &c. They are generally soft and yielding, and communicate to the touch a deceptive feeling of fluctuation, so that they are apt to be confounded with encysted

tumors. Such cases are as hopeless as medullary tumor of the eyeball.

Melanotic tumor in the orbit.

Melanotic tumors have been met with in the orbit, either alone or in conjunction with the same disease in the eyeball.

Aneurism by anastomosis in the orbit.

Tumors of this kind, congenital or acquired, occur in the orbit, having either had their origin there, or being an extension of the disease from the eyelids.

The characters of such tumors are their pulsation, with whizzing noise in the head, their readily becoming diminished by pressure and increased by excitement of the circulation.

Treatment.—Ligature of the common carotid artery has been performed with success in cases of this disease; first by Mr. Travers, subsequently by Mr. Dalrymple of Norwich, and others.

True aneurism in the orbit.

A case of true aneurism of both ophthalmic arteries terminating fatally has been recorded by Mr. Guthrie.

CHAPTER XI.

INJURIES OF THE EYE.

SECTION I.—INJURIES OF THE CONJUNCTIVA AND EYEBALL.[1]

INJURIES OF THE CONJUNCTIVA FROM INTRUSION OF FOREIGN BODIES INTO THE OCULO-PALPEBRAL SPACE.

THE intrusion of foreign bodies into the oculo-palpebral space of the conjunctiva, their removal and the applications necessary in the first instance have been above treated of (p. 80, et seq.). Here the injury occasioned and its treatment come to be considered.

[1] Effusion of blood under the conjunctiva or within the eyeball, which not unfrequently occurs in those injuries, is above considered under the head of *Hæmophthalmus*, pp. 214, et seq.

Mechanical injuries.

The inflammation which supervenes on the mechanical irritation or injury done to the conjunctiva, by the intrusion of foreign bodies into the oculo-palpebral space, or by simple wounds or abrasions of the membrane by whatever means produced, differs very much in different cases, both as to seat and as to nature and severity. Sometimes the inflammation is confined to the conjunctiva, sometimes it is internal; sometimes less, sometimes more severe, and that irrespective of the severity of the injury. When conjunctival, the inflammation may present the scrofulous character or it may be puro-mucous.

These differences, though they may be determined in some degree by the nature of the injury, depend also very much on the age and constitution of the patient.

Treatment.—See Traumatic Ophthalmia, p. 181, et seq.

It is to be here observed that a certain degree of inflammatory congestion is excited by an injury, and will continue until the healing process is completed, being a necessary condition for the supply by exudation of the lymph necessary for that purpose (p. 85). It is vain, therefore, as well as improper to attempt the resolution of this due degree of inflammation. It is only to moderate undue inflammatory action that interference is called for. The distinction between *due* and *undue* must be learned by experience under the guidance of the principles previously laid down.

Chemical injuries.

According to their degree of concentration, and the length of time they have been allowed to remain in the eye, bodies chemically active may simply excite more or less severe inflammation, internal as well as external; or may at once produce very material organic injury, which is of course also followed by inflammation.

That the conjunctiva can bear a great deal in this way is proved by the strong irritants,—such as nitrate of silver ointment or even nitrate of silver in substance,—frequently applied to it by way of treatment, and by the circumstance that melted pitch, tallow, and even lead, have fallen into the eye, without any bad ultimate result. In some cases, however, the effects of the action of such agents are both severe and destructive.

The chemical agents, the intrusion of which into the eye not unfrequently occur, are lime, mineral acids, and the like, or burning hot substances.

Lime.—According as it is in the state of quick lime, slaked lime, or mortar, and according to the quantity intruded into the eye

and the length of time it has lain there, so will be the extent of the injury.

Quick lime is very fatal to the eye. Not only is the epithelium of the conjunctiva and cornea immediately decomposed, but their proper substance may be more or less completely destroyed, and the eye forever rendered useless.

Slaked lime does not produce such immediate mischief. The conjunctiva and cornea are rendered thickened, and of an opaque white appearance from decomposition of their epithelium, wherever they have been directly acted on by the caustic. Sloughs of the conjunctiva may be formed, and thrown off, leaving the sclerotica or tarsal cartilage exposed, as the case may be.

The conjunctiva is white at the places where the lime has acted most severely—elsewhere, it presents vascular injection and small spots of extravasation of blood. The conjunctiva is of a peculiar red and white marbled appearance.

The decomposed epithelium peels off in opaque white flakes. Over the cornea, it first rises in a blister, and when it has peeled off, the proper substance is left smooth, but somewhat opaque, and vessels soon form in it.

When the cornea has been implicated, if the action of the lime have not extended to its proper substance, and if the inflammation which follows is moderate, as the epithelium is regenerated, the transparency of the cornea will be gradually restored in a greater or less degree, but vascularity of it will probably remain.

If the lime have acted more deeply, or if severe inflammation has ensued, the cornea may never again become clear.

Sulphuric acid.—This has been sometimes thrown into the eyes of persons with the criminal intention of destroying sight. In such cases, besides the injury to the face and eyelids, the conjunctiva appears almost scarred, being white, soft, and swollen. It afterwards peels off, while the cornea rapidly becomes disorganized by infiltration of pus, ulceration, and sometimes sloughing.

Though the immediate effect of the injury may not be to such an extent as the above, Dr. Mackenzie remarks that dangerous symptoms, such as onyx and iritis, are apt to occur in such cases, weeks after the receipt of the injury.

Symblepharon, either mediate or immediate, and to a greater or less extent, is a common effect of injury of the conjunctiva by caustic substances. The corresponding surfaces of the eyeball and eyelid having been left raw by corrosion, ulceration, or sloughing, readily unite, and that, notwithstanding every effort of the surgeon to prevent it.

Burning hot substances.—Burns blister the conjunctiva and cornea, and sometimes excite very destructive inflammation.

When gunpowder is exploded against the eye, besides the burn which takes place by the flame and the grains in a state of ignition which are projected against the organ, unexploded grains, when the gunpowder has been confined as in a flask, are apt to be projected against and to fix in the skin of the eyelids, the conjunctiva, and the cornea.

Treatment.—The removal of caustic or burning hot substances, whether solid or fluid, and grains of gunpowder, and the treatment in the first instance, have been above considered (p. 82).

To moderate the inflammatory reaction as much as possible, the patient must be kept at rest, and his bowels opened; blood should be abstracted by venesection or leeches, and the eye covered with cold lotions.

The inflammation which supervenes must be treated according to its nature and severity. Most commonly the inflammation is puro-mucous conjunctivitis.

INJURIES OF THE EYEBALL AND ITS PROPER TUNICS.

Concussion of the eyeball.

Amaurosis is a not unfrequent consequence of even very slight blows on the eyeball, with, or without any visible injury of the organ.

Blows, contusions, and wounds of the eyebrow and margin of the orbit, without any visible injury of the eyeball, may also occasion amaurosis. In such cases the amaurosis is considered to be owing to concussion of the retina (p. 342), though most probably to extravasation of blood.

As in wounds of the eyebrow, the frontal branch of the fifth nerve is often injured, the opinion has been entertained, that the amaurosis is in some manner connected with that injury rather than concussion. Although this can scarcely be admitted, as regards amaurosis, immediately consequent on the injury, it is by no means unlikely that injury of the fifth nerve, by determining slow internal ophthalmia, may prove a cause of the amaurosis, which sometimes comes on subsequently to the injury.

Treatment.—For the treatment of the amaurosis from concussion of the eyeball, see p. 344.

The effect of a blow on the eye may be evident internal inflammation with amaurosis, probably from extravasation of blood implicating the retina. A man received a box on the eye: when seen a few days after, there was found circumcorneal injection, both sclerotic and conjunctival; the color of the iris changed, and the

pupil dilated. He could not recognize a person, but could just see that there was something before him.

Venesection to ℥xij, and one grain of calomel three times a day, were ordered.

A few days after, the inflammation was much diminished, and the sight so far improved that the patient could now recognize a person before him.

Contused wounds of the eyeball.

The eyeball bears simple incised wounds very well, but not contused wounds. Injuries of this kind, in fact, are very dangerous.

In injuries of the eyeball from contused wounds, occasioned, for example, by small shot, fragments of percussion caps, &c., striking it, with or without penetrating into its interior, if blindness from attending concussion should not be the immediate effect, it will generally be eventually occasioned by the destructive internal inflammation which supervenes. But in addition to this, the uninjured eye is, as above shown (p. 182), very prone to become similarly affected with internal inflammation.

Treatment.—See Traumatic Ophthalmia (p. 181, et seq.)

Injuries of the cornea.

Foreign bodies imbedded in the cornea.—The removal of foreign bodies adhering to the surface of the cornea, or imbedded merely in its conjunctival layer, has been above treated of. Here foreign bodies imbedded in the substance of the cornea fall to be considered.

Chips of pure metal, splinters of glass, stone, hard wood, and the like, projected against the eye, often stick, more or less deeply, in the cornea, or even wholly penetrate it, and lodge in the interior of the eye. If a part of the foreign body remains projecting, very great irritation ensues, but if the body has sunk fairly in the substance of the cornea, it may produce little reaction, or, becoming enveloped in a capsule of lymph, may cease to be a cause of irritation, and the inflammation, to which it has given rise, subside; the cornea at the part remaining opaque. More frequently, however, ulceration of the cornea takes place around the foreign body which thus becomes loose at the bottom of the ulcer requiring but a touch for its detachment.

When a chip of pure iron sticks in the cornea, and is allowed to remain any time, it becomes oxidated, and tinges the adjacent cornea of a brown color.

If any part of a foreign body which has penetrated the substance of the cornea projects, it is to be seized with a forceps and drawn

out; but if it does not project, it is necessary to use a pointed instrument, such as a large and rather blunt cataract needle for its dislodgement. In doing this, great care should be taken not to cause any abrasion of the cornea, and never to scrape it, with the intention of removing, for instance, the brown speck left by the oxidation of a fragment of iron—such a speck it is well not to interfere with.

When the foreign body is irregular in shape, and has penetrated the cornea obliquely, and to some extent, it may be necessary to make an incision with a cataract knife, so as to expose the body, which is then to be seized with a forceps, or turned out with the spatula.

It is to be observed, that when a foreign body cannot be readily got at, attempts at extraction should not be continued too long, for more injury may result from this than from the presence of the foreign body. By-and-by, it will become loose, and may then be more easily extracted.

Abrasions of the cornea.—Though the surface of the cornea may be touched without inconvenience, a sudden wipe on it, with a handkerchief, for instance, causes considerable uneasiness, lacrymation, and intolerance of light for a time.

Abrasion of the cornea is sometimes produced by a scratch of the finger nail, or by awkward attempts to remove a foreign body; or it is the result of a stroke with a twig, or with an ear of corn, an accident to which reapers are much exposed.

Punctured and incised wounds of the cornea.—The puncture or incision made in the cornea in operations generally heals soon and kindly; and even wounds produced by accident sometimes heal beyond expectation, though they are not unfrequently followed by severe and destructive inflammation. Such a result is readily accounted for by the contusion of the whole eye attending the accident, by the irregularity of the wound, perhaps a bad state of health at the time, and not unfrequently by the neglect with which the case is apt to be treated at first.

The immediate effect, in cases of penetrating wounds of the cornea, is escape of the aqueous humor, and, sometimes, protrusion of the iris. It is this latter circumstance, when it occurs, which constitutes the principal difficulty of the case, for the mere wound of the cornea may heal, and the aqueous humor be renewed in from thirty-six to forty-eight hours. Even when the accident is quite recent, it is seldom we succeed in returning the iris to its natural position—never, if but a few hours have elapsed.

If the iris be but slightly engaged in the wound of the cornea, and if this be towards the circumference, the first thing to be tried is rubbing the upper eyelid over the cornea, and then suddenly

opening the eye to a bright light. The tendency of the pupil to contract being thus excited, disengagement of the iris from the wound of the cornea is expected to follow. This proceeding may be repeated along with attempts to push the iris back into its place with a blunt probe. But, of course, all of this would be useless if the iris were at all strangulated in the wound of the cornea.

If the wound of the cornea be nearer the centre, and if it be the pupillary portion of the iris which is prolapsed, dilatation of the pupil by belladonna, prejudicial in the former case, may be tried in this, along with rubbing the eyelid over the cornea.

In regard to exciting the pupil to contract or dilate, it is to be remarked, that though the contractile power of the iris appears very considerable while supported by the aqueous humor, it becomes almost null when this is removed, in consequence of the resistance of its own weight, and the pressure of adjacent parts, to say nothing of its engagement in a wound of the cornea.

If protrusion of the iris be evidently kept up by the aqueous humor pressing it forward, this should be evacuated by puncture.

If the attempts to return the iris have failed, and if the case be still recent, the protruding iris should be snipt off with scissors, especially if it be the pupillary edge, and then friction employed as before. By this proceeding we may preserve the cornea entire, though with a pupil large and irregular. By leaving the iris protruded, synechia anterior and contracted pupil, with opacity of the cornea to a greater or less extent, if not partial staphyloma, inevitably result.

If some time has already elapsed since the accident, the case falls into the category of ophthalmia, attended by penetrating ulceration of the cornea, and protrusion of the iris.

A penetrating wound of the cornea, close to its margin, sometimes closes by the conjunctiva alone healing over it, while the proper substance of the cornea remains ununited. The consequence is, the aqueous humor elevates the conjunctiva in the form of a vesicle. This state of parts is called *fistula corneæ*, and must be distinguished from hernia corneæ and partial staphyloma.

After snipping off the elevated conjunctiva, the orifice in the proper substance of the cornea, leading into the anterior chamber, is to be touched freely with the lunar caustic pencil.

Treatment of inflammation excited by injury of the cornea.—The inflammation may be very slight, and readily subside by rest, cold lotions, and antiphlogistics.

The result of injury of the cornea, however, even when trifling in degree, is not always so slight. The inflammation is sometimes severe, obstinate, and dangerous, involving not only the cornea itself, but also other parts of the eye, both external and internal.

The membrane of the aqueous humor is particularly liable to suffer; and iritis on the one hand, and inflammation of the proper substance of the cornea, ending in purulent infiltration, on the other, are not unfrequent complications.

Inflammation from abrasion of the cornea.

A severe form of inflammation is often met in consequence of abrasion of the cornea, though a similar inflammation often arises from other injuries of the cornea. The patient presents himself to the surgeon with the cornea muddy, the iris discolored, and pupil contracted, with considerable conjunctival and sclerotic injection, such as is seen in catarrho-rheumatic ophthalmia (p. 151, et seq.) These objective symptoms are accompanied by fever, severe circumorbital or temporal pain, aggravated at night, and dimness of vision.

If the inflammation be allowed to run on, or if treatment fail to arrest its progress, purulent infiltration of the cornea, hypopyon, and effusion of lymph into the pupil, may take place singly or together. The ultimate result is loss of the eye, either by the bursting of the cornea and the formation of staphyloma, or by atrophy.

In such a case mercury is our principal remedy, after the abstraction of blood. The extent to which venesection should be carried ought to be carefully regulated by the circumstances of the case; it is not to be dreaded too much on the one hand, nor, on the other, pushed by repetition, too far. The pupil is to be kept dilated by belladonna lotion or the solution of atropine; and when the progress of the inflammation is arrested, the exhibition of bark, as a general remedy, and the application of the drops of the bichloride of mercury with vinum opii (p. 71) as a local remedy, will powerfully promote the cure.

A woman, æt. 46, received an injury of the left eye from her husband's finger being thrust into it. On the second day after the surface of the cornea was found abraded, and there was considerable conjunctival, together with some circumcorneal, sclerotic injection. The iris was somewhat discolored and the pupil contracted.

The patient complained of great pain in the eye, over the eyebrow, and in the temple, of the same side, and in addition pain still more severe over the eyebrow of the opposite side: the pain shot to the back of the head.

Calomel (gr. iij) and Dover's powder (gr. viij) were ordered to be taken at bedtime, and black draught [Inf. Sen. C.] next morning; after that, calomel (gr. j) and Dover's powder (gr. ij) three times a day. The belladonna lotion to be used for fomenting the eye with.

Under this treatment improvement took place, and I saw nothing

more of the patient for a month, when she returned complaining that, three nights before, she awoke with dreadful pain in the left eye and temple and across to the other side. On examination, I found conjunctival and sclerotic injection, with a small ulcer nearly in the middle of the cornea; the iris discolored and the pupil somewhat contracted. She was suffering sharp pain in the eye, apparently from the ulcer of the cornea; also, circumorbital and temporal pain extending from the left to the right side.

Venesection was ordered and a repetition of the calomel and Dover's powder at bedtime with black draught next morning, and after that calomel (gr. j) and opium (gr. ¼), three times a day.

She bore the abstraction of ℥xij of blood well.

On the third day after this, the report was—"Eyes almost well to-day."

A man, æt. 45, was under my care, a year and a half ago, on account of an injury to the left eye, occasioned by an infant thrusting its finger into it, and abrading the cornea, and on which inflammation of a catarrho-rheumatic character supervened.

A week ago he suffered a similar injury. This has been followed by similar symptoms. The vascular injection of the eye is slight, but the circumorbital pain is very severe.

Is subject to and now suffering from rheumatism.

To take calomel (gr. iij) and Dover's powder (gr. x) to-night, and black draught to-morrow morning.

Two days after this, the eyes were found much better. No marked vascularity, and circumorbital pain gone, merely some slight pricking pain over the eye. The rheumatic pains principally confined to the head now. To take the alkaline colchicum mixture.

A boy, æt. 5. The finger of an infant was accidentally thrust into his right eye. On examination the indented mark of the finger nail was observed about the middle of the cornea, the pupil was considerably contracted, there was great intolerance of light. The child did not complain much of pain.

Two leeches to the eye were ordered, and a powder consisting of hydrarg. c. creta and rhubarb.

When the patient was next seen, the eye was found much better, the vascularity diminished, the intolerance of light less, and the pupil no longer so much contracted.

Foreign bodies in the aqueous chamber.

Foreign bodies may penetrate right through the cornea and remain lodged in the anterior chamber, often at the same time sticking in the iris or crystalline. Eyelashes have in several in-

stances been driven in through a wound of the cornea: some of these cases have been described as examples of development of hairs within the eye.

If the wound in the cornea be large enough, an attempt may be made to extract the foreign body through it by means of the small hook delineated at page 259, or forceps at page 266. If not large enough, and if so placed that enlargement of it would not be advisable, a clean section of the cornea near its margin should be made of the necessary size, and on the side where it appears the foreign body will admit of being most readily seized. It sometimes happens that, on section of the cornea, the foreign body escapes along with the aqueous humor, when this has not been previously evacuated.

Foreign bodies, though not extracted, may cease to cause irritation by becoming enclosed in a capsule formed of lymph deposited around them; or, in the case of small particles of iron or steel, as the point of a cataract knife or needle accidentally broken off during operation, they may become oxidized and dissolved.

A lad, æt. 14, seven or eight years ago accidentally thrust a small shoemaker's knife into the right eye at the upper and outer edge of the cornea. The wound implicated the sclerotica and extended halfway across the cornea. The lens had been wounded, and prolapsus iridis taken place. On examination, the iris was found dragged up towards the cicatrice, behind which the contracted pupil was partly hid. By looking from below a piece of opaque capsule in the pupil could be seen. The iris was tremulous, and on the anterior surface of its lower part there lay an eyelash diverted from above, downwards and inwards. The former free extremity of the hair appears to be implicated in the cicatrice, and the root part is that which is directed downwards and inwards to within one-twentieth of an inch of the ciliary margin of the iris. The little black point of the bulb and the white part above were still quite appreciable. The hair was of the same color as the existing eyelashes, except that it was rather redder. It shook with every motion of the iris. The eyeball as a whole was enlarged and vision quite gone.

In a man who had five or six years before had a piece of percussion cap projected into his eye, I found it attached to the iris, near the pupillary margin, by lymph, without causing any irritation. The capsule of the lens had been wounded and the lens absorbed.

Foreign bodies which have penetrated through the cornea into the lens or deeper, may sometimes be got hold of through the still open and suppurating wound and extracted.

Injuries of the iris and pupil.

Along with the cornea, ciliary body, and other parts of the eye, the iris may be implicated in punctured, incised, and lacerated wounds.

By smart strokes on the eye, the iris is apt to be separated from its ciliary attachment.

The iris may be lacerated across in its whole breadth, and at the same time separated to a greater or less extent from its ciliary attachment.

Great and irregular dilatation of the pupil sometimes occurs, from the iris being on one side wholly displaced to behind the sclerotica.

All these injuries may be attended with more or less effusion of blood and impaired vision.

Such injuries, it will be observed, are similar in their nature to those inflicted either accidentally or intentionally in various operations on the eye, or which occur in disease as above described.

Thus when an opening is made in the iris, it gapes and remains as a false pupil. When the iris is separated at some part of its ciliary circumference, the result also is a false pupil. When the iris is torn across there is produced a state resembling coloboma iridis. Lastly, when the iris is displaced on one side to behind the sclerotica, so as no longer to be visible through the cornea, a state of pupil is presented similar to that which often occurs in posterior internal ophthalmia and choroid staphyloma.

Prognosis and treatment.—See *Traumatic Ophthalmia.*

Injuries of the crystalline body.

The crystalline body is liable to suffer from two kinds of injuries. It may be directly wounded by a foreign body or instrument which has penetrated the eyeball; or it may have its connections so broken up in consequence of a blow upon the eye or its neighborhood, that it becomes opaque. In this latter case the capsule may or may not be burst.

Wounds of the crystalline body, even when simply punctured or incised, give rise generally, though not invariably, in the human eye, to lenticular opacity, and often to more or less capsular opacity in the seat of the wound. After a wound or rupture of the capsule, the soft exterior part of the lens is sometimes seen to ooze out in the form of a semi-opaque flock.

The wound of the capsule may unite and the opaque lens remain; but when, by reason of its extent, the wound does not close, the lens is gradually dissolved, and disappears, as after the operation for cataract by division. In such a case the injury is both bane and antidote.

The wound of the eye, of which that of the crystalline is merely a part, is usually followed by an attack of internal inflammation, sometimes very severe and destructive. This may take place even after needle-operations for cataract, in which the wound is as simple as possible. The membrane of the aqueous humor and the iris are, in the least complicated cases, the parts commonly most affected; and the consequence is, effusion of lymph into the pupil.

Sometimes a wound of the capsule is followed by dislocation of the lens, an accident which occasionally happens during needle operations for cataract. The capsule may also be burst by a blow, and the lens forced out of its situation.

The extent to which the crystalline is removed from its place has been found to vary in different instances. It may be merely so far separated from its connections, as to press the iris forward, and thus obliterate the posterior chamber and diminish more or less the anterior, or it may be entirely dislocated into the anterior chamber. Cases again have been met with in which the lens has escaped through a breach in the cornea, from a blow, or, having been forced through a laceration in the sclerotica, has been found lying underneath the conjunctiva.

The capsule may accompany the dislocated lens; but this will seldom be the case in a previously healthy eye, because the connections of the capsule are everywhere so close. But it sometimes happens, that the connections of the capsule having gradually become dissolved in consequence of some slow morbid action in the interior of the eye,—the result, sometimes, of no particular cause, sometimes of a blow previously received—the slightest concussion is sufficient to cause dislocation of both it and the lens. In such a case, as a dissolved state of the vitreous body is a frequent concomitant change, the dislocated crystalline may fall back into it, or through the pupil into the anterior chamber. Sometimes the connections of the crystalline not being wholly broken up, it remains *in situ*, but is tremulous; or it is retained at some part of its circumference merely, and there moves as a door on its hinges.

A dislocated crystalline very generally becomes opaque, but not always; for instances are related, not only of a lens and its capsule, but also a lens alone, being dislocated into the anterior chamber, and remaining there for some time without losing transparency.

It generally happens in those cases in which the connections of the crystalline are slowly dissolved, that opacity also takes place. This is called *cataracta cystica;* and as it is seen bobbing up and down, or floating in the dissolved vitreous humor, the epithets *tremulans* or *natatalis* are sometimes superadded. A cystic cataract may occasionally fall through the pupil into the anterior chamber, and again slip back.—See farther on this subject the Section on Cataract (p. 230).

Treatment.—Wounds of the crystalline body are not of themselves the immediate subject of treatment, but it is the internal inflammation, which is so apt to result, that requires to be carefully attended to. A dislocated lens is frequently the cause of keeping up inflammation, and ought to be extracted; and this, even though there should be no irritation at the time, if from its hardness it is not likely to be absorbed; because, acting as a foreign body, it is apt sooner or later to give rise to inflammatory action.

The propriety of removing a lens forced out of the eyeball through a rent in its coats, and lying under the conjunctiva, is obvious, but interference will depend on the existing circumstances of the case.

A sportsman, æt. 49, in passing over a stile received a stroke on the cornea from a rebounding twig. The result was some degree of iritis. When he consulted me I detected opacity of the lens, but no rupture of the capsule.

A countryman, æt. 50, in passing through a wood received a similar stroke, whereby the upper part of the cupsule was burst and the lens somewhat displaced upwards, so that it pressed on the iris. In this case, I considered it advisable to lacerate the capsule more freely by operation.

A boy, æt. 13, suffered a similar injury. In this case the capsule was more freely lacerated by the stroke. The lens became opaque, broke up of itself, and was quickly absorbed. The pupil became quite clear. The iris continued lively. The vision as good as it ever is after the loss of the crystalline.

A man, about 24 years old, was hacking wood, when a splinter flew up and struck the eye, causing a penetrating wound of the cornea, next to its lower and inner margin. The effect of this was considerable prolapsus iridis, and inflammatory reaction. The lens also became opaque, but the capsule was not burst.

A man, about thirty years of age, healthy but not strong, in attempting to take a nail out of a board with a screw-driver, the instrument slipped and struck his right eye; the result was that his spectacles, which he had on at the time, were broken, and a vertical penetrating wound of the cornea inflicted. As appeared afterwards, the capsule of the crystalline lens was also lacerated,—probably, however, in consequence of being burst by the blow rather than directly wounded by the instrument. After three weeks homœopathic treatment the patient came under my care, when I found the eye in the following state:

There was a large quantity of lymph on the posterior surface of the cornea in the situation of the wound, and thence extending into and filling up the pupil. The pupillary margin of the iris at its outer part was adherent to the cornea in the situation of the wound.

The pupil being so filled with lymph the state of the lens could not be at first ascertained.

The vascularity of the white of the eye was chiefly limited to circumcorneal sclerotic injection. The iris was of a deep green color.

The patient had suffered very little pain.

A pill of calomel gr. ij, and opium gr. ¼, was ordered to be taken three times a day, and the eye to be bathed occasionally with tepid water.

At the end of four or five days, the mouth had become slightly affected by the mercury, and the circumcorneal sclerotic injection and greenness of the iris much diminished, whilst absorption had so far cleared away the lymph that a part of the pupil could now be seen.

The report four days after the last, *i. e.* about eight days after the commencement of the allopathic treatment, states the mouth to be much affected by the mercury—the natural color of the iris re-appearing—and the lymph on the posterior surface of the cornea and in the pupil still further diminished by absorption, so that more of the pupil was visible.

The pupil was found somewhat contracted and displaced inwards, in consequence of the implication of the outer part of the pupillary margin of the iris in the wound of the cornea.

Consistence of the eyeball natural.

Perception of light much stronger.

To intermit the calomel and opium.

According to the next report, three days after the last, *i. e.* about eleven days from the commencement of the mercurial treatment, the inflammation was still diminishing and the absorption of lymph so far advanced, that the pupil was now cleared of it so as to allow of the state of the lens being ascertained. It was now discovered that the capsule had been lacerated by the injury, and that the lens had in consequence become cataractous.

Ten days after the last report, *i. e.* after about three weeks' allopathic treatment, the circumcorneal sclerotic redness almost gone, and the iris nearly of its natural color. The wound of the cornea healed and free from lymph. The cataractous lens becoming absorbed.

Fourteen days after the last report the eye looked well. The redness of the white of the eye around cornea almost gone. Iris natural-looking, with the exception of the slight synechia anterior; pupil of natural size, and contracts or dilates according to the degree of light.

Cataractous lens slowly disappearing by absorption.

Seven weeks after the last report the lens was quite absorbed, and the pupil black. Two slight points of anterior synechia, one

at the lower and outer, and the other at the upper and outer, margin of the pupil.

Sees very well with a cataract glass.

Wounds of the sclerotica and posterior segment of the eyeball.

The tunics being divided, there is a tendency to protrusion of the vitreous body, with escape of its fluid, effusion of blood, and perhaps, protrusion of the internal tunics, and even escape of the lens.

By blows on the eye, the sclerotica, but not the conjunctiva, may be ruptured; besides this, there is necessarily more or less serious injury to the other parts of the posterior segment of the eye, such as extravasation of blood within the organ, laceration and protrusion of the internal tunics, escape of vitreous humors, sometimes of the lens, which is found under the conjunctiva.

Treatment.—Nothing more can be done in such cases but to keep the patient at rest, with his eyelids closed, and covered with cold applications, and to meet inflammation as it arises. See Traumatic Ophthalmia. The eye usually becomes atrophic in such cases.

A boy was struck in the eye by an arrow. The sclerotica was pierced behind the upper and inner edge of the cornea. Protrusion of the ciliary body with dragging of the iris took place. The inflammatory reaction which followed was not very severe. The eye became atrophic.

A woman, æt. 30, received a blow on the right eye. There was great extravasation of blood under the ocular conjunctiva, so that it was raised up somewhat like chemosis around the cornea. There was also extravasation of blood into the aqueous chambers, so that the iris could not be seen. Leeches were applied, and aperients administered. After which the pain was relieved, and absorption of the effused blood commenced. A week after, the blood had so far disappeared from the aqueous chambers that the iris and pupil could be seen. The subconjunctival ecchymosis was also removed to a considerable extent. At the upper part of the eyeball the conjunctiva was now seen to be elevated by something underneath. This was probably the lens burst through a rent in the sclerotica, especially as on examining the eye catoptrically, no lenticular images were seen. The patient did not again come under observation.

The yellowish opaque deposition, sometimes traversed by blood-vessels, at the bottom of the eye, which is a not unfrequent result of injury of the eyeball, especially of its posterior segment, has been above described under the head of non-malignant tumors (p. 209). Sclerotic staphyloma, atrophy of the eyeball, a shrunk state of the same from loss of humors and the like, have also been referred to,

as not unfrequent eventual consequences of injury of the eyeball (pp. 203, 205, 206).

Dislocation of the eyeball.

Foreign bodies forced in between the eyeball and the wall of the orbit, may cause protrusion of the former. The foreign body being removed, pressure on the eyeball, continued, steady, but gentle, will effect reduction of it; sometimes with a jerk. Vision, which had been lost from the stretching of the optic nerve and pressure on the eyeball, is on reduction sometimes quite restored.

Evulsion of the eyeball.

The eyeball, with a portion of the optic nerve, has been completely torn out of its socket by a cart-wheel going over the side of the man's head. Recovery took place. The eyeball may be blown out by a musket-shot.

Section II.—Injuries of the Eyebrow and Eyelids.

Contusion, with ecchymosis.

The effect of contusion of the eyebrow and eyelids is at first swelling, which, after a few hours, is followed by ecchymosis or extravasation of blood into the substance of the dermis, causing discoloration of the parts, or what is called a black eye. In severer cases of contusion, there is effusion of blood into the subcutaneous cellular tissue also.

Subconjunctival ecchymosis is often occasioned at the same time by contusion of the eyebrow and eyelids. Extravasation of blood may even take place into the orbital cellular tissue, occasioning some degree of exophthalmus.

Treatment.—If there is effusion of blood into the subcutaneous cellular tissue, it is to be evacuated by puncture. When the contusion is severe, it will be necessary to apply leeches and cold lotions to keep down inflammation. In simple cases, cold lotions alone may be sufficient.

The discoloration from ecchymosis disappears as the blood is absorbed; but as this takes place but slowly, various applications are made in order to hasten the process. A cataplasm of the grated roots of convallaria, or Solomon's seal, is a popular and efficient remedy, reapplied every half hour for several hours. It occasions considerable redness and œdema of the skin, with smarting. A solution of the hydrochlorate of ammonia (Ammon. hydrochlorat. ℥j, aq. destillat. ℥xiv, Alcohol dilut. ℥ij) is also a useful remedy for the purpose. Likewise a vinous infusion of Arnica flowers and rosemary (āā ℈iv) in wine (℥iv).

Incised, lacerated, and contused wounds of the eyebrows and eyelids.

Wounds of the eyebrows and eyelids are to be carefully united by strips of court plaster or by suture, according to their situation and extent. When in consequence of the wound being lacerated and contused, union does not take place by the first intention, great care will be necessary during the process of granulation—unless there be loss of substance, when healing by a broad cicatrice is rather to be attempted (p. 386)—to keep the edges of the wound drawn toward each other, and in a proper direction, with strips of plaster, so as to insure as regular a cicatrice as possible.

It is always to be kept in mind, that one great point in the treatment of wounds of the eyebrows and eyelids, is to prevent distortion of the eyelid, such as ptosis on the one hand, or lagophthalmos or ectropium on the other, taking place from irregular cicatrices.

If no undue inflammation supervenes, wounds of the eyebrows and eyelids readily heal. Even when lacerated or contused, little suppuration may take place, and but a slight scar may be left, without injury to the eyelid. Undue inflammation, phlegmonous or erysipelatous, may, however, come on. In this case, the wound must be left open and covered merely with water-dressing until the inflammation has subsided.

In wounds of the upper eyelid, as above mentioned (p. 403), the levator muscle may be divided, and ptosis thereby occasioned.

A fissure of the eyelid, like a button-hole or like hare-lip,[1] has been met with as the result of wounds of the eyelids, in which, by neglect, the edges have not been kept in apposition, but allowed to cicatrize separately. Such cases are to be treated, by making the edges of the fissure raw, and uniting them by suture.

In penetrating wounds of the eyelid, whether from the conjunctival surface of the eyeball being at the same time injured, or from its being subsequently abraded, adhesion of the eyelid to the eyeball may take place. In treating such wounds, the possibility of this should always be kept in mind, and care taken to prevent it.

Injury of the nerve of the fifth pair in wounds of the eyebrow has been above referred to (p. 456).

Poisoned wounds.

When the eyelids happen to be stung by wasps, bees, or the like, there is considerable swelling and irritation, sometimes severe ery-

[1] The fissure like hare lip has been called *coloboma*, or, since the name has been employed generically, *coloboma palpebræ*, the other species being *coloboma iridis* (p. 303). A congenital fissure of the eyelid (*congenital coloboma palpebra*) has been met with.

sipelatous inflammation of the part, ending in the formation of a small slough.

If the sting of the insect has been left in the wound, an attempt should be made to extract it. Whether this proves successful or not, the part is to be rubbed with olive oil, and covered with cloths wet with a fresh-made solution of the hydrochlorate of ammonia.

If there is any general disturbance of the system occasioned by the injury, a glass or two of wine may be taken, or a few drops of ammonia in sugared water occasionally.

Malignant pustule, which might be brought under the head of poisoned wounds, has been already treated of (p. 373).

Burns and scalds.

Scalds of the eyebrows and eyelids, in which the texture of the dermis is not injured, are of comparatively small consequence, except in so far as the conjunctiva may be complicated. Slight burns may be also unimportant in their effects, but when the burn is so severe that the dermis is injured, then there is great danger of such contraction taking place, in cicatrization, as to occasion lagophthalmos or ectropium.

To oppose as much as possible the tendency to contraction during cicatrization, the eyelids must be kept closed, luxuriant granulation encouraged, and cicatrization retarded.

Another danger of burns, and this is also the principal danger from severe scalds, is, supposing the eyeball to have escaped, anchyloblepharon, when the borders of the eyelids have been rendered raw, and the patient allowed to lie with his eyes closed.

When gunpowder is exploded against the eye, the injury is seldom confined to the eyebrow and eyelids. See above (p. 456).

Section III.—Injuries of the Lacrymal Organs.

Injuries of the lacrymal gland and ducts.

While the upper mass of the lacrymal gland is, from its situation, well protected from injury, the ducts, together with the lower mass of the gland, may readily be implicated in a wound of the upper eyelid. Wound of the lower mass of the gland, together with some of the lacrymal ducts in Crampton's operation for entropium, is above referred to, p. 397, foot-note. In a case of lacerated wound of the upper eyelid involving the ducts and lower mass of the gland, sinuses formed, and the wound showed no disposition to heal.

In a case of gun-shot wound, related by Larrey, the ball struck

towards the superior external angle of the left orbit. Being cleft into two, one half took the direction of the temple, the other half lodged in the upper mass of the lacrymal gland, along with which, in a lacerated state, it was removed by enlarging the wound in the eyelids. The wound healed, the eye was saved, and continued to be sufficiently moistened.

Injuries of the derivative lacrymal organs.

Foreign body in the punctum.—A loose eyelash sometimes gets into one of the puncta by one end, and by the other, which projects, irritates the lacrymal caruncle, as above mentioned (p. 420). The possibility of this accident should be kept in mind, and attention directed to the state of the puncta in any case of irritation at the inner canthus. Dr. Mackenzie, who has seen a number of such cases, mentions that in one of them, the patient himself detected the hair as the cause of irritation, but not recognizing its unusual mode of implantation, he made it be cut short with a pair of scissors, but this only rendered the irritation greater. Demours relates a case in which a piece of barley awn got introduced into the lacrymal point, one end projecting out to a small extent. The foreign body being discovered, the removal of it is an obvious and simple matter.

Injuries involving the lacrymal papillæ, puncta, and canalicules.—Wounds of these parts are not of common occurrence. The edges should be brought accurately together, and retained so by stitches, in order, if possible, to obtain union by the first intention. But this is only a means towards the great object of preserving the permeability of the passages. For this purpose, a pin, rendered blunt at the point, and properly bent, should be introduced along the wounded canalicule as far as the sac, and retained for the first two or three days after the injury. I am not aware, however, of any case in which such a practice has been successful. (See p. 435).

Injury of the papillæ, puncta, and canalicules, may be occasioned by burns, caustics, &c.

Injury of the lacrymal sac.—A simple penetrating wound of the lacrymal sac will heal if the lining membrane be healthy, but a fistulous opening is apt to remain if the lining membrane has not been in a healthy state originally, or if it has in consequence of the injury fallen into such a state. This is more apt to happen in consequence of laceration or contusion of the part, and that especially in scrofulous subjects.

Mr. Lawrence mentions his having seen three or four instances of the lacrymal sac being burst by a blow, with escape of air into the cellular tissue of the lids; the emphysematous swelling, which was considerable, but not extending beyond the palpebræ, disap-

peared spontaneously in a few days. Emphysema of the eyelids may also arise from wound of the frontal sinuses.

In injuries of the osseous walls of the nose, the nasal duct may be implicated, the bones being driven in and pressing on the duct. When such appears to be the case, it would be warrantable to open the sac by incision, and insert a style into the duct, in order to prevent its being obliterated by any encroachment of its fractured walls.

Section IV.—Injuries of the Orbit.

Blows, &c., on the edge of the orbit.

Such injuries are, as above stated, the cause sometimes of periorbitis, running into suppuration and disease of the bone; sometimes of orbital tumors; sometimes of concussion of the eyeball.

Penetrating wounds of the orbit.

Injury of the orbit from penetrating wounds is necessarily attended with external wound of the eyelids, &c., but this, it is to be remarked, may be very small.

The consequences of such injuries of the orbit may be:

1. Swelling of the eyelids, protrusion of the conjunctiva, and exophthalmus, from effusion of blood into the orbit.
2. Inflammation of the orbital cellular tissue, especially if any portion of the wounded body has been left lodged in the orbit.
3. Injuries of the muscles and nerves of the orbit, sometimes dislocation of the eyeball (p. 468).

As the instrument inflicting a penetrating wound of the orbit may, by piercing the orbital plate of the frontal bone, wound the brain, accidents of this kind must always be regarded with great anxiety, and carefully watched and treated.

The importance of keeping in mind the possibility of a foreign body having penetrated and become lodged in the orbit, has been above (p. 87) insisted on.

If a foreign body has penetrated into, and lodged in the orbit, it must be extracted as soon as possible. By its extraction the risk of inflammation will be diminished, and if the eyeball is at the same time dislocated, restoration of it to its proper position, in the manner above indicated (p. 468), will be possible. If, however, from the situation of the body, removal does not admit of being readily effected, attempts should not be persisted in, and, especially if inflammation has already come on, it will be safer to wait.

Rest, and the antiphlogistic regimen, more or less strict, must not only be enjoined, but the case must be closely watched for some time, in order that inflammation may at its onset be duly met.

GLOSSARY.

ACHROMATOPSIA (*a*, priv. *χρῶμα, color, ὤψ, the eye*), want of power to distinguish colors.

AEGILOPS (*αἰγίλωψ*, from *αἴξ, αἰγός, a goat, ὤψ, the eye*), a name given by the older surgeons to a sinuous ulcer at the inner corner of the eye, from its resemblance to the *larmier*, or infra-orbital glandular sac of goats and other ruminating animals.

ALBUGO (albus, *white*), an opacity of the cornea.

AMAUROSIS (*ἀμαύρωσις, obscuration*, from *ἀμαυρόω, to render obscure*), impairment or loss of vision from paralysis of the optic nervous apparatus.

AMBLYOPIA (*ἀμβλύς, dull, ὤψ, the eye*), impaired vision from defective sensibility of the retina.

AMPHIBLESTROIDITIS (*ἀμφιβληστροειδής, the retina*, from *ἀμφίβληστρον, a net*, and *εἶδος, form*), retinitis, or inflammation of the retina.

ANCHILOPS (*ἀγχίλωψ*, from *ἄγχι, near*, and *ὤψ, the eye*), name given by the older surgeons to the abscess at the inner corner of the eye, ending in the sinuous ulcer which they called Aegilops.

ANCHYLOBLEPHARON (*ἀγκύλος, crooked, βλέφαρον, eyelid*), cohesion of the eyelids to each other at their borders.

ASTHENOPY (*a*, priv. *σθένος, strength*, and *ὤψ, the eye*), weaksightedness.

ATRESIA (*a*, priv. *τιτράω, to perforate*), closure or imperforation; applied to the pupil, etc.

BLEPHARITIS (*βλέφαρον, eyelid*), inflammation of the eyelids.

BLEPHAROBLENNORRHŒA (*βλέφαρον, eyelid, βλέννα, mucus, ῥέω, to flow*), first stage of puro-mucous inflammation of the conjunctiva.

BLEPHAROPHTHALMIA (*βλέφαρον, eyelid, ὀφθαλμός, eye*), called also Blepharophthalmo-blennorrhœa, puro-mucous inflammation of the conjunctiva in its fully formed state.

BLEPHAROPLEGIA (*βλέφαρον, eyelid, πληγή, stroke or blow*), paralysis of the eyelid.

BLEPHAROPTOSIS (*βλέφαρον, eyelid, πτῶσις, a falling down*), called also simply Ptosis, a falling down of the upper eyelid.

BLEPHAROSPASMUS (*βλέφαρον, eyelid, σπασμός, spasm*), spasm of the eyelids.

BUPHTHALMOS (*βους, οχ, ὀφθαλμός, eye*), OCULUS BOVINUS, dropsical enlargement of the eye.

CANTHUS (*κανθος, the rim of a wheel*), angle of the eye.

CATARACT (καταράκτης, from καταῤῥάσσω, *to throw down with violence, to break or disturb*), opacity of the lens or its capsule.

CERATITIS (κέρας, *horn, cornea*), inflammation of the cornea.

CERATOCELE (κέρας, *horn, cornea*, κήλη, *tumor*), hernia of the cornea.

CERATOME (κέρας, *cornea*, τομὴ, *section*), a knife for making an incision of the cornea.

CHALAZION (χάλαζα, *grando, or hailstone*), a small tumor of the eyelid.

CHEMOSIS (χήμωσις, from χῆμη, *a gaping*, from χαινω, *to gape;* or χύμωσις, from χυμὸς, *humor, or fluid*), elevation of the conjunctiva like a wall round the cornea, from exudation into the subjacent cellular tissue.

CHOROIDITIS (choroid, from χόριον, *chorion, one of the membranes of the fœtus*, εἶδος, *likeness*), inflammation of the choroid.

CHROMATOPSY, or CHROMOPSY (χρῶμα, *color*, ὄψις, *vision*), chromatic or colored vision.

CHROOPSY, or CHRUPSY (χρόα, *color*, ὄψις, *vision*), chromatic vision.

CILIA (celo, *to cover or conceal, because they cover and protect the eye*, or from cieo, *to move*), eyelashes.

CIRSOPHTHALMIA (κιρσὸς, *varix*, ὀφθαλμὸς, *the eye*), a varicose state of the bloodvessels of the eye.

CLAVUS (*the head of a nail*), a certain degree of prolapse of the iris, through an opening in the cornea; the prolapsed portion of the iris being pressed flat like the head of a nail.

COLLYRIUM (κολλύριον, from κολλύρα, *a cake; bread sopped according to Scaliger, this being a common application to the eyes*), a medicine for the eyes.

COLOBOMA (κολόβωμα, *mutilation*), applied to fissures of the eyelids and of the iris, congenital or traumatic.

CORECTOMIA (κόρη, *pupil*, ἐκ, *out*, τέμνω, *to cut*), operation for artificial pupil by excision.

COREDIALYSIS (κόρη, *pupil*, διαλύω, *to loosen*), operation for artificial pupil by separation.

COREMORPHOSIS (κόρη, *pupil*, μόρφωσις, *formation*), operation for artificial pupil in general.

COREONCION (κόρη, *pupil*, ὄγκος, *hook*), hook invented for the operation for artificial pupil by separation.

COREPLASTICE (κόρη, *pupil*, πλαστικὴ, *the art of making images*), operation for artificial pupil in general.

CORNEA (*cornu, horn*), the cornea was so called from its horny appearance.

COROTOMIA (κόρη, *pupil*, τέμνω, *to cut*), operation for artificial pupil by incision.

CURETTE (*French for a small spoon*), DAVIEL'S spoon, an instrument used to assist the exit of the lens in the operation of extraction.

DACRYOADENITIS (δακρύω, *to weep*, ἀδὴν, *gland*), inflammation of the lacrymal gland.

DACRYOCYSTITIS (δακρύω, *to weep*, κυστις, *sac*), inflammation of the lacrymal sac.

DACRYO-SYSTO-BLENNORRHŒA (δακρύω, *to weep*, κυστις, *sac*, βλέννα, *mucus*, ῥέω, *to flow*), blennorrhœa of the lacrymal sac.

DACRYOHÆMORRHYSIS (δακρύω, *to weep*, αἷμα, *blood*, ῥέω, *to flow*), sanguineous lacrymation.

DACRYOLITES (δακρύω, *to weep*, λίθος, *a stone*), calculous concretions deposited in the lacrymal passages.

DACRYOMA (δακρύω, *to weep*), stillicidium lacrymarum.

DIPLOPY (διπλόος, *double*, ὤψ, *vision*), double vision.

DISTICHIASIS (δὶς, *twice*, στίχος, *a row*), a form of trichiasis in which the maldirected eyelashes form a second row distinct from the others.

ECTROPIUM (Ἔκτροπιον, from ἐκ, *out*, τρέπω, *to turn*), eversion of the eyelids.

ENCHANTHIS (ἐν, *in*, κάνθος, *the corner of the eye*), enlargement of the lacrymal caruncle.

ENTROPIUM (*ἐν, in, τρέπω, to turn*), inversion of the eyelids.

EPICANTHUS (*ἐπὶ, upon, κανθός, angle of the eye*), a congenital peculiarity of a fold of skin extending over the inner canthus.

EPIPHORA (*ἐπὶ, upon, φέρω, to carry*), watery eye from excess of lacrymal secretion.

EXOPHTHALMOS and EXOPHTHALMIA (*ἐξ, out, ὀφθαλμός, eye*), protrusion of the eyeball. Exophthalmos is used when the eyeball is otherwise uninjured; exophthalmia, when, in addition to the protrusion, there is disorganization of the eyeball.

GERONTOXON (*γερων, old, τόξον, a blow*), arcus senilis.

GLAUCOMA (*γλαυκός, sea-green*), a greenish opaque appearance behind the pupil.

GRANDO (*hailstone*), a small tumor of the eyelid.

GUTTA OPACA, name given by the Arabians to cataract, as they supposed it an opaque drop in front of the lens.

GUTTA SERENA (drop serene) name given by the Arabians to amaurosis, supposing it to depend on a clear drop fallen from the brain into the eye.

HAEMOPHTHALMOS, HAEMOPHTHALMIA (*αἷμα, blood, ὀφθαλμός, the eye*), sanguineous effusion into the eye.

HEMERALOPIA (*ἡμέρα, day, ὄψις, vision*), night-blindness. It has been also employed to mean day-blindness (*ἡμέρα, day, α*, priv. or *ἀλαός, blind, ὄψις, vision*).

HEMIOPY (*ἡμισυς, half, ἔψις, vision*), a defective state of vision, in which one half of objects only is seen.

HORDEOLUM (hordeum, *barley*), stye.

HYALITIS, or HYALOIDITIS (*ὕαλος, glass*), inflammation of the hyaloid membrane.

HYDROPHTHALMIA, or HYDROPHTHALMOS (*ὑδωρ, water, ὀφθαλμός, the eye*), dropsy of the eye.

HYPERKERATOSIS (*ὑπερ, above, κεράς, cornea*), conical cornea.

HYPOAEMA (*ὑπὸ, under, αἷμα, blood*), blood in the anterior chamber.

HYPOCHYMA (*ὑπόχυμα*, or *ὑπόχυσις*, from *ὑκὸ, under, χύμα, effusion*), cataract.

HYPOGALA (*ὑπὸ, under, γάλα, milk*), effusion of a milky-like matter in the anterior chamber.

HYPOPYON (*ὑπὸ, under, πὸον, pus*), pus in the anterior chamber.

IRIANKISTRON (*ἶρις, iris, ἄγκιστρον, a fish-hook*), an instrument invented for performing the operation of artificial pupil by separation.

IRIDAUXESIS (*ἶρις, iris, αὔξησις, growth*), thickening or growth of the iris from exudation into its substance.

IRIDONCOSIS (*ἶρις, iris*, and *ὄγκὸς, tumor*), a name formerly proposed by Von Ammon for the same morbid state of the iris as that to which he has since given the name IRIDAUXESIS; but now applied to an abscess of the iris.

IRIDECTOMIA (*ἶρις, iris, ἔκ, out, τέμνω, to cut*), operation for artificial pupil by excision.

IRIDECTOMEDIALYSIS (*ἶρις, iris, ἔκ, out, τέμνο, to cut, διάλυσις, separation*), operation for artificial pupil by a combination of excision and separation.

IRIDENCLEISIS (*ἶρις, iris, ἐν, in*, and *κλείω, to close*), the strangulation of a prolapsed portion of the iris between the lips of an incision in the cornea in certain operations for artificial pupil.

IRIDODIALYSIS (*ἶρις, iris, διάλυσις, separation*), the operation for artificial pupil by separation.

IRIDOSCHISMA (*ἶρις, iris, 'σχίσμα, fissure*), a fissure of the iris. See COLOBOMA IRIDIS.

IRIDOTOMIA (*ἶρις, iris, τομὴ, section*), the operation for artificial pupil by incision.

IRIDOPERIPHAKITIS (*ἶρις, iris, περὶ, over, φακος, a lens or lentil*), inflammation of the uvea and anterior wall of capsule of the lens.

KERATITIS (*κέρας, horn, cornea*), inflammation of the cornea.

KERATONYXIS (*κέρας, cornea, νύξις, a puncture*), corneal puncturation in needle operations for cataract.

KORECTOMIA. See CORECTOMIA.

KOREDIALYSIS. See COREDIALYSIS.

KOROMORPHOSIS. See COROMORPHOSIS.

KOREPLASTICE. See COREPLASTICE.

KOROTOMIA. See COROTOMIA.

LAGOPHTHALMOS (*λαγός, a hare, ὀφθαλμός, the eye*), oculus leporinus, or hare's eye. Retraction or shortening of either eyelid.

LEUCOMA (*λευκόω, to whiten*, or *λευκός, white*), opacity of the cornea from a cicatrice.

LIPPITUDO (lippus, *blear eyed*), blear eye.

LUSCITAS (luscus, *blind of one eye*), fixed misdirection of the eye.

MADAROSIS (*μαδάρωσις*, from *μαδός, bald*), a falling out of the eyelashes.

MARMARYGE (*μαρμαρυγή, splendor*), an appearance of sparks or coruscations before the eyes.

METAMORPHOSY (*μεταμορφόω, to transform, ὄψις, vision*), distorted appearance of objects.

MICROPHTHALMOS (*μικρός, small, ὀφθαλμός, the eye*), smallness of the eye from imperfect development.

MICROPY (*μικρός, small, ὄψις, vision*), a state of vision in which objects appear smaller than natural.

MILIUM (*a millet seed*), a small white tumor of the eyelids or their neighborhood.

MONOBLEPSIS (*μόνος, single, βλέψις, view*), state in which vision is distinct only when one eye is used.

MUCOCELE (*μυξα, mucus, κήλη, a tumor*), dropsy of the lacrymal sac.

MUSCÆ VOLITANTES (musca, *a fly*, volito, *to fly about*), the appearance of grayish motes before the eyes.

MYDRIASIS (*ἀμυδρός, obscure*, or *μυδάω, to abound in moisture*, because it was supposed to be owing to redundant moisture), preternatural dilatation of the pupil.

MYOCEPHALON (*μυῖα, a fly, κεφαλή, the head*), a small protrusion of the iris, like a fly's head, through an ulcerated opening in the cornea.

MYODESOPSIA (*μυῖα, a fly, ὄψις, vision*), muscæ volitantes.

MYOPY (*μύω, to shut, ὤψ, the eye*), nearsightedness.

MYOSIS (*μύω, to shut*), preternatural contraction of the pupil.

MYOTOMY (*μῦς, a muscle, τέμνω, to cut*), section of muscles. Ocular myotomy, section of muscles in strabismus.

NYCTALOPIA (*νύξ, night, ὄψις, vision*), day-blindness. Employed also for night-blindness (*νύξ, ἀ*, priv. or *ἀλαός, blind, ὄψις, vision*).

NYSTAGMUS (*νυσταγμός, sleep*), oscillation of the eyeball.

OCULUS BOVINUS (bos, bovis, *an ox*), ox-eye; see BUPHTHALMOS.

OCULUS LEPORINUS (lepus, leporis, *a hare*), hare's-eye; see LAGOPHTHALMOS.

ONYX (*ὄνυξ, a nail*), deposition of matter in the substance of the cornea.

OPHTHALMIA (*ὀφθαλμός, the eye*), a general name for inflammation of the eye.

OPHTHALMIA NEONATORUM (*νέος, young*), purulent ophthalmia of new-born infants.

OPHTHALMITIS, inflammation of the whole eyeball.

OPHTHALMODYNIA (*ὀφθαλμός, eye, ὀδύνη, pain*), pain in the eye.

OPHTHALMOLOGY (*ὀφθαλμός, eye, λόγος, a discourse*), the science of ophthalmic medicine and surgery.

OPHTHALMOPLEGIA (*ὀφθαλμός, eye, πληγή, a blow or stroke*), paralysis of the muscles of the eyeball.

OPHTHALMOPTOSIS (*ὀφθαλμός, eye, πτῶσις, a falling down*, from *πίπτω, to fall*), the protrusion of the eyeball, resulting from paralysis of its muscles.

OPHTHALMOSCOPE (*ὀφθαλμός, eye, σκοπέω, to examine*), the instrument for exploring the interior of the eye.

OPHTHALMOSCOPY (*ὀφθαλμός, eye, σκοπιὰ, a looking out*), exploration of the eye.

OXYOPIA (*ὀξὺς, sharp, ὤψ, the eye*), preternatural acuteness of vision.

PACHEABLEPHARA, PACHYTES (*παχύτης, thickness*, from *παχὺς, thick, βλέφαρον, eyelid*), enlargement and thickening of the eyelid.

PALPEBRÆ (a palpitando, *from their frequent motion*), the eyelids.

PANNUS (pannus, *cloth*), a thickened and vascular state of the conjunctiva corneæ.

PERIORBITA (*περὶ, over*), the periosteum of the orbit.

PHLYCTENULA (*φλύκταινα, a vesicle*, from *φλύζω, to gush forth*), vesicle filled with a watery fluid.

PHOTOPHOBIA (*φῶς, light, φοβέω, to dread*), intolerance of light.

PHOTOPSIA (*φῶς, light, ὄψις, vision*), subjective appearance of light before the eyes.

PHTHEIRIASIS (*φθειρίασις, morbus pedicularis*, from *φθεὶρ, a louse*), pediculi among the eyelashes and hairs of the eyebrows.

PINGUECULA (pinguis, *fat*), a small tumor on the white of the eye near the edge of the cornea, apparently but not really adipose.

PLADAROTES (*πλαδαρὸς, flaccid*), thickening of the palpebral conjunctiva.

PRESBYOPY (*πρέσβυς, old, ὤψ, the eye*), farsightedness.

PROPTOSIS (*πρὸ, before, πτῶσις, a falling down*, from *πίπτω, to fall*); see OPHTHALMOPTOSIS.

PSOROPHTHALMIA (*ψώρα, scabies, ὀφθαλμὸς, the eye*), ophthalmia tarsi.

PTERYGIUM (*πτερὸν, a wing, πτερύγιον, a small wing*), thickened and vascular state of a portion of the conjunctiva, of a triangular shape, the apex encroaching more or less on the cornea.

PTILOSIS (*πτίλωσις, bald*), falling out of the cilia; see MADAROSIS.

PTOSIS (*πτῶσις, a falling down*, from *πίπτω, to fall*), falling down of the upper eyelid.

PUPIL (*pupilla*), the aperture in the iris.

RETINITIS (rete, *a net*), inflammation of the retina.

RHEXIS, or RHEGMA OCULI (*ῥῆξις* and *ῥῆγμα, a rupture*), rupture of the eyeball.

RHYTIDOSIS (*ῥυτίδωσις, a wrinkling*, from *ῥυτιδόω, to wrinkle*), collapsed or contracted state of the cornea.

SCLEROTITIS (*σκληρὸς, hard*), inflammation of the sclerotica.

SCOTOMATA (*σκότωμα, dizziness*, from *σκοτόω, to darken*), dark spots seen before the eyes; see MUSCÆ VOLITANTES.

STAPHYLOMA (*σταφυλὴ, a grape*), a projection of some part of the eyeball, generally of the cornea and iris, or sclerotica and choroid.

STAPHYLOMA RACEMOSUM (racemus, *a bunch of grapes*), staphyloma is so called when there is an appearance of several projections.

STENOCHORIA (*στενοχωρία, narrowness of space*, from *στενὸς, narrow, χῶρος, space*), a contraction; applied to the derivative lacrymal passages.

STEREOSCOPE (*στερεὸς, solid*, and *σκοπέω, I look at*), the instrument described at page 351.

STILLICIDIUM (stillo, *to drop*, cado, *to fall*), dropping of tears from the eye, in consequence of obstruction of the derivative lacrymal passages.

STRABISMUS (*στραβίζω, to squint*, from *στραβὸς, twisted*), squinting.

SYMBLEPHARON, (*σὺν, together, βλέφαρον, eyelid*), adhesion of the eyelids to the eyeball.

SYNCHYSIS (*σύγχυσις, mixture*, from *σὺν, together*, and *χέω, to pour*), dissolution of the vitreous body.

SYNECHIA (*συνέχεια, continuity*, from *συνέχω, to keep together*), adhesion of the iris to the cornea or capsule of the lens; in the former case it is distinguished as anterior synechia, in the latter as posterior synechia.

SYNIZESIS (*συνίζησις, a falling together*, from *συνίζέω, to set together*), closure of the pupil.

TARSORAPHIA (*ταρσος, tarsus, ῥαφη, a suture*), suture of the tarsal margins in ectropium of the external angle.

TARAXIS (*τάραξις, disturbance*, from *ταράσσω, to disturb*), slight external ophthalmia.

TRACHOMA (*τραχομα, roughness, τραχόω, to make rough*), granular conjunctiva.

TRICHIASIS (*θρίξ, a hair*), inversion of the eyelashes.

TRICHOSIS (*θρίξ, a hair*), TRICHOSIS BULBI, a small tumor on the front of the eyeball with hair growing on it.

TYLOSIS (*τύλος, callosity*), thickening and induration of the borders of the eyelids.

XEROMA, XEROPHTHALMIA, XEROSIS (*ξηρός, dry*), dryness of the eye, of which there are two kinds, viz., conjunctival and lacrymal.

INDEX.

Abscess of anterior chamber, 200
cornea, 94, 188
iris, 100, 162
lacrymal caruncle, 420
lacrymal sac, 428, 430
Meibomian glands, 379
orbit, 446, 447
Abscission of iris, 297
Absorption, cure of cataract by, 237, 238, 274, 282
of orbit from pressure, 448
Accidental or complementary colors, 331
Acetate of lead precipitated on ulcerated conjunctiva and cornea, 189
in granular conjunctivitis, 184, 185, 186
in tarsal inflammation, 375, 377, 378
Acute inflammation, 86
Adaptation of an artificial eye, 206
Adjustments, optical, of the eye, abnormal states of, 304, 318
Aegilops, 46, 427
Albugo, 190
Alternating applications in chronic conjunctivitis, 185, 186
Amaurosis, 331, 336
apoplectic, 342
hydrocephalic, 342
from congestion or inflammation of nervous optic apparatus, 339, 342, 343
causes of, 339, 343
considered nosologically, 336
pathologically, 340
therapeutically, 343
definition of, 336
diagnosis of, 235, 339
nosologically considered, 336
pathologically " 340
therapeutically " 343
from aneurism of central artery of retina, 342
apoplexy of eye, 342, 344
from blows on eye, 344, 456
cerebral congestion, 343
concussion of retina, 456
or other injury of the head, 456
depressed or reclined lens, 268, 274, 281
disease in antrum, 342
of frontal sinus, 342
disordered digestive organs, 343
dropsy of the eye, 211, 212, 213
encephalic aneurism, 342

Amaurosis from enlarged pituitary gland, 342
exostosis of orbit, 342
fractured cranium with depression, 342
hæmorrhagy, 342
hydrocephalus, 342, 343
inflammation of orbital cellular membrane, 446, 342
the posterior tunics of the eye, 170, 172, 173, 342
injuries of branches of fifth nerve, 456
intense light, 342, 343, 344
intoxication, 343
irritation of branches of fifth nerve, 343
laceration of retina, 342
lightning, 344
loss of fluids, 344
masturbation, 344
morbid changes affecting membranes or bones of cranium, 342, 343
in optic nerves, 342
formations in brain, 344
onanism, 344
ophthalmia interna posterior, 170, 173, 342
over exercise of sight, 343, 344
pressure on eye, 342, 343, 344, 450
sanguineous extravasation in head, 342
spermatorrhœa, 344
suckling, 344
suppressed menses, 343
perspiration, 344
purulent discharge, 344
tumors in brain, 342
orbit, 342, 343, 450
venery, 344
worms, 343
wounds of eyebrows or eyelids, 456
degrees in, 336, 337
lactantium, 344
prognosis in, 339, 343, 344
seats of, 338, 340, 341, 342
symptoms of, 336, 337, 338
traumatica, 456
treatment of, 343, 344
with debility, 344
post-febrile ophthalmitis, 180
Amblyopy, or incomplete amaurosis, 64, 320, 335, 336
Anchyloblepharon, 407
Anchylops, 46, 427
Anel's probes, uses of, 434, 436, 437
syringe, injection with, 452, 442
Aneurism by anastomosis in orbit, 453
of eyelids, 411
of central artery of retina, 342
cerebral arteries, a cause of amaurosis, 341
ophthalmic artery, 341, 453
Angles of eye, exploration of, 44
Anodyne friction, 78
Anterior chamber, abscess of 200
Antrum, pressure on orbit from, 450
disease of, causing amaurosis, 341
Apoplexy, amaurosis from, 341
of eye, 341, 344

Applications to the eyes, cold, 66
warm, 66, 67
alternating, in conjunctivitis, 185, 186
Aqueous chambers, dropsy of, 201, 211
foreign bodies in, 461
humor, evacuation of, 83, 112
loss of, 458, 459
Aquo-capsulitis, 156
Arcus senilis, 55, 247
Arthritic ophthalmia, 164, 171
ring, 54, 55, 164, 171
Artificial dilatation of the pupil, 59, 60
eye, 206
pupil, 283
by abscission, 297
distortion, 298
excision, 289–293
incision, 285–289
separation, 293–297
compound operations for, 300, 301
general conditions for, 284
states of eye requiring, 300, 301
Asthenopy, 319
Atresia iridis, 99, 100, 202
of lacrymal puncta, 433
Atrophy of eye, 205
Atropia, solution of sulphate of, 59, 60, 71

Beer's cataract knife, 249
Belladonna, uses of, 59, 60, 78, 111, 112, 191, 210, 244
Blear eyes, 376
Bleeding, general, in ophthalmic inflammation, 75, 110
Blennorrhœa of derivative lacrymal organs; 429
Blepharitis, scrofulosa, 376
Blepharospasmus, or spasmodic closure of the eyelids, 40
Blood effused into eye, &c., 214, 456, 467, 468
vessels, arrangements of, in ophthalmiæ, 52
Blows on eye, 456
Bluish-white ring round the cornea, 54, 55, 156, 164
Bluestone in granular lids, 184, 185
Borax in granular lids, 186
Brain, morbid formations in, producing amaurosis, 343
Burns of cornea, 455
eyelids, 470
Bursting of eye from blows, 467

Calculus, lacrymal, 445
Meibomian, 408
Callosity, scirrhoid, of eyelids, 412
Cancer of eyeball, 221
eyelids, 412
soft, of eyeball, 221
Canthi, exploration of, 44
Capsule, aqueous, inflammation of, 96, 99, 156
crystalline, inflamed, 166, 102
injuries of, 463
Carbuncle of eyelids, 373
Caruncula lacrymalis and semilunar fold, chronic enlargement of, 420
fungus of, 421
inflammation of, 419, 420

Caruncula lacrymalis polypus of, 421
scirrhus of, 422
Caries of orbit, 392, 449
os unguis, 431
Cataracta cum zonula, 241
cystica, 464
lymphatica, or false cataract, 231
pyramidata, 231, 238
tremulans vel natatilis, 240, 464
traumatica, 103, 463
Cataract, 230
anterior capsular, 238
black, 233
capsular, 238
capsulo-lenticular, 239
causes of, 235, 238, 239
central, 238, 240
complications of, 242
congenital, 240, 280
couching of, 266
cure of, by absorption or dissolution, 241, 274, 282
operation, 241
definition of, 230
depression of, 266
diagnosis of, 231, 232, 235, 238, 239, 240
displacement of, 266, 268, 272, 281
division of, 274, 275, 278, 280, 282
examination of cases of, 59, 60, 231
extraction of, 247, 265
fibrinous, or false cataract, 231
firm, or hard, 232, 233
fluid, 276, 240
genera and species of, 230
glasses, 282
green, 346
hard, 232
history of pathology of, 345
lenticular, 231, 237
Morgagnian, 240
operations for, 241
pigmentous, 231
position of patient in operations for, 244
posterior capsular, 239
prognosis in, 237, 238, 239, 240, 241
purulent, or false cataract, 231
reclination of, 268, 272
sanguinous, or false cataract, 231
secondary, 280
siliquose, 241, 266
soft, 237, 274
spontaneous displacement of, 240, 464
trabecular, 231
treatment of, without operation, 241
questions regarding removal of, by operation, 241
Cataracts from inflammation, 231, 239
spurious, 231
true, 231
Catarrhal ophthalmia, 88, 116
Catarrho-rheumatic ophthalmia, 151
Cataplasms to the eyes, warm, 66, 372

Catgut, as a means of dilating the nasal duct, 441
Catoptrical examination of the crystalline body, 60
Cat's eye, 345
Cautery, potential, application of, to the eye, 74
Cellular membrane of orbit, induration of, 446
infiltration of, 450
inflammation of, 446
Celsus's operation for lagophthalmos, 385
Cerebral congestion causing amaurosis, 342
Chalazion, 410
Chemosis, 51, 78, 89, 123, 126, 131
excision and incision of conjunctiva in, 78
Cheselden's operation for artificial pupil, 285, 304
Choroid, non-malignant tumors of, 218
wounds of, 467
Choroiditis, 101, 168, 169
Chromatic vision, 318
Chronic inflammation, 86
Chroopsy, 327
Cicatrices, eversion of lids from, 385
of cornea, 97, 190
Cilia, exploration of, 41, 42
inversion of, 398
Cirsophthalmia, 203
Cold applications to the eyes, 66
lotions, 66
douche bath, 66
dry, 67
Collyria, 68
Coloboma iridis, 59, 302
palpebræ, 469
Colored vision, 318
Colors, accidental or complementary, 330, 331
defective perception of, 332
Complementary colors, 330, 331
Compound ophthalmiæ, 147
Concussion of brain, a cause of amaurosis, 456
Congestion, in inflammation, 84, 85, 86, 87
Conical cornea, 208
Conjugate foci, 309
Conjunctiva arida, 187
chemosed, excision and incision of, 78
corneæ, inflammation of, 94, 126
cuticular, 187
diseases of, 414
excision and incision of, in chemosis of, 78
foreign substances adhering to, 80–82
in folds of, 80
oculo-palpebral space of, 81
granular, 43, 89, 182
inflammations of, 87, 115
injuries of, 453
polypus of, 417
scarification of, 77
tumors of, 416, 417
warts of, 417
Conjunctival surface of eyelids, exploration of, 43
Conjunctivitis catarrhalis, 116
contagiosa, 121
Egyptiaca, 121

Conjunctivitis erysipelatosa, 90, 133
gonorrhoica, 131, 160
leucorrhoica, 132
morbillosa, 177
phlyctenulosa, 138
puro-mucosa, 132
pustulosa, 115
scarlatinosa, 161
scrofulosa, 138, 147
variolosa, 177
Consistence of eyeball, 63
Contagious ophthalmia, 121
reproduction of, by inoculation, as a means of treating pannus, 124, 186
Contusion of cornea, 457
edge of orbit, 456
eyebrow and eyelids, 468
eyelids, 41
Corectomia, 289, 293
Coremorphosis, 283
Coreoncion, Graefe's, 296
Lagenbeck's, 296
Coreplastice, 283
Cornea, abscess of, 94, 188
arthritic ring round, 54, 55, 156, 164
bluish-white ring round, 54, 55, 156, 164
burns of, 455
cicatrice of, 98, 190
conical, 208
contusion of, 457
dimple or clear facet of, 98
extraction through, 247
fistula of, 459
foreign substances adhering to, 81, 82
imbedded in, 457
hernia of, 96
inflammation of, 92, 137, 459
injuries of, 457
lining membrane of, inflamed, 94, 96, 156
malformations of, 208, 212, 317
mortification of, 97
non-malignant tumors of, 218, 417
paracentesis of, 83
penetrating wounds of, 457
punctured wounds of, 457
rupture of, 123
specks or opacities of, 189
ulcer of, from debility, 188
ulcers of, 96, 188
vascular, 186
and iris, staphyloma of, 192
wounds of, 457
Corneitis parenchymatosa, 94, 95, 146
rheumatica, 146
scrofulosa, 143
Corodialysis, 293, 297
Coretomia, 285, 289
Couching, 266
Counter-irritation in diseases of the eyes, 79
Crampton's operation for entropium, 397

Cranium, disease of membranes or bones of, producing amaurosis, 340, 341
pressure on orbit from cavity of, 450
Crayon of alum in granular conjunctivitis, 186
bluestone, 184, 185, 186
borax, 186
rock-salt, 186
Crystalline lens and capsule, injuries of, 463
Crystallino-capsulitis, 102, 166
Cupping, in diseases of the eyes, 75
Cuticular conjunctiva, 186
Cutting-needles in cataract, 277
Cylindrical eye, 317
Cysticercus or hydatid in anterior chamber, 215
eyelid, 411
under conjunctiva, 417

Dacryocystitis acuta, 428
chronica, 429
Dacryolites, 445
Day-blindness, 335
Debility, amaurosis with, 344
Depression of cataract, 266
through cornea, 272
sclerotica, 268
Descemet, inflammation of membrane of, 94, 156
Dichromatism of lens in glaucoma, 345
Digestive organs, amaurosis from disordered, 344
Dilatation of orbit from pressure, 450
of pupil, artificial, 59
Dimple, or clear facet of cornea, 98
Diplopy, 356
with one eye, 318
Direction of the eyeballs, examination of, 46
Dislocation of eyeball, 468
lens, 464
Dislocation of pupil, 283, 298, 463
Displacement of cataract, 266, 268, 282, 281
pupil, 169, 463
Dissolution of vitreous body, 204
Distichiasis, 398
Distoma in crystalline, 218
Distortion of eyeball, 358
Division of cataract, 274
through cornea, 278
sclerotica, 275
straight-needle in, 276
cutting-needles in, 277
enlarged vessels in sclerotic conjunctiva, 77
Double vision from want of correspondence in muscles of eyeball, 356, 359
with one eye, 318
two eyes, 356
when natural, 353
Drilling, an operation for cataract, 279
Drops for the eyes, 70
Dropsy of aqueous chambers, 201, 211
eye, 211
vitreous body, 203, 212
sub-choroid, 203, 213
sub-sclerotic, 203, 213
Dry cold to the eyes, 66

Dry warmth, 67
Dryness of eye, 186, 422
Duct, nasal, injuries, 472
obliteration of, 445
obstruction of, 441
Ducts, lacrymal, injuries of, 397, 470
Dura mater, and cranium, disease of, producing amaurosis, 342

Ecchymosis of eyelids, 468
under conjunctiva, 51, 214, 468
Ectropium, 40, 381
sarcomatosum, 382
Effusion of blood into eye, 214, 456, 467, 468
Egyptian ophthalmia, 121
reproduction of, by inoculation, as a means of treating pannus, 124, 186
Emetics in ophthalmic inflammation, 111
scrofulous ophthalmia, 140
Emphysema of eyelids, 41, 471, 472
subconjunctival, 51
Ecanthis benigna, 421
inflammatoria, 419
maligna, 422
Encysted tumor in connection with the iris and aqueous chambers, 219
Encysted tumors in orbit, 451
eyelids and eyebrows, 408, 410
Enlarged vessels in sclerotic conjunctiva, division of, 77
Enlargement of lacrymal gland, 425
Enlargement of eyeball, 208
Entozoa in organs of vision, 215, 438, 417, 452
Entropium, 393
Epicanthus, 404
Epiphora, 46, 423
Eruptions, syphilitic, affecting eyelids, 379
Erysipelas of eyelids, 41, 372
Erysipelatous ophthalmia, 90, 133
Evacuation of aqueous humor, 83
Eversion of eyelids, 43, 381
Evulsion of eyeball, 468
eyelashes, 79
Examination of the eyes, objective, 37
subjective, 63
direction and movements of the eyeballs, 46
front and interior of the eyeball, 47
state of pupil, 56
catoptrical, of crystalline body, 60
Excision, artificial pupil by, 289, 293
of chemosed conjunctiva, 78
Excoriation, eversion of eyelids from, 381
Excrescence of iris, fungous, 219
Exophthalmia, 449
Exophthalmos, 449
Exostosis of orbit, 450
Exploration of the angles of eye and lacrymal organs, 44
conjunctival surface of eyelids and palpebral sinuses, 43
eyes in order to a diagnosis, 37
objective, 37
subjective, 63
eyebrows and orbital margins, 39
eyelids, tarsal border, cilia, and Meibomian apertures, 40

Extirpation of eyeball, 228
eyelids, 413
lacrymal gland, 424
orbital tumors, 452
partial, of orbital tumors, 451
Extraction of cataract, 247, 265
through sclerotica, 247
section of one-third of cornea, 266
semicircular section of cornea, 249
Exudation in inflammation, 84
Exuded matter in inflammation, 84, 89, 94, 99, 105, 106
Eye, adaptation of artificial, 206
apoplexy of, 342
blows on, 344, 456
cylindrical, 317
dropsy of, 211
gunshot wounds of, 457
modes of fixing, during operations, 242, 243
pressure on, 341, 342, 343, 450
sanguineous effusion into, 214, 456, 467, 468
Eyes, sensations of the two, correspondence between, 348
loss of correspondence between, 356
Eyeball, atrophy of, 205
bursting of, 467
cancer of, 221, 226
consistence of, 63
dislocated, 468
enlargements of, 208
evulsion of, 468
extirpation of, 228
fungus hæmatodes of, 221
immovable distortion of, 358
inflammatory diseases of, 84, 114
injuries of, 456
non-malignant tumors of, 218
malignant affections of, 221, 226
melanosis of, 226
oscillation of, 370
scirrhus of, 221
spongoid or medullary tumor of, 221
tumors within, 218
Eyeballs, movements of the two, correspondence in, 353
loss of correspondence in, 358
Eyebrow, injuries of, 39, 468, 470
tumors in, 408
wounds of, 468, 470
phtheiriasis of, 413
Eyebrows and orbital margins, exploration of, 39
Eye-drops, 68, 71
Eyelashes, exploration of, 40
false, 42, 398
inversion of, 398
phtheiriasis of, 413
Eyelid, lower, capable of being drawn up over the front of the eyeball, 40
retraction of, 401, 402
upper, falling down of, 40, 403
Eyelids, albuminous tumor of, 410
aneurism by anastomosis of, 411
burns and scalds of, 40, 470
Eyelids, callosity, scirrhoid of, 412

Eyelids, cancer of, 412
carbuncle of, 373
contusion and ecchymosis of, 468
convulsion of, 50
emphysema of, 41, 471, 472
encysted tumors in, 411
erysipelatous inflammation of, 372
eversion of, 381
exploration of, 40
extirpation of, 413
fibrinous tumor, 410
hydâtids in, 411
inflammation of edges of, 374
injuries of, 468
inversion of, 393
malignant pustule of, 373
melanosis of, 413
milium of, 409
nævus maternus of, 411
œdema of, 41
palsy of, 403
phlegmonous inflammation of, 371
phlyctenulæ of, 408
poisoned wounds of, 469
retraction of, 401, 402
scirrhoid callosity of, 412
scirrhus of, 412
spasm of, 40
syphilitic ulceration of, 379
eruptions affecting, 379
tumors in, 408
twitching or quivering of, 40
variolous inflâmmation of, 373
warts on, 409
wounds of, 468
Eye-powders, 73
Eye-salves, 72
Eye-waters, 68

Farsightedness, 314
Fifth nerve, injuries of branches of, 456
irritation of, producing amaurosis, 343
Filaria in crystalline, 218
Medinensis under conjunctiva, 419
Fistula of cornea, 459
lacrymal sac, 433
spurious, 46, 427
true lacrymal, 424
Fixed muscæ, 335
Foci, conjugate, 309
Focus, principal of a lens, 309
Fomentations to the eyes, warm, 66
Foreign bodies in aqueous chambers, 461
in oculo-palpebral space of conjunctiva, 80
body in orbit, 472
substances adhering to conjunctiva, 80–82
imbedded in cornea, 457
Fractured cranium with depression, producing amaurosis, 342
Fractures of edge of orbit, 39
Friction, anodyne, 78

Front of the eyeball, examination of, 50
Frontal sinus, diseases of, produce amaurosis, 342
pressure on orbit from, 450
Fungus hæmatodes in the orbit, 453
of brain, 223
eyeball, 221
optic nerve, 223
Fungus of antrum, 450
caruncula lacrymalis, 421
iris, 215

Gerontoxon, 55, 247
Gibson's mode of extracting soft cataract, or combination of division and extraction, 282
Gland, lacrymal, encysted tumor in, 425
enlargement or scirrhus of, 425
extirpation of, 424
inflammation and suppuration of, 423
injuries of, 425, 470
Glands of cilia, inflammation of, 375
Glandulæ congregatæ or lower mass of lacrymal gland, injuries of, 397, 470
inflammation of, 423
Glasses for cataract-patients, 282
longsightedness, 315
shortsightedness, 313
Glaucoma, 61, 345
acute, 347
dichromatism of lens in, 345
dissections of eyes in state of, 345
its diagnosis from cataract, 235
with amaurosis, 347
with cataract, 346
Gonorrhœal conjunctivitis, 131
iritis, 160
ophthalmia, 131, 132
Granular conjunctiva, 43, 89, 182–186
Gunshot wounds of the eye, 456, 457
Gutta opaca, 336
serena, 336

Hæmophthalmus, 214
Half-vision, 332, 336
Hays' operation for cataract, 277
Healing process, nature of, 86
Hemeralopia, 333
Hemiopy, 332, 336
Hernia of cornea, 96
iris, 96
lacrymal sac, 431
Himly's operation for artificial pupil, 298
Hordeolum, 378
Hyaloid membrane, dissolved, 204
opacities of, 190
Hyaloïditis, 103
Hydatids in eyeball, 215
eyelids, 411
orbit, 452
under conjunctiva, 417
Hydrocephalus, amaurosis from, 341, 342
Hydrophthalmia, 211

Hydrops of lacrymal sac, 432
Hyperkeratosis, 208
Hyperostosis of orbit, 450
Hypertrophia lentis, 347
Hypochyma, 345
Hypopyon, 200

Incision, artificial pupil by, 285–289
of chemosed conjunctiva, 78
through cornea, artificial pupil by, 287
sclerotica, artificial pupil by, 285
Infiltration of orbital cellular membrane, 450, 468, 472
Inflammation, distinction of, into acute and chronic, 86
in general, 84
of aqueous capsule, 156
bones of orbit, 449
caruncula lacrymalis, 419, 420
choroid, 101, 168, 169
conjunctiva, 87, 115
cornea, 92, 137, 459
crystalline lens and capsule, 102, 166
derivative lacrymal organs, acute, 428
chronic, 429
edges of eyelids, 374
eyelids, erysipelatous, 41, 372
eyelids, erysipelatous, poultices to, 372
phlegmonous, 371, 372
hyaloid membrane, 103
internal optic apparatus, a cause of amaurosis, 339, 340, 343
iris, 99, 139, 158
lacrymal gland, 423
Meibomian follicles, 379
orbital cellular membrane, 446
periosteum of orbit, 449
retina, 101, 167
semilunar membrane, 419
ophthalmic, 84
in general, 86
proper, 84
terminations or events of, 84
varieties of, 86
Inflammations of eye from injuries, 181
eyeball, 114.
Inflammatory process, phenomena attending the first step of, 84
Injections of lacrymal passages, 69, 431, 432
Injuries of branches of fifth nerve, 456
conjunctiva, 453
cornea, 457
crystalline lens and capsule, 463
eyeball, 456
eyebrow and eyelids, 468–470
head, amaurosis from, 342, 343, 456
iris, 463
lacrymal canals, 471
glands and ducts, 470
sac, 471
muscles of eyeball, 472
nasal duct, 472
orbit, 456, 472
orbital cellular membrane, 472

Inoculation to reproduce contagious ophthalmia, as a means of curing pannus, 124, 186
Interior of eyeball, examination of, 48
Intolerance of light, 64, 104
Intoxication producing amaurosis, 343
Inversion of eyelashes, 398
eyelids, 393
Iriankistron, *Schlagintweit's*, 296
Iridauxesis, 202
Iridectomy, 289
Iridectomedialysis, 297
Irideremia congenita, 59, 301
Irido-dialysis, 293
Iridoncosis, 57, 202
Irido-periphakitis, 166
Iridoschisma, 302
Iridotomy, 285
Iris, abscess of, 100, 162
abscission of, 297
accidental separation of, from choroid, 463
congenital absence of, 59, 301
fissure of, 59, 302
imperforation of, 304
encysted tumor connected with the, 220
fungous excrescence of, 219
hernia of, 96
inflammation of, 99, 158
injuries of, 463
its motions effected through third nerve and sympathetic, 305
non-malignant tumors of, 219
paralysis of, 304, 307, 308
preternatural states of, 301, 302, 304, 307, 308
prolapsus of, 99, 192, 458, 459
staphyloma of, 202
tremulous, 204
Iritis, 99, 158
after typhus fever, 180
arthritica, 163
gonorrhoica, 160
rheumatica, 159
scrofulosa, 158
sympathetica, 181
syphilitica, 161
traumatica, 181
with amaurosis after typhus fever, 180
Irritation of fifth nerve, amaurosis from, 343

Janin's ointment, 73
operation for artificial pupil, 287

Keratitis, see Corneitis.
Keratonyxis, 267
Knife-needle in cataract, 277

Lacrymal calculus, 445
canals, injuries of, 471
obstruction of, 434
fistula, true, 424
glands and ducts, injuries of, 470
enlargement or scirrhus of, 425

Lacrymal glands, encysted tumor in, 425
extirpation of, 424
inflammation and suppuration of, 423
organs, acute inflammation of derivative, 428
chronic inflammation of derivative, 429
diseases of derivative, 426
secreting, 422
exploration of, 44
puncta, obstruction of, 434
relaxation of, 433
sac, abscess of, 428, 430
blennorrhœa of, 429
dropsy of, 432
fistula of, 427, 433
hernia of, 431
injuries of, 471
mucocele of, 432
polypus of, 441
relaxation of, 431
spurious fistula of, 46, 427
xeroma, 422
Lacrymation, disordered, 103, 422
Lactation, a cause of amaurosis, 344
Lagophthalmos, 401
Lapis divinus, 69
Leeches, application of, to the eyes, 75
Lens and capsule, injuries of, 463
dichromatic, in glaucoma, 345
dislocation of, 464
hypertrophy of, 347
opacity of, 230
Lenses of the eye, inflammation of, 102
Lentitis, 102
Leucoma, 98, 190
Leucorrhœal ophthalmia, 128, 132
Light, amaurosis from intense, 342, 343, 344
intolerance of, 64, 104
Lime, effects of, thrown into eye, 455
Lippitudo, 376
Longsightedness, 314
Luscitas, 47, 359

Madarosis, 376
Masturbation, a cause of amaurosis, 344
Maunoir's operation for artificial pupil, 287
Maxillary sinus, pressure on orbit from, 450
Measles, ophthalmia from, 177
Medullary tumor of eyeball, 221
Meibomian apertures, exploration of, 44
obliteration of, 45, 47, 376
obstruction of, 408
calculus, 408
glands, abscess of, 379
enlargement and induration of, 408
Melanosis in orbit, 453
of conjunctiva, 413
eyeball, 226
eyelids, 413
Menses suppressed, a cause of amaurosis, 343
Mercury in diseases of the eye, 111
Mesh, as a means of dilating the nasal duct, 441

Metamorphopsy, 358
Milium, 409
Monoblepsis, 358
Monostoma in crystalline, 218
Morbillous ophthalmia, 177
Movements of the eyeballs, exploration of, 46
Mucocele of lacrymal sac, 432
Muco-lacrymal muscæ, 327
Muscæ, fixed, 322, 335
muco-lacrymal, 327
volitantes, 322
Muscles of eyeball, correspondence in the action of, 353
loss of correspondence in the action of, 358
injuries of, 472
palsy of, 366, 369
section of, in strabismus, 362
Mydriasis, 304, 308, 367
Myocephalon, 98
Myopia, 308, 310
Myosis, 304, 307
Myotomy, ocular, in strabismus, 362

Nævus maternus of eyelids, 411
Nasal duct, injuries of, 472
obliteration of, 445
obstruction of, 441
Nearsightedness, 308, 310
Nebula, 190
Necrosis of orbit, 449
New vessels, development of, in inflammation,
of cornea, 93, 94, 95, 96, 143, 156
of iris, 99
of crystalline capsule, 102, 166
Newton's hypothesis regarding arrangement of optic nerves, 351
Nictitation, morbid, 40
Night-blindness, 333
Nitrate of silver, application of, as a caustic, 74
drops and salve, 71, 72, 73
stains conjunctiva, 71
Nitre in ophthalmic inflammation, 111
Nostril, pressure from, on orbit, 450
Nyctalopia, 333
Nystagmus, 47, 370

Obliteration of pupil, 99, 202
Obstruction of lacrymal canals, 434
Meibomian apertures, 408
nasal duct, 445
puncta lacrymalia, 434
Ocular myotomy in strabismus, 362
spectra, 330
Oculi, speculum, 48
Oculo-palpebral space of conjunctiva, foreign bodies in, 80
Œdema of eyelids, 41
subconjunctival, 51
Onyx, 95, 182
Opacities of cornea, 190
hyaloid, 101

Opacity of crystalline capsule, 238
lens, 230
Operation for anchyloblepharon, 406
cataract, choice of an, 281
in infants, 280
symblepharon, 407
Operations for artificial pupil, 283
compound, 297, 300
cataract, general account of, 241
position of patient during, 244
indications and contraindications for, 241, 243, 267, 274
general observations and questions regarding, 241
eversion of eyelids, 382, 393
inversion of eyelashes, 399
eyelids, 395, 397
Ophthalmia, arthritic, 163, 171,
bellica, 121
catarrhal, 88, 116
catarrho-rheumatic, 151
contagious, 121
Egyptian, 121
epidemic, 118
erysipelatous, 90, 133
externa, 87, 115
from absorption of pus, 181
Ophthalmia gonorrhoica, 131, 160
interna, 153, 167
anterior, 87, 114, 153
posterior, 87, 114, 167
leucorrhoica, 128, 132
mercurial, 160
morbillosa, 177
neonatorum, 127
of new-born children, 127
phlyctenulosa, 138
puromucous, 115, 132
purulenta gravior, 121
mitior, 116
of infants, 127
pustulosa, 87, 115
rheumatica, 134
scarlatinosa, 177
scrofulous, 138
posterior internal, 167
scrofulo-catarrhal, 147
sympathetic, 181
syphilitic, 161
tarsi, 374
variolosa, 178, 373
Ophthalmiæ, 114
classification of, 114
compound external, 147
diseases consequent to, 182
traumatic, 181
Ophthalmic artery, aneurism of, 453.
Ophthalmic inflammation, causes of, 108
general treatment of, by antiphlogistics, 110
tonics and alteratives, 112
in general, 86

Ophthalmic inflammation, kinds of pain in, 63, 103
local treatment of, by antiphlogistic and soothing remedies, 112
irritating applications, 113
remedies for, 109
treatment of, 109
Ophthalmitis phlebitica, 180
postfebrile, 179
puerperal, 180
Ophthalmo-blennorrhœa, 121
Ophthalmoscope, 48
Ophthalmoscopy, 37
Optic nerves, morbid conditions of, producing amaurosis, 342
semi-decussation of, 333, 350
Orbicularis palpebrarum, palsy of, 401
Orbit, abscess of, 446–448
absorption of, from pressure, 450
caries of, 392, 449, 450
contusions of edge of, 456
dilatation of, from pressure, 450
diseases of, 446
exostosis of, 450
fractures of edge of, 40
fungus hæmatodes in, 452
hydatids in, 452
hyperostosis of, 450
injuries of, 472
melanosis in, 453
necrosis of, 449
osteo-sarcoma of, 450
ostitis of, 449
penetrating wounds of, 472
periostitis of, 449
periostosis of, 450
pressure on, from cavity of cranium, 450
frontal sinus, 450
maxillary sinus, 450
nostril, 450
sphenoid sinus, 450
within orbit, 450
tumors in, 449
Orbital aneurisms, 453
cellular membrane, induration of, 446
infiltration of, 450, 472
inflammation, erysipelatous, of, 447
inflammation, phlegmonous, of, 446
injuries of, 472
Oscillation of eyeball, 47, 370
Os unguis, caries of, 431
Osteo-sarcoma of orbit, 450
Ostitis of orbit, 449
Over-refraction, 311

Pain, kinds of, in ophthalmiæ, 63, 104
Palpebral sinuses, exploration of, 43
Palsy of abductor, or external rectus oculi, 369
levator palpebræ superioris, 366, 403
muscles of eyeball, 366, 369
face, 41, 401
muscles supplied by portio dura, 401

Palsy of muscles supplied by third nerve, 366
orbicularis palpebrarum, 401
upper eyelid, 403
from wounds, 403
Pannus, 186
treatment of, by reproducing the purulent inflammation by inoculation, 124, 186
Panophthalmitis, 114, 174
Paracentesis corneæ, 83, 112
Paralysis of iris, 304, 307, 308
Periorbitis, 449
Periostitis of orbit, 449
Periostosis of orbit, 450
Perspiration, suppressed, causes amaurosis, 344
Phimosis palpebrarum, 405, 407
Phlebitic ophthalmitis, 180
Phlegmon, subconjunctival, 51
Phlegmonous inflammation of eyelids, 371
Phlyctenula of eyelids, 408
Phlyctenular ophthalmia, 138
Photophobia, 64, 104
Photopsy, 327
Phtheiriasis, 413
Phthisis oculi, 206
Pinguecula, 416
Pituitary gland, enlarged, producing amaurosis, 343
Pladarotes, 182
Polyopy, 318
Polypous excrescence of lacrymal caruncle and semilunar fold, 421
Polypus of lacrymal sac, 441
Position of patient during operation for cataract, 244
Postfebrile ophthalmitis, 179
Potential cautery, application of, to the eyes, 74
Poultices in ophthalmia, 372
in inflamed eyelids, 372
Presbyopy, 314
Pressure on eye, amaurosis from, 339, 342, 344
orbit, effects of, 450
from cavity of cranium, 450
frontal sinus, 450
maxillary sinus, 450
nostril, 450
sphenoid sinus, 450
within orbit, 450
Principal focus of a lens, 308
Prolapsus of iris, 99, 192, 458, 459
operation of, 298
Psorophthalmy, 376
Pterygium, 53, 414
crassum, 415
fleshy, 415
pingue, 416
tenue, 415
Ptosis, 403
Puerperal ophthalmitis, 180
Puncta lacrymalia, obstruction of, 434
relaxation of, 431
Pupil, artificial, 283
by excision, 289, 290, 293
incision, 285, 289

Pupil, artificial, by separation, 293, 297
artificial dilatation of, 59, 60
dislocation of, to opposite clear part of cornea, 298
displacement of, 169, 463
examination of state of, 56
morbid contraction of, 301, 307
dilatation of, 301, 308
obliteration of, 99, 202
restoration of, to natural position by abscission, 297
Pupils contract during sleep, 301
their occasional mobility in amaurosis explained, 307
Purkinje's experiment, 326
Puro mucous conjunctivitis, 89, 132
ophthalmia in female children, with puro-mucous discharge from vagina, 133
Pustular ophthalmia, 87, 115
Pustule, malignant, of eyelids, 373

Quina, use of, in scrofulous ophthalmiæ, 112, 142
Quivering of eyelids, 40

Reclination of cataract, 268, 272
through cornea, 272
sclerotica, 275
Reisinger's double hook for artificial pupil, 296
Refraction, diminished, 314
irregular, 301, 317
preternatural, 310
Relaxation of lacrymal sac, 431
puncta lacrymalia and canaliculi, 433
Resolution of inflammation, 85
Retina, aneurism of its central artery, produces amaurosis, 342
apoplexy of, 342, 344
coarctation of, 102, 244
pressure on, by depressed lens, 268, 274, 281
spectrum of vascular ramifications of, 326
Retinitis, 101, 167
Retraction of eyelids, 402
Rheumatic corneitis, 146
iritis, 159
ophthalmia, 134
Ring, arthritic, 54, 55, 164, 171
bluish-white, around the cornea, 54, 55, 164, 171
Rupture of cornea, 123

Sanguineous effusion into eye, 214, 456, 467, 468
Sarcomatous tumors in orbit, 451
Scarification of conjunctiva, 77
Scarlatinous ophthalmia, 177
Scirrhoid callosity of eyelids, 412
Scirrhus of caruncula lacrymalis, 422
eyeball, 221
eyelids, 412
lacrymal gland, 425
Sclerotica, extraction through, 247
non-malignant tumors of, 218
wounds of, 467
Sclerotico-choroiditis, 168
Sclerotitis, 91
rheumatica, 134

Sclerotitis, scrofulous, 136
Scrofulo-catarrhal ophthalmia, 147
Scrofulous corneitis, 143
iritis, 158
ophthalmia, 138, 167
sclerotitis, 136
Secondary cataract, 280
Semilunar fold, inflammation of, 419
Sensations of light and color, subjective, 327
Sensations, irradiation of, 329
Separation, artificial pupil by, 293, 297
Shortsightedness, 308, 310
Sight, over-exercise of, a cause of amaurosis, 343, 344
weakness of, 319, 336
Small-pox, ophthalmia from, 178, 373
Spasm of eyelids, 40
Speck, vascular, 148, 149
Specks of cornea, 189
crystalline capsule, 238
Spectra consequent to impressions on the retina, 329
Spectra, ocular, 322, 324, 330
Spectacles, concave, 312
convex, 282, 316
Speculum oculi, 48
Sphenoid sinus, pressure on orbit from, 450
Spongoid tumor of eyeball, 221
Squinting, 359
Staphyloma, conical, 195, 201
of cornea and iris, 192
operation for, 199
partial, 192
pathology of, 193
prevention of, 198
prophylactic treatment of, 198
spherical, 193
total, 193
iridis, 202
pellucidum, 208
posticum, 203
racemosum, 99
sclerotic, 56, 203
uveæ, 203
Single vision with two eyes, 349
Stereoscope, 350, 351
Stillicidium lacrymarum, 46, 423
Strabismus, 359
convergens, 359
cure of, by ocular myotomy, or section of muscles of eyeball, 362
deorsumvergens, 365
divergens, 365
sursumvergens, 365
Strychnia, in amaurosis, 344
Stye, 378
Style, use of lacrymal, 442
Subjective symptoms, 63
Subsclerotic and subchoroid dropsy, 213
Suckling, amaurosis from, 344
Suffusion of cornea, 189
Sulphuric acid, effects of, thrown into eye, 455

Suppressed menses, amaurosis from, 343
perspiration, amaurosis from, 343
purulent discharge, amaurosis from, 344
Symblepharon, 407
Synchisis, 204
scintillans, 63
Synechia anterior, 201
posterior, 202
Synizesis, 202
Syphilitic iritis, 161
eruptions affecting eyelids of infants, 381
ulceration of eyelids, 381

Tarsal border, exploration of, 41
Tarsal ophthalmia, 374
Tarsoraphia, 391
Tinea ciliaris, 376
Trachoma, 182
Traumatic ophthalmia, 181
Tremulous iris, 204
Trichiasis, 398
Trichosis bulbi, 19, 53, 416
Tube for nasal duct, 443
Tumor, albuminous, in eyelids, 410
encysted, in eyelids, 410, 411
connected with the iris and aqueous chambers, 219
in neighborhood of lacrymal gland, 424
fibrinous, in eyelids, 410
spongoid, or medullary, of eyeball, 221
Tumors, conjunctival, 416, 417
in eyebrow and eyelids, 410
brain, producing amaurosis, 342
orbit, 449
non-malignant, in vitreous humor, 219
of choroid, 219
cornea and sclerotica, 218
eyeball, 218
iris, 218
within eyeball, 219
Turpentine, its use in corneitis, iritis, &c., 111, 136, 142, 145, 156, 158, 161 163, 165
Twitching of eyelids, 40
Tylosis, 376

Ulceration, 85
Ulcers of cornea, 94, 188
eyelids, cancerous, 412
scrofulous, 376
syphilitic, 378
Uvea, staphyloma of, 202
Uveitis, 101, 102

Vaccination, cure of nævus maternus by, 412
Vapors, of aromatic or narcotic substances to the eyes, 67
medicated, to the eyes, 67
stimulating, 67
watery, 67
Varicositas oculi, 203
Variolous ophthalmia, 162, 175

Vascular cornea, 186
speck, 148, 149
Venery, a cause of amaurosis, 344
Vision, colored, 318
defective, various states of, 64, 304, 322, 327, 348
Visus defiguratus, or metamorphopsy, 358
dimidiatus, 336
increscens, 336
interruptus, 336
Vitreo-capsulitis, 114
Vitreous body, dissolution of, 204
dropsy of, 203, 212
non-malignant tumors in, 219

Warm applications to the eyes, 66
Warm cataplasms and fomentations, 66
Warmth, dry, 67
Warts on eyelids, 409
of conjunctiva, 417
Watery eye, 46, 423
Watery vapors to the eyes, 67
Weakness of sight, 319, 336
Web, 414
Wenzel's operation for artificial pupil, 293
Wollaston on semi-decussation of optic nerves, 333
Worms, amaurosis from, 343
Wounds, gunshot, of eye, 456, 457
of choroid, 467
cornea, penetrating, 457
punctured, 457
eyebrows and eyelids, 468
sclerotica, 467
penetrating orbit, 472

Xeroma, conjunctival, 186
lacrymal, 422
Xerophthalmia, conjunctival, 186
lacrymal, 422

Zonula, cataracta cum, 241

THE END.